

Unusual Presentation of Invasive Mole: A Case Report

Soheila Aminimoghaddam ^{1*}, Andisheh Maghsoudnia ²

1- Department of Obstetrics and Gynecology, Firouzgar Hospital, Iran University of Medical Sciences, Tehran, Iran

2- Tarbiat Modares University, Tehran, Iran

Abstract

Background: Invasive mole is responsible for most cases of localized gestational trophoblastic neoplasia. Gestational trophoblastic disease describes a number of gynecologic tumors that originate in trophoblastic layer including hydatidiform mole (complete or partial), invasive mole, choriocarcinoma, placental site trophoblastic tumor and epitheloid trophoblastic tumor. Invasive mole may arise from any pregnancy event although in most cases is diagnosed after molar pregnancy. Overall cure rate in low risk patients is nearly 100% and in high-risk patient 90%. In rare cases, molar tissue traverses thickness of myometrium and leads to perforation and acute abdomen and invasive mole infrequently metastasis. The best treatment option is chemotherapy (according to stage and score with single or multiple agent) and in patients that fertility is not the matter, hysterectomy can be done.

Case Presentation: A 41 years old G3P2ab1 woman referred to Firouzgar hospital 2 months after curettage of molar pregnancy with vaginal bleeding and acute abdomen. In workup, HCG 224000 mIU/ml and evidence of metastasis was detected. Chemotherapy due to stage 3 and score 9 and surgery due to acute abdomen was done. This case was reported for its rarity.

Discussion: This case reported about ovarian metastasis and uterine rupture with acute abdomen and involvement of omentum in metastatic invasive mole. Lack of surveillance led to extensive morbidity. Management of this patient was successful. In follow up, she was free of disease without sequel of any kind for five years now.

Key words: Complete mole, Gestational trophoblastic neoplasia, Haemoperitoneum, Invasive mole, Trophoblast.

To cite this article: Aminimoghaddam S, Maghsoudnia A. Unusual Presentation of Invasive Mole: A Case Report. J Reprod Infertil. 2017;18(1):205-209.

* Corresponding Author:
Soheila Aminimoghaddam,
Gynecology Oncology
Department, Firouzgar
Hospital, Iran University
of Medical Sciences,
Valiasr Square, Tehran,
Iran
E-mail:
Dr_aminimoghaddam@
yahoo.com

Received: Nov. 14, 2015

Accepted: Mar. 2, 2016

Introduction

Invasive mole is penetration of molar tissue (complete or partial mole) into myometrium or uterine vasculature (1, 16, 19). Edematous villus and proliferative trophoblasts invade myometrium so they can be distinguished from choriocarcinoma. Pathologists mention the existence of villi in trophoblastic tissue (8, 12). Locally invasive gestational trophoblastic neoplasia develops in 15% of patients and metastatic form in 4% of patients after evacuation of complete mole and infrequently after partial mole (2).

HCG level (>100000 mIU/ml), excessive uterine enlargement, theca lutein cyst size ≥ 6 cm are considered as high risks for developing post molar

tumors (high risk mole) (3). The most common symptom of invasive mole is persistent vaginal bleeding after evacuation of molar pregnancy (sub involution of uterus and persistent theca lutein cyst is another symptom). The rise in β HCG titer is a laboratory test for diagnosis of invasive mole in follow up of molar pregnancy. Although definite diagnosis of invasive mole is based on pathology (8), with β HCG or radiologic diagnosis (9), invasive mole is diagnosed as well.

In rare cases, metastasis occurred and the most common sites were lungs (80%) (4), vagina (30%), pelvis (20%), liver (10%), brain (10%), bowel and kidney and spleen ($<5\%$) were other metastatic

sites. However, metastasis to ovary from invasive mole is rare. About 5% to 6% of ovarian tumors come from metastasis of other organs. Metastasis can occur from direct extension of another pelvic neoplasm or by hematogenous or lymphatic spread or by transcelomic dissemination. Possibility of metastasis to ovary is extremely rare which is even much lower than that of nongestational primary ovary choriocarcinoma with an incidence of 1 in 3.7×10^8 (5). Ovarian non gestational choriocarcinoma is a major differential diagnosis. Metastasis to the omentum is very rare in invasive mole. Invasive mole is curable with chemotherapy but hysterectomy decreases the need for multiple courses of chemotherapy and in patients with heavy bleeding or sepsis for control of complication and stabilization, chemotherapy is needed (6, 11).

Here a case with invasive mole after evacuation of molar pregnancy, presented with acute abdomen and in surgery metastasis to ovary and omentum and parametrium was detected. Management and treatment with hysterectomy and chemotherapy in this case was successful.

Case Presentation

A 41- year- old housewife woman, gravid 3 para 2 live child 2 (all NVD) with a last 10 years old child referred to Firouzgar hospital on 24 August 2010 with a history of a dilation and curettage and 2 months of cough. On examination, she was febrile (38°C., tachycardia, leukocytosis (16000) and uterus was tender and enlarged. Primary management of her problem was carried out in another hospital. Vaginal bleeding persisted and second curettage was done in another hospital. At that time, chest x-ray was normal. In our hospital, report of sample pathology given from first and second curettage was complete mole. After molar evacuation, the patient was not monitored for weekly determination of β HCG level. She received antibiotics (due to fever) and work up for malignant trophoblastic disease or persistent GTN was

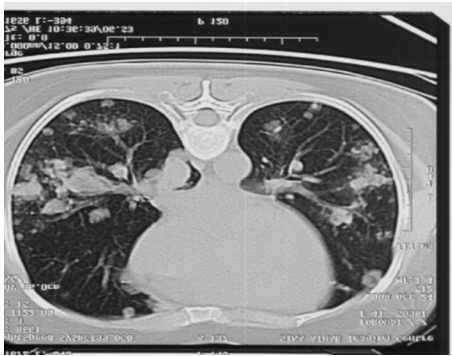

Figure 1. Pulmonary Metastasis in invasive mole

done because of high β HCG level (224000 *mIU/ml*) and much too enlarged uterus and involvement of the whole uterine parenchyma, which was detected on sonography (largest tumor size in uterus was 6 *cm*). The liver and renal function tests were also normal. Thyroid function test demonstrated hyperthyroidism. In the metastatic work up, CT scan of chest and abdomen and brain was carried out. CT scan of the abdomen and pelvis showed involvement of the left adnexa and pelvic lymphadenopathy.

The patient’s chest CT scan showed multiple bilateral round pulmonary metastatic lesions that were 2 *cm* in diameter, illustrated in figure 1. The liver and brain scans were both normal.

Once the disease was diagnosed, the patient chemotherapy with EMA started (Table 1). Because of acute abdomen and severe abdominal pain and unstable vital signs with diagnosis of perforative peritonitis, the patient was taken up for emergency laparotomy. Due to hyperthyroid state, in induction of anesthesia, β blocker agent was administered. In this patient, subtotal hysterectomy and left salpingo oophorectomy and resection of omentum were done. In gross uterus, chorionic villus was seen. Uterine wall was perforated by tumoral invasion on the left side of posterior wall (Figure 2).

The bilateral uterine parameters, the external

Table 1. The patient was III:9 according to FIGO staging and WHO scoring (7)

	0	1	2	4
Age (year)	<40	≥40		
Antecedent pregnancy	mole	abortion	Term	
Interval months from index pregnancy	<4	4-7	7-13	≥13
Pretreatment HCG serum (<i>mIU/ml</i>)	<1000	1000-10000	10000-100000	≥100000
Largest tumor size (<i>cm</i>)	<3	3-5	>5	-
Site of metastasis	lung	Kidney/spleen	GI	Liver/brain
Number of metastasis	-	1-4	5-8	>8
Previous failed chemotherapy	-	-	Single drug	Two or more drugs

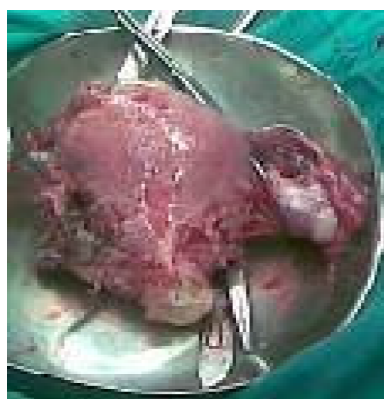

Figure 2. Enlarged uterus, ovarian metastasis, perforation of uterus, and myometrium invasion

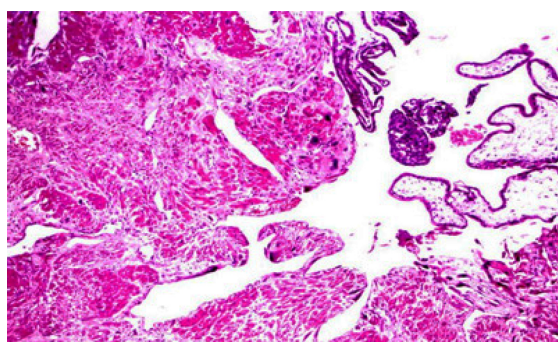


Figure 3. Villous formation in myometrium

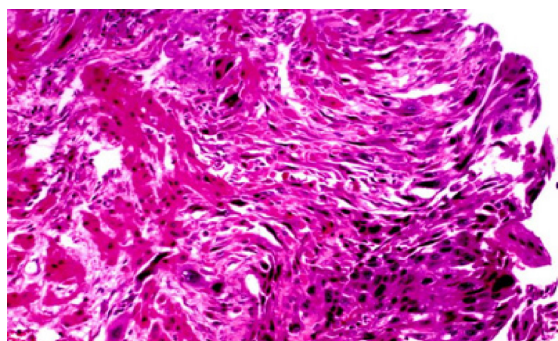


Figure 4. Villosity with necrosis in invasive mole

surface of the endocervical canal and the omentum were invaded by tumors. A hemorrhagic luteal cyst was seen in the right ovary. The left ovary was totally invaded by tumors. Final diagnosis was invasive mole (Figures 3 and 4).

This patient was treated with 4 courses of chemotherapy with EMA-CO. After negative β HCG (<5), she received an additional 3 courses of chemotherapy to reduce the relapse.

β HCG titer was later tested monthly for 1 year. When the first year of testing β HCG terminated, HCG testing on a bimonthly basis for 2 years was done. The patient was followed up to 5 years and

after that the patient was free of tumor and the β HCG was negative.

Discussion

Invasive mole with rupture of uterus and metastasis to ovary and omentum and manifestation of acute abdomen was rare (5). According to epidemiological retrospective survey, invasive mole secondary to hydatidiform mole occurred in six months after evacuation (5, 3). Local invasion in the uterus occurred in about 15% of cases (12). Overall invasive mole occurred in 1/15000 pregnancies (12).

Partial and complete hydatidiform mole are distinct disease processes with characteristic cytogenetic, histologic, and clinical features (8).

Kumar et al. in 2014 (13) reported a case of invasive mole presenting as acute hemoperitoneum that was similar to the present case. In invasive mole, proliferation of trophoblast in stroma was seen. Molar tissue can penetrate myometrium (9) and lead to uterine perforation (13) and cause vaginal bleeding due to erosion of uterine vessels (14, 15).

Similar to Atala et al.'s case report in 1991(14), in our case, uterine perforation with acute intra peritoneal hemorrhage was seen. Due to ease of entry of molar tissue into large venous lake present in myometrium and pelvis in pregnancy or trophoblastic disease metastasis of invasive mole commonly in lungs and after lungs in vagina, cervix, broad ligament (16, 19), in our case metastasis to lung and ovary and omentum was seen. Although theca lutein cysts in high-risk mole due to high serum HCG level are seen normally, they regress spontaneously within 2-4 months (17). Non gestational choriocarcinoma of ovary is differential diagnosis (5) but due to occurrence of metastasis to ovary in our case after molar pregnancy, this differential diagnosis was not a matter.

As in a report of invasive mole in fallopian tube (21), the first misdiagnosis of our case in another hospital, repeat curettage was done, although the first diagnosis could be persistent GTN.

In another case report (15) from Bruner, similarity with our case was seen.

Invasive mole is highly sensitive to chemotherapy (11). Combination chemotherapy should be continued in such cases as far as toxicity permits until the patient achieves 3 consecutive normal HCG levels (9, 18). As normal HCG levels are attained, 3 additional courses of chemotherapy are administered to reduce the risk of relapse. In low

risk patients, one or two courses are adequate (19).

In our case, 3 courses of chemotherapy after nor-malization of β HCG were done.

Hysterectomy may be required in invasive mole in order to control vaginal bleeding and in unstable patient or in sepsis (6, 20). Hysterectomy is a reasonable option for patients who do not wish to preserve their fertility, but it does not prevent metastasis (20). Furthermore, in patients with extensive uterine tumor, hysterectomy may substantially reduce the trophoblastic tumor burden (20) and thereby limit the need for multiple courses of chemotherapy.

In our case, due to unstable and uterine rupture, hysterectomy was done but the need for chemotherapy courses was not removed and after several courses of chemotherapy with EMA-CO courses, it was cured.

However, final diagnosis of our patient was invasive mole with metastasis to ovary and omentum and lung (stage 3) and uterine rupture.

The patient responded to the treatment well and in follow up this patient was still fine for 5 years after definite care for metastasis invasive mole with surgery and chemotherapy.

Conclusion

An invasive mole in uterus with ovarian and omental metastasis was diagnosed and the patient was successfully treated by hysterectomy and chemotherapy and she was fine for 5 years in follow up.

Conflict of Interest

Authors declare no conflict of interest

References

1. Tse KY, Chan KK, Tam KF, Ngan HY. An update on gestational trophoblastic disease. *Obstet Gynaecol Reprod Med*. 2012;22(1):7-15.
2. Seckl MJ, Fisher RA, Salerno G, Rees H, Paradinas FJ, Foscett M, et al. Choriocarcinoma and partial hydatidiform moles. *Lancet*. 2000;356(9223):36-9.
3. Uberti EM, Fajardo Mdo C, da Cunha AG, Rosa MW, Ayub AC, Graudenz Mda S, et al. Prevention of postmolar gestational trophoblastic neoplasia using prophylactic single bolus dose of actinomycin D in high-risk hydatidiform mole: a simple, effective, secure and low-cost approach without adverse effects on compliance to general follow-up or subsequent treatment. *Gynecol Oncol*. 2009;114(2):299-305.
4. Darby S, Jolley I, Pennington S, Hancock BW. Does chest CT matter in the staging of GTN? *Gynecol Oncol*. 2009;112(1):155-60.
5. Yamamoto E. Solid tumor section. *Atlas Genet Cytogenet Oncol Haematol*. 2009;13(9):683-5.
6. Doll KM, Soper JT. The role of surgery in the management of gestational trophoblastic neoplasia. *Obstet Gynecol Surv*. 2013;68(7):533-42.
7. El-Helw LM, Coleman RE, Everard JE, Tidy JA, Horsman JM, Elkhenini HF, et al. Impact of the revised FIGO/WHO system on the management of patients with gestational trophoblastic neoplasia. *Gynecol Oncol*. 2009;113(3):306-11.
8. Wells M. The pathology of gestational trophoblastic disease: recent advances. *Pathology*. 2007;39(1):88-96.
9. Green CL, Angtuaco TL, Shah HR, Parmley TH. Gestational trophoblastic disease: a spectrum of radiologic diagnosis. *Radiographics*. 1996;16(6):1371-84.
10. El-Helw LM, Hancock BW. Treatment of metastatic gestational trophoblastic neoplasia. *Lancet Oncol*. 2007;8(8):715-24.
11. Tidy J, Hancock BW. The Management of Gestational Trophoblastic Disease. UK: Royal College of Obstetricians and Gynaecologists; 2010 Feb. 11 p. RCOG Green-top Guideline No.: 38.
12. Balagopal P, Pandey M, Chandramohan K, Somanathan T, Kumar A. Unusual presentation of choriocarcinoma. *World J Surg Oncol*. 2003;1(1):4.
13. Kumar S, Vimala N, Mittal S. Invasive Mole Presenting as Acute Haemoperitoneum. *JK Sci*. 2004;6(3):159-60.
14. Atala C, Riedemann R, Biotti M, Ramírez F, Pabulo M. [Invasive mole with uterine rupture]. *Rev Chil Obstet Ginecol*. 1992;57(5):356-8. Spanish.
15. Bruner DI, Pritchard AM, Clarke J. Uterine rupture due to invasive metastatic gestational trophoblastic neoplasm. *West J Emerg Med*. 2013;14(5):444-7.
16. Okumura M, Fushida K, Pulcineli Vieira Francisco R, Schultz R, Zugaib M. Sonographic appearance of an advanced invasive mole and associated metastatic thrombus in the inferior vena cava. *J Clin Ultrasound*. 2013;41(2):113-5.
17. Ngan HY, Kohorn EI, Cole LA, Kurman RJ, Kim SJ, Lurain JR, et al. Trophoblastic disease. *Int J Gynecol Obstet*. 2012;119 Suppl 2:S130-6.
18. Berkowitz RS, Goldstein DP. Current advances in the management of gestational trophoblastic disease. *Gynecol Oncol*. 2013;128(1):3-5.
19. Lybol C, Sweep FC, Harvey R, Mitchell H, Short

- D, Thomas CM, et al. Relapse rates after two versus three consolidation courses of methotrexate in the treatment of low-risk gestational trophoblastic neoplasia. *Gynecol Oncol.* 2012;125(3): 576-9.
20. Fang J, Wang S, Han X, An R, Wang W, Xue Y. Role of adjuvant hysterectomy in management of high-risk gestational trophoblastic neoplasia. *Int J Gynecol Cancer.* 2012;22(3):509-14.
21. Zhang HY, Wu W, Zhu J. Unilateral hydronephrosis caused by invasive mole: a case report. *Int J Clin Exp Med.* 2013;6(10):1010-4.