

Histochemical Study of N-acetylgalactosamine Containing Glycoconjugate in Intraductal Carcinoma of the Breast by HPA Lectin

Mohammad Reza Arab, Ph.D.^{1,‡}, Zahra Sepehri, M.D.², Hossein Eimani, Ph.D.^{3,4}
Mehrbood Karimi, M.D.⁵, Fereydoon Sargolzaie Aval, Ph.D.¹

1. Anatomy Department, Faculty of Medicine, Zahedan University of Medical Sciences and Health Services
2. Imam Ali Hospital, Zahedan University of Medical Sciences and Health Services
3. Anatomy Department, Baghiyatallah University
4. Embryology Department, Royan Institute
5. Pathology Department, Zahedan University of Medical Sciences and Health Services

‡ Corresponding Address: P.O.Box: 98165-493, Anatomy Department, Faculty of Medicine, Zahedan University of Medical Sciences and Health Services, Zahedan, Iran
Email: mr_arabz@yahoo.com

Abstract

Received: 11/Jul/2005, Accepted: 23/Nov/2005

Introduction: Glycoconjugates are a class of glycoproteins or glycolipids, their terminal sugars are responsible for cell-cell and/or cell-extracellular matrix interactions. Aberrant glycosylation of these compounds are one of the most important aspects of cellular transformation, metastasis and escape of tumoral cells from immune system and resistance to antineoplastic drugs. Recent studies showed that patients with HPA (helix pomatia agglutinin) positive intraductal carcinoma cells have worse prognosis compared to patients with HPA negative cells. The aim of the present study was to define the presence of GalNac terminal sugar in glycoconjugate of different grades of intraductal breast carcinoma and to compare the degree and the pattern of reactivity of tumoral cells to HPA lectin.

Material and Methods: The paraffin blocks belonging to 20 patients of intraductal carcinoma was chosen from pathology archive of Khatam-Al-Anbia hospital in Zahedan and 5-7 micrometer sections were prepared. Two expert pathologists determined histopathological grading independently. The lectin histochemistry was performed using HPA. The same observers determined histochemical grading. Data were analyzed by NPAR (non-parametric) test of Mann Whitney.

Results: Results of this study revealed that the pattern and the degree of histochemical reactivity of neoplastic cells differ in all grades of intraductal carcinoma. Histochemical staining showed significant difference between grades of intraductal carcinoma of the breast ($p < 0.003$). The lowest reactivity was seen in grade I and the highest in grade III. Furthermore, the reaction of tumoral cells was primarily confined to apical surfaces of cells in grade I, to the Golgi zone in grade II, and to a diffuse cytoplasmic distribution in grade III.

Conclusion: Our data suggest that the HPA reactivity of tumoral cells were different in all grades of intraductal carcinoma. The tumor cells showed aberrant glycosylation, which occurred in the course of anaplastic changes. It seems that our data suggest a potential and clinically important role of HPA reactivity to predict the invasive nature of malignant tumoral cells of intraductal carcinoma of the breast.

Key words: Breast, Intraductal carcinoma, Glycoconjugate, Lectin

Yakhteh Medical Journal, Vol 7, No 4, Winter 2006, Pages: 216-221

Introduction

Breast cancer is the most frequent malignancy in women that may lead to death. The incidence and mortality rate are high in most developed countries, and early detection and

adequate therapy are very important (1). Once locally excised, some breast cancers are cured, while others progress rapidly and lead to death even after staying dormant for many years. This difference in the behavior of the

neoplastic cells cannot be predicted by morphological criteria alone (2). Knowledge of the biological properties of neoplastic cells provides new insights for treatment of cancer patients (3). Lectins are a class of plant biological compounds that specifically bind to terminal sugars of cell surface and extracellular glycoconjugates. The ability of lectins to bind selectively to the carbohydrate moiety of glycoconjugate makes these proteins valuable in experimental and clinical cancer research (4). Reactivity of some populations of neoplastic cells especially in adenocarcinoma to some lectins, PNA (peanut agglutinin), HPA, and UEA (ulex europeas agglutinin) have been shown to have some predictive values, because indicating a class of cancer cells which have more potential for metastasis (5).

helix pomatia agglutinin (HPA) is a lectin that specifically binds to N-acetyl galactosaminyl oligosaccharide (GalNac) and appears to be a valuable lectin for assessing long-term prognosis in breast cancer patients. HPA binding properties of tumours provide important data for staging and to choose the best treatment protocol (6, 7).

Glycosylation means the post-translational modification of cell surface and extracellular proteins, which multiplies the diversity of the proteins and also modifies their functions (8). Abnormal cellular glycosylation of neoplastic cells is a common feature of cancer cells that is responsible for their altered biological properties (8). Malignant transformation has been associated with changes in the glycosylation of cell surface proteins.

Tissue invasion and metastasis are highly dependent on alterations in the extracellular matrix and cell-cell interactions that in part involve structural changes in cell surface (9). Abnormal cellular glycosylation of cancer cells could reflect the aggressive biological behaviour of metastatic cells. Furthermore several studies showed that there is a good association between survival rate of breast cancer patients and HPA binding properties of neoplastic cells. It seems that the prognostic significance of altered glycosylation is unlikely to be related to the proliferation rate of neoplastic cells (10).

Brooks *et al.* showed that breast cancer cells may express a complex array of related but distinct glycans which have terminal immunodominant sugar GalNac.

It is possible that these glycoconjugates may be implicated in aggressive behaviour of cancer cells (7). The aim of the present study was to determine the HPA binding properties of neoplastic cells of breast cancer and to examine their potential correlation to histopathological grades.

Material and Methods

Sample collection

Paraffin blocks were prepared from a total of 20 patients of intraductal breast carcinoma in Khatam-Al-Anbia Hospital in Zahedan. Prepared hematoxylin & eosin stained sections were graded by two expert pathologists (Grades I, II, III). The number of enrolled patients in each group, from I to III was 4, 6 and 7 patients respectively. Three patients were excluded from the study, because there was disagreement on their histopathological grading.

Lectin Histochemistry

Prepared sections were deparaffinized and hydrated according to the routine procedures. HPA lectin (Sigma, USA) was diluted up to 10 µg/ml with 0.1M phosphate buffer solution (PBS pH=7). Sections (at least 3 for each patient) were incubated with lectin up to 2 hours in humidified chamber. Sections were washed in PBS for 30 minutes and then immersed in a 0.03% of diaminobenzidine (DAB) (Sigma, USA) solution containing 0.1% H₂O₂. Thereafter, sections were washed in running tap water for another 30 minutes and counterstained with alcian blue pH=2.5 and then dehydrated, cleared and mounted according to the routine procedures. Parallel control sections for each patient were used undergoing the same treatment except for not incubating with lectin or DAB. Histochemical grading was blindly assigned as [3+++ (highest reactivity), 2++ (intermediate reactivity), 1+ (low reactivity)] by the same observers. Collected data was analyzed using NPAR test of Mann Whitney via Statistical Package for Social Study, version 10.0 (SPSS Inc, Chicago, IL) software.

Results

Three histologic grades of intraductal carcinoma were determined according to the amount of glandular formation, nuclear atypia, degree of hyperchromasia, and the rate of mitotic figure. The extent of these structural

changes increased with histological grade (Fig. 1, 2, and 3).

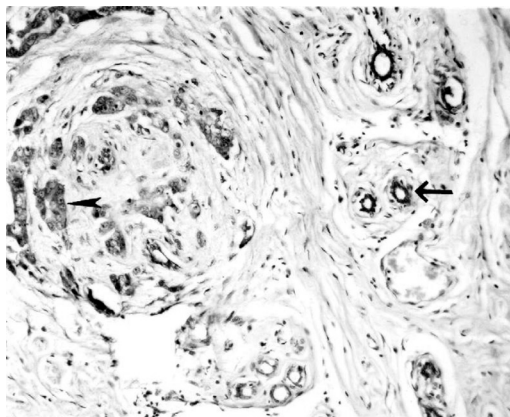


Fig 1: Histological appearance of neoplastic cells (arrow head) and normal duct (arrow) was shown in grade I of intraductal carcinoma of breast. H&E×200.

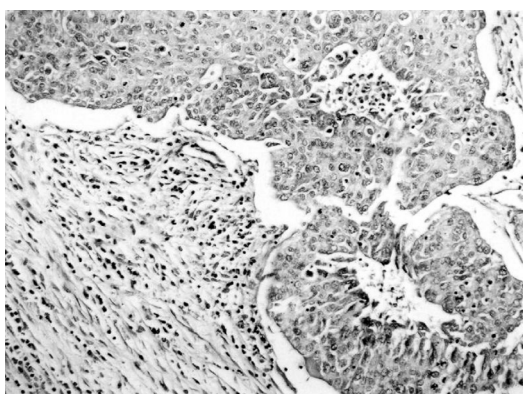


Fig 2: The aggregation of neoplastic cells and their stroma with inflammatory cells was shown in grade II of intraductal carcinoma of breast. H&E × 200.

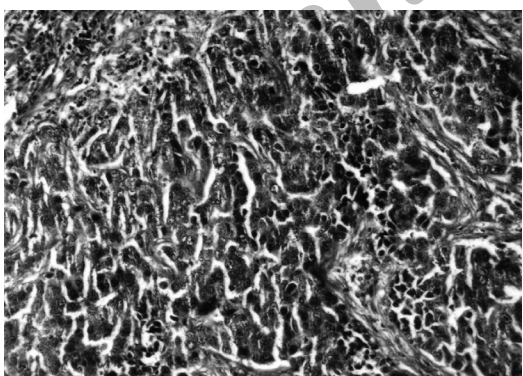


Fig 3: Nuclear hyperchromasia, pleomorphism, and cellular atypia were shown in grade III of breast intraductal carcinoma. H&E × 200.

Statistical analysis of obtained data according to the degree of reactivity to HPA lectin (i.e. showing the GalNac terminal sugar of glycoconjugates) revealed that there was a

significant statistical difference between three histological grades of intraductal breast carcinoma ($p<0.003$). The highest staining reactivity was observed in grade III, while the lowest one was seen in grade I.

Accordingly, the staining reactivity in grade II was intermediate. Furthermore, there was a special pattern of heterogeneity among neoplastic cells in all grades of intraductal breast carcinoma. The staining reactivity of neoplastic cells to HPA lectin for demonstration of GalNac bearing glycoconjugate was primarily confined to cell membrane for grade I, to the Golgi zone for grade II, and diffusely to the cytoplasm in grade III.

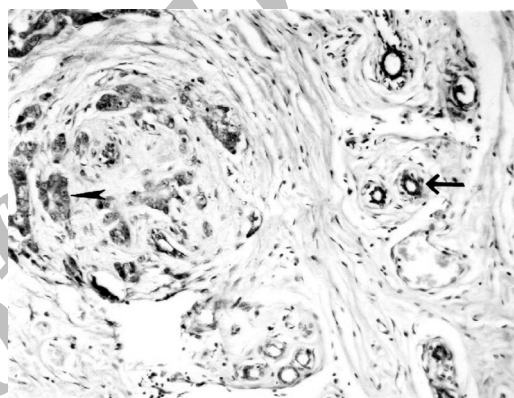


Fig 4: Mild reaction of neoplastic cells (large arrow head) and severe staining of endothelial cells (small arrow head) to HPA lectin were shown in grade I of intraductal carcinoma. HPA/Alcian blue pH=2.5 ×400.

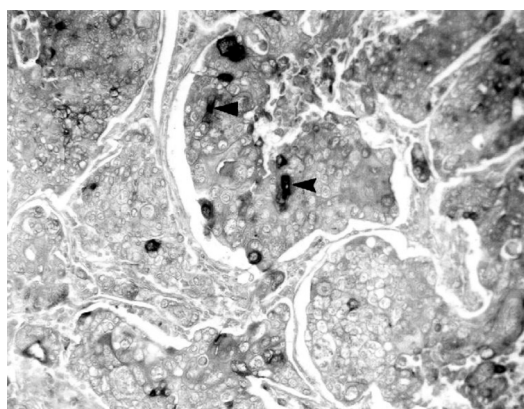


Fig 5: Heterogeneous reactions of neoplastic cells (arrow heads) to HPA lectin were shown in grade III of intraductal carcinoma. HPA/Alcian blue pH=2.5 ×400.

Extracellular matrix of tumor stroma reacts to lectin just in the periphery of neoplastic components in grade I. Furthermore the endothelium of tumor vascular components reacted to HPA lectin (Table 1; Fig. 4, 5, and 6).

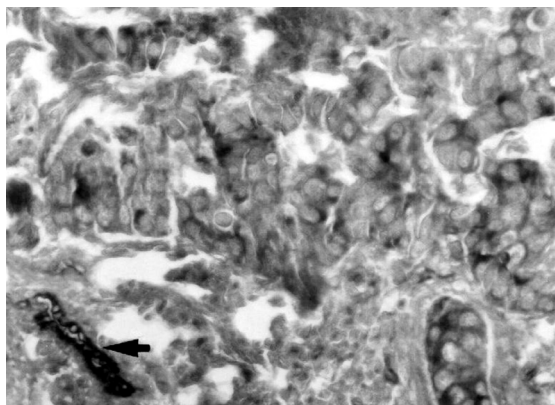


Fig 6: Severe and heterogeneous reaction of neoplastic cells (arrow) was shown in grade III of intraductal carcinoma. HPA/Alician blue pH=2.5 \times 400.

Table 1: Comparison of staining intensity of tumoral cells of intraductal breast carcinoma to helix pomatia lectin

Histopathological grading	I	II	III
Staining intensity			
Mean \pm SD	1.1 \pm 0.3	1.8 \pm 0.6	2.3 \pm 0.7

Values with different superscripts within each column are significantly different ($p < 0.003$).

Discussion

The data obtained in the present study showed that there is a statistically significant difference in staining properties between neoplastic cells of different grades (grade I to III) of intraductal carcinoma of the breast ($p < 0.003$). Furthermore, there was a more intense staining (for GalNac) in cancer cells of grade III compared to the neoplastic cells in grade I. The extent of staining reaction of neoplastic cells in grade II was intermediate to the ones in grades III and I.

Apparently, as the tumor histopathological grade increases in intraductal breast carcinoma, more GalNac bearing glycoconjugates accumulate in breast, which explains high staining properties of the cells to lectin. However, further investigation is needed to find out whether this type of changes in glycosylation pattern is the causative factor to the malignancy of the tumors or it is simply a product or by-product of tumor progression.

The pattern of staining reaction of cancer cells in grade I was confined to plasmalemma, whereas it was appeared in Golgi zone and diffusely distributed in cytoplasm in grades II and III, respectively. The latter finding indicates that not only the staining intensity of neoplastic cells changes while the tumor progresses, but also the pattern of staining is subject to extensive change. Recent studies

showed that there is also a different pattern of staining for galectin-3 (s- type lectin which exhibits galactose binding ability) in diffuse type of gastric carcinoma compared with intestinal type (11).

It seems that simultaneous with morphological changes of cancer cells such as nuclear pleomorphism and atypia, hyperchromasia, and disorganized architecture, lectin-staining properties of cells were changed. Finding out the timing of these changes and the relationship among these changes during the course of tumor progression might be potentially helpful in diagnosis, prognosis, and treatment of breast cancer. The study of Fukotomi and colleagues showed that there is a good association between gene amplification and carbohydrate structure in breast cancer cells. The positive rate of HPA was related to gene amplification of *c-myc* proto-oncogene (12).

Our results are consistent with the previous reports showing the presence of GalNac bearing glycoconjugates in breast (13), colorectal, and gastric cancer (14). There is a strong association between HPA binding properties of neoplastic cells and prognosis in patients of breast, colorectal and gastric cancers (13, 14).

Overexpression of N-acetylgalactosamine glycoproteins detected by light microscopy revealed that cytochemical HPA binding patterns are consistent with a fundamental disruption in normal glycobiosynthetic pathway attending to increase metastatic potential (15). On the other hand, there is not any association between HPA binding property and prognosis of head and neck cancers (16).

The abnormal cellular accumulation of glycoconjugates in neoplastic cells may be a result of a change in the rate of expression of glycosyltransferase, which is the enzyme responsible for addition of sugars to proteins (10).

Burchell and colleagues showed that in normal resting, pregnant, and lactating breast, mucin O-glycans are largely extended structures. In contrast, mucin O-glycans found in breast carcinoma is often truncated (10).

Lectin staining properties of the neoplastic cells may have a relevance to neoplastic process or may reflect the biological behavior of the tumor. Neoplastic cell transformation and metastasis is associated with altered carbohydrate composition (16).

Streets and colleagues found a single glycoprotein of 55 kDa in breast tumors that had HPA binding property, whereas it lacked this property in normal tissue. Further works showed that this glycoprotein is homologous

to immunoglobulin A heavy chain (17). The invasive potential and metastasis of cancer cells is a series of events in which adhesion and loss of adhesion are sequentially switched on and off. Loss or alteration of adhesion in malignant cells may lead to metastasis.

Aberrant glycosylation may lead to synthesis of abnormal glycoconjugate in cell surface that enable them to detach from their original place of growth and their transport to a new place of growth (16, 17, 18, 19).

Metastasis of cancer cells to axillary lymph node is the most powerful prognostic factor for breast cancer patients (20). Calafat and colleagues have reported that stromal cells and endothelium of vascular bed in tumor stroma reacted to PNA and UEA lectins (21).

Conclusion

Our results revealed that the endothelial cells

References:

1. Udo Jescheke, Joannis Mylonas, Kristiane Kunert-Keil, Naim Shabani et al. Expression of glycodelin protein mRNA in human ductal breast cancer carcinoma in situ, invasive ductal carcinoma, Their lymph node and distant metastasis and ductal carcinoma with recurrence. *Oncology Repor* 2005; 13: 413-419
2. Silvestrini R, Diadone MG, Luisi A, Boracchi P, Mezzeti M, Di Fron Andeola, Salvadori B, Veronesi U. Biologic and clinicopathologic factors of specific relapse types in node-negative breast cancer. *J Clin Oncol* 1995; 13(3): 697-704
3. Neville AM, Bettelheim R, Gelber RD, Save-Soderbergh, Davis BW, Reed R, Torhorst J, Golouuh R, Peterson HF, Price NK et al. Factors predicting treatment responsiveness and prognosis in node-negative breast cancer. *J Clin Oncol* 1992; 10(5): 696-705
4. Praizel Oksana, Evstigneeva Rima P, Yamskov Igor A, Shtil Alexander A. Fucose specific lectins in cancer rearch and diagnosis. *Drug Design Review* 2005, 2(5): 349-359
5. Thomas M, Noguchi M, Fonseca L, Kitagawa H, Kinoshita K, Miyazaki I. Prognostic significance of Helix Pomatia lectin and c-erb-2 oncoprotein in human breast cancer. *Br J Cancer* 1995; 68(3): 621-6.
6. Brooks SA. The involvement of Helix Pomatia lectin (HPA) binding N-acetylgalactosamine glycans in cancer progression. *Histol Histopathol.* 2000; 15(1): 143-158
7. Brooks SA, Leathem AJ. Expression of alpha-GalNac glycoprotein by breast cancers. *Br J Cancer* 1995; 71(5): 1033-1038
8. Martegani MP, Del Prete F, Gasbarri A, Natali PG, Bartolazi A. Structural variability of CD44v molecules and reliability of immunodetection of CD44 hsoforms using mAbs for CD44 variant exon products. *Am J Pathol.* 1999; 154(1): 291-300
9. Christine Coudrey, Jeffrey E Green. Metastases: the glycans connection. *Breast Cancer Res.* 2000, 2: 321-323
10. Bruchell Joy M, Mungul Arron, Taylor-Papadimitriou. O-Linked glycosylation in the mammary gland: changes that occur during malignancy. *J Mammary Gland Biol Neoplasia.* 2001; 6(3): 355-364
11. Tomotoka Shibata, Tsuoshi Noguchi, Shinsuke Takeno, Yoshiaki Takahanshi et al. Impact of nuclear galectin 3 expression on histological differentiation and vascular invasion in patients with esophageal squamous cell carcinoma. *Oncol Rep.* 2005, 13: 235-239
12. Fukotomi T, Hirohashi S, Tsuda H, Nanasawa T, Yamamoto H et al. The prognostic value of tumor associated carbohydrate structure correlated with gene amplification in human breast carcinomas. *Jpn J Sur* 1991, 21(5): 499-507
13. Leathem AJ, Brooks SA. Predictive value of lectin binding on breast cancer recurrence and survival. *Lancet* 1987; 9; 1(8541): 1054-1056
14. Schumacher DU, Randall CJ, Ramasy AD, Schumacher U. Is the binding of the lectin Helix Pomatia agglutinin of prognostic relevance in tumors of the upper aerodigestive tract. *Eur J Sur Oncol.* 1996; 22(6): 618-620
15. Brooks S A, Hall DM, Buley I. GalNac glycoprotein expression by breast cell lines primary breast cancer and normal breast epithelial membrane. *Br J Cancer* 2001, 85(7): 1014-1022
16. Laack E, Nikbakht H, Peters A, Kulger C, Jasiewicz Y, et al. Lectin histochemistry of resected adenocarcinoma of the lung. *Am J Pathol.* 2002; 160: 1001-1008
17. Streets AJ, Brooks SA, Dwek MV, Leathem AJ. Identification, purification and analysis of a 55 kDa lectin binding glycoprotein present in breast cancer tissue. *Clin Chim Acta* 1996; 254(1): 47-61

18. Spillane Andrew J., Nigel P. M. Sacks. Role of axillary lymph node surgery in early breast cancer: Review of the current evidence. *Aus Newz J Surg.* 2000; 70(7): 515-520
19. Guillot J, Guerry M, Konska G, Caldeifie-Chezet F, De Latour M, Penault-Llorca F. Modification of glycoconjugates during the carcinogenesis: the case of

mammary carcinoma. *Bull Cancer* 2004; 91(2): 141-58.
20. Noguchi M. Internal mammary sentinel node biopsy for breast cancer: Is it practicable and relevant? *Oncol Rep.* 2002; 9(3): 461-468
21. Calafat J, Janssen H. Binding of lectins to human mammary tumors: ultrastuctural study. *Breast Cancer Res Treat.* 1984; 4(3): 169-179



Archive of SID

مطالعه هیستوشیمیایی ان-استیل گلاکتوز آمین در گلیکوکونژوگه‌های سرطان اینتراداکتال پستان با لکتین HPA

محمدرضا عرب Ph.D.^۱، زهرا سپهری M.D.^۲، حسین ایمانی Ph.D.^۳،
مهربد کریمی M.D.^۴، فریدون سرکلزایی اول Ph.D.^۵

۱. دانشگاه علوم پزشکی زاهدان، دانشکده پزشکی، گروه آناتومی

۲. دانشگاه علوم پزشکی زاهدان، بیمارستان امام علی^(ع)

۳. دانشگاه بقیه الله، گروه آناتومی

۴. پژوهشکده رویان، گروه جنین‌شناسی

۵. دانشگاه علوم پزشکی زاهدان، دانشکده پزشکی، گروه پاتولوژی

✉ آدرس مکاتبه: زاهدان، صندوق پستی: ۴۹۳-۹۸۱۶۵، دانشگاه علوم پزشکی زاهدان، دانشکده پزشکی، گروه آناتومی

پست الکترونیک: [Email: mr_arabz@yahoo.com](mailto:mr_arabz@yahoo.com)

چکیده

دریافت مقاله: ۸۴/۴/۲۰، پذیرش مقاله: ۸۴/۹/۲

*** هدف:** شناسایی قند انتهایی ان استیل گلاکتوز آمین در گلیکوکونژوگه‌های قسمت‌های مختلف سلول در گریدهای سرطان اینتراداکتال پستان و مقایسه شدت رنگ‌آمیزی آن‌ها با هم

*** مواد و روش‌ها:** بلوک‌های پارافینی ۲۰ بیمار با تشخیص اینتراداکتال کارسینوما از فایل آسیب‌شناسی بیمارستان خاتم‌الانبیای زاهدان انتخاب شدند. لام‌های هماتوکسیلین انوزین تهیه شده توسط دو پاتولوژیست از نظر هیستوپاتولوژیک گریه‌گذاری شدند. لام‌های ۵-۷ میکرومتری تهیه شده با لکتین HPA رنگ‌آمیزی شدند. سپس از نظر شدت رنگ‌آمیزی درجه‌بندی شده و اطلاعات به دست آمده با نرم‌افزار SPSS با تست مان ویتنی تجزیه و تحلیل شد.

*** یافته‌ها:** نتایج این مطالعه نشان داد که الگوی رنگ‌آمیزی با لکتین HPA و شدت آن در سلول‌های تومورال گریدهای مختلف سرطان اینتراداکتال پستان با هم متفاوت است ($p < 0.003$). بیشترین شدت واکنش سلول‌های تومورال به لکتین در گریه III و کمترین آن در گریه I دیده شد. سلول‌های تومورال گریه II شدت رنگ‌آمیزی متوسطی از خود نشان دادند. هم‌چنین ناحیه واکنش در سلول‌های تومورال گریه I اغشا سلولی و در گریه III ناحیه گلژی سلول رخ داد، در حالی که الگوی واکنش در گریه II به صورت پراکنده و منتشر در سراسر سیتوپلاسم ارزیابی شدند.

*** نتیجه‌گیری:** بر اساس اطلاعات این تحقیق میزان واکنش به لکتین و شدت آن در گریدهای مختلف سرطان پستان متفاوت از هم ارزیابی شد که گلیکوزیلاسیون غیرمعمول روند نئوپلازی علت این واکنش می‌تواند باشد. به نظر می‌رسد الگو و شدت واکنش سلول‌های تومورال در سرطان اینتراداکتال پستان به لکتین HPA می‌تواند نشان دهنده رفتار تهاجمی سلول‌های تومورال باشد که از نظر بالینی حائز اهمیت است.

کلیدواژگان: پستان، اینتراداکتال کارسینوما، گلیکوکونژوگه، لکتین