

Advanced Therapy Medicinal Products in Vitiligo; Current Status, Future Prospect, and Approved Treatments

Shahriar Ghashghaei, M.D., Mahkameh Abbaszadeh, M.D., Shahedeh Karimi, M.D., Leila Ataie-Fashtami, M.D.* , Amir Bajouri, M.D., Massoud Vosough, M.D., Ph.D.*

Department of Regenerative Medicine, Cell Science Research Center, Royan Institute for Stem Cell Biology and Technology, ACECR, Tehran, Iran

Abstract

Vitiligo is an auto-immune disease, causing depigmentation of skin in 0.2-1.8% of global population. Topical corticosteroids and calcineurin inhibitors are the only treatments with firm evidence of optimal effectiveness with considerable side effects. Phototherapies might not induce serious side effects, although the effectiveness of the method is limited. Advanced therapy medicinal products (ATMPs) are emerging treatment modalities based on correction and replacement of affected genes, damaged tissues or cells in treatment of difficult-to-treat diseases. Due to optimal effectiveness and minimal side effects, ATMPs have recently gained much attention in order to develop new treatments. In this review, the ATMPs for treating vitiligo were along with its clinical success, affordability and cost-effectiveness. Currently, the main ATMP based products using in treatment of vitiligo are non-cultured epidermal cell, melanocytes, and hair follicle melanocytes. These products have shown promising results in the non-responding vitiligo patients. Furthermore, mesenchymal stem cells and multi-lineage differentiating stress enduring cells are other new potential modalities. Recently, Iranian Food and Drug Administration (IR-FDA) authorized the first cell-based product for vitiligo. This product is autologous suspension of keratinocytes and melanocytes. Although ATMPs are efficient and could be cost-effective in long term, the most important obstacle is affordability of them. This could be facilitated by insurance companies and instalments payment programs from manufacturers.

Keywords: Cell Therapy, Immune System Diseases, Keratinocytes, Melanocytes, Vitiligo

Citation: Ghashghaei Sh, Abbaszadeh M, Karimi Sh, Ataie-Fashtami L, Bajouri A, Vosough M. Advanced therapy medicinal products in vitiligo; current status, future prospect, and approved treatments. *Cell J.* 2023; 25(3): 143-157. doi: 10.22074/CELLJ.2023.557550.1067.

This open-access article has been published under the terms of the Creative Commons Attribution Non-Commercial 3.0 (CC BY-NC 3.0).

Introduction

Vitiligo is an auto-immune disease affecting 0.2-1.8% of world's population causing depigmentation of skin in both children and adults (1). Melanocyte destruction in vitiligo is the outcome of different etiologies. These include autoimmune reactions, oxidative stress, generation of inflammatory mediators, and melanocyte detachment. Vitiligo is classified into segmental and non-segmental types (SV and NSV) which are different in the courses, treatment modalities, and prognosis (2). The disfiguration resulted by vitiligo leads to impairment in quality of life in patients (3). There are several medical treatments available for vitiligo including: systemic and topic pharmacological therapies such as corticosteroids, calcineurin inhibitors, vitamin D3 analogs, pseudocatalase/superoxide dismutase, 5-fluorouracil (5-FU), methotrexate (MTX), prostaglandin F2 alpha analogs, basic fibroblast growth factor (bFGF)-derived peptide, minocycline, statins, azathioprine, and cyclosporine. Physical treatments include phototherapy narrow-band ultraviolet B (UVB), psoralen combined with UVA (PUVA) and laser therapy EL (Excimer light). In addition, depigmentation treatments such as monobenzyl ether of hydroquinone (MBEH) and

cryotherapy are other therapeutic modalities (2). In a study by Van et al. (4), Vitilinox® herbal bioactive molecule in combination with nbUVB was indicated as an effective therapy in vitiligo. Vitilinox® consists of two components: Skin Prep lotion (containing-centipeda cunninghamii, aloe vera, terpinol-4-ol and dihydro avenanthramide-D) and Emmolient (containing- black cumin seed oil, black pepper coleus forskohlii, Psoralea coryfolia, thyme oil, myrrh and neroli extracts). Vitilinox® was applied in the affected area and then the area irradiated weekly over 12 weeks. Interestingly, 87% of the patients had 50% more re-pigmentation rate compared to the control group. In 2022, recent findings were presented during the American Academy of Dermatology Annual Meeting and showed that Ruxolitinib cream was associated with clinically significant improvement in facial and total body re-pigmentation (5, 6). Oral JAK inhibitor, Ritlecitinib, induced 60 to 70% re-pigmentation of the face after 12 months (7).

Furthermore, platelet-rich plasma (PRP) application seems to be an effective alternative therapy in vitiligo, but

Received: 11/July/2022, Revised: 16/January/2023, Accepted: 20/February/2023

*Corresponding Address: P.O.Box: 16635-148, Department of Regenerative Medicine, Cell Science Research Center, Royan Institute for Stem Cell Biology and Technology, ACECR, Tehran, Iran

Emails: ataiefash@gmail.com, masvos@royaninstitute.org



Royan Institute
Cell Journal
(Yakhteh)

www.SID.ir

there are some restricting factors such as small samples of the patients in clinical trials, not enough controlled clinical studies (6 studies), and short follow-up period which reduced credibility of this study (8). Studies have shown that the proportions of patients with repigmentation rates of 75, 50, and 25% were significantly higher in PRP plus 308-nm excimer laser therapy than 308-nm excimer laser monotherapy (9). Recently, cell-based therapies provided promising outcomes in regenerative medicine (10). Although effective in general, these treatments have certain limitations, and regarding the relapsing nature of disease, sometimes the current treatments can be “frustrating” for patients (2). Pharmaceutical therapies include a variety of agents (2); Yet, enough evidence on the optimal effectiveness (more than 75% re-pigmentation) of only a few treatments have been validated (11). The mentioned conventional treatments impose significant side effects (2).

On the contrary, patients who have received phototherapy (all types) did not exhibit severe side effects (2), but the effectiveness of phototherapy is limited (12). Limited access to this treatment modality is also a major concern. Considering this, novel modalities for vitiligo treatment have been emerged. Advanced therapy medicinal products (ATMPs) are emerging novel products in modern medicine known as the next line of treatment for the patients who do not respond to regular treatments (13). ATMPs are promising therapeutic modalities for a variety of diseases including dermatological disorders, however despite of their high efficacy, ATMPs are expensive (14).

Recently, Iranian Food and Drug Administration (IR-FDA) authorized the first Iranian live cell-based product for vitiligo. This is the first ATMP in Iranian Drug List (IDL). This product is autologous suspension of keratinocytes and melanocytes injected intraepidermally into the hypo- or depigmented area. Royan Institute developed this technology and Cell Tech Pharmed Co. conducted process development. The registered commercial name for this product is RecolorCell®. Two other products were approved for vitiligo patients in US and Japan. The U.S. Food and Drug Administration gives pre-market approval to RECELL, which is an autologous cell harvesting device. This device is indicated for the treatment of acute thermal burn wounds and other dermatological complications like vitiligo. Also, JACE is an epidermal-derived cell sheet which received Japan PMDA in 2007 for skin disorders like vitiligo. This product has been applied for treating giant congenital melanocytic nevus (GCMN). It is reported that most of the grafts survived, and the dark brown color of the nevus was reduced (15). Also JACE application was found to contribute to the patient survival up to 7 weeks after burn (16). In the current review, we will discuss current treatments for vitiligo, promising ATMPs along with their challenges and cost-effectiveness and finally the current clinical trials in this field.

Pathophysiology of vitiligo

Pathogenesis of vitiligo, genes

As many other autoimmune diseases, genetic factors are important in vitiligo. From the genetic viewpoint, vitiligo

behaves as a typical polygenic condition. However, the polygenicity is rather low and heritability high compared to the other complex traits. Thereupon, the genetic predisposition of vitiligo has been easier to detect and understand compared to the other hereditary disorders (17). This assumption raised based on the fact that one's siblings have higher chance of developing the condition. The odds rise four times in identical twins.

Genome variations in vitiligo subjects for innate and adaptive immune system was discovered. The affected genes are as follows: i. Innate immune system: *NLRP1*, *IFIH1*, *CASP7*, *C1QTNF6* and *TRIF* and ii. Adaptive immune system: *FOXP3*, *BACH2*, *CD80*, *CCR6*, *PTPN22*, *IL-2R*, alpha *GZMB* and HLA class I and II (18).

Pathogenesis of vitiligo, key cells

In vitiligo patients, melanocytes are more susceptible to oxidative stress compared to unaffected population. Atypical cellular structures in their melanocytes - including endoplasmic reticulum, mitochondria and melanosome structure-support the mentioned statement. The vulnerability against oxidative stress is followed by innate and adaptive immune responses. Secretion of interleukin 1-beta, 6, 8 and heat shock proteins by natural killer cells along with CD8⁺ activity, interferon gamma (IFN- γ) and CXCL-10 production are examples of innate and adaptive immune system response, respectively (18). The mentioned genes and cells could be potential targets for gene therapy and cell-based therapy. Despite the common belief, melanocytes in vitiligo patients are not completely lost or deactivated. Seleit et al. (19) showed the presence of melanocytes and melanocyte stem cells in interfollicular epidermis and follicular epidermis in affected skin. Moreover, they demonstrated the correlation between the population of precursors and histopathology grading.

Clinical trials using ATMPs for vitiligo treatment

A search in "www.clinicaltrials.gov" website using the showed 184 different clinical trials in this field. After careful assessment of results, 18 ATMP-based studies were identified and the related data was collected. Trials that contained published results were summarized in Table 1 and ongoing trials in Table 2. As shown in Figure 1, half of all clinical trials were completed and 30% are whether terminated, withdrawn or have an unknown status. Only 7 clinical trials had published results which applied two main methods (Table 1).

The first method is melanocyte-keratinocyte cell suspension (MKCS) transplantation classified based on the source of melanocytes:

1. Non-cultured epidermal cell suspension (NCECS) (20-26)
2. Outer root sheath hair follicle suspension (ORSHFS) (20)
3. Cultured melanocyte transplantation

The second method assessed the effectiveness of combining NCECS and non-cultured dermal cell suspension transplantation (26).

Table 1: Published ATMP-based clinical trials for vitiligo treatment

N	Trial code	Trial official title	Status	Trial start and end	No. of patients	Intervention	Results
1	NCT02510651	Effect of procedural-related variables on melanocyte-keratinocyte suspension transplantation in non-segmental stable vitiligo: a clinical and immunohistochemical study	Completed (phase I)	January 2010- June 2014	37	<p>Intervention 1: NCECS</p> <p>Procedure: Patients receive melanocyte-keratinocyte suspension obtained from gluteal area or front of thigh (n=31). The recipient site is either prepared with Cryobles (n=21) or CO₂ laser (n=10).</p> <p>Devices: CO₂ laser</p> <p>Intervention 2: ORSHFS</p> <p>Procedure: Patients receive melanocyte-keratinocyte suspension obtained from hair follicle units in ORSHFS and the recipient sites are prepared with CO₂ laser (n=6).</p> <p>After intervention 1 and 2, recipient areas undergo NB-UVB phototherapy.</p> <p>Devices: CO₂ laser, NB-UVB lamp</p>	<p>Intervention 1</p> <p>No. of patients with proper color match: 6</p> <p>No. of patients with more than 75% repigmentation: 2</p> <p>No. of lesions with more than 75% repigmentation: 10 (out of 61)</p> <p>Effect of preparation procedures: Lesions located in distal fingers prepared with cryoblebbing had significantly higher repigmentation rate comparing to those prepared with CO₂ laser. Though, lesions prepared with cryoblebbing took more time to regenerate and had higher infection rate.</p> <p>All lesions located in distal fingers prepared with cryoblebbing (n=10) and none of the lesions located in distal fingers prepared with CO₂ laser (n=24) had more than 90% repigmentation.</p> <p>Intervention 2</p> <p>No. of patients with proper color match: 6 (out of 6)</p> <p>No. of patients with more than 75% epigmentation: 2</p> <p>No. of lesions with more than 75% epigmentation: 5 (out of 24) (20)</p>
2	NCT03013049	A comparative study between autologous non-cultured epidermal cell suspension versus combination of autologous non-cultured epidermal cell suspension and non-cultured dermal cell suspension in stable vitiligo	Completed	January 2016- June 2017	40	<p>Intervention 1: NCECS</p> <p>Procedure: patients receive keratinocyte-melanocyte suspension obtained using split-thickness skin graft.</p> <p>Devices: N/A</p> <p>Intervention 2: Non-cultured dermal cell suspension Procedure</p>	<p>Group 1: Twenty patients with 3-6 months' stability subgroup A (n=10)</p> <p>Group 1 patients undergone Intervention 1 (n=10) with 24 months follow up</p> <p>No. of patients with more than 75% repigmentation: 3</p>

Table 1: Continued

N	Trial code	Trial official title	Status	Trial start and end	No. of patients	Intervention	Results
						Procedures: patients receive dermal cell suspension obtained using a 4-mm skin punch biopsy.	Group 1 patients undergone Intervention 1 and 2 (n=10) with 24 months follow up Subgroup B (n=10)
						Devices: four millimeter skin punch biopsy	No. of patients with more than 75% repigmentation: 10 (8 out of 10 had more than 90% repigmentation) Results Group 2: Twenty patients more than 12 months' stability Group 2 patients undergone Intervention 1 (n=10) with 24 months follow up No. of patients with more than 75% repigmentation: 6 Group 2 patients undergone Intervention 1 and 2 (n=10) with 24 months follow up No. of patients with more than 75% repigmentation: 7 (26)
3	NCT00830713	Safety and efficacy of melanocyte-keratinocyte transplantation in the treatment of vitiligo	Completed (phase III)	January 2009-October 2011	23 Note: According to clinicaltrials.gov the number of recruited patients in this study is 40; yet, we authors changed it to 23 patients as reporter in the related publication.	Intervention: NCECS Procedure: patients receive melanocytes and keratinocyte suspensions obtained from lateral part of gluteal area using knives. Dermabrasion was performed on recipient sites before application of suspension.Devices Devices: Surgical knife	No. of patients with more than 65% repigmentation: 14 (5 out of 14 patients had more than 95% repigmentation) Follow up duration: At least 3 months Adverse events: pain (n=5), hypopigmentation/koebnerization (n=7), and scarring (n=1) (21).
4	NCT03668834	A comparative study between recipient site preparation using dermabrasion,liquid nitrogen induced blister and dermarolling system in autologous non-cultured epidermal cell suspension procedure in stable vitiligo patients	Completed	January 1, 2018-June 30, 2019	36	Intervention 1: NCECS Procedure: Patients receive non-cultured epidermal cell suspension using an 18-G needle. The suspension is placed on the site and spread evenly. Procedure	Intervention 1 (36 lesions) No. of lesions with more than 75% repigmentation: 20 No. of lesions with proper color match: 17 Results Intervention 2 (36 lesions)

Table 1: Continued

N	Trial code	Trial official title	Status	Trial start and end	No. of patients	Intervention	Results
						<p>Dermabrasion is carried out on recipient area before application of Manekshaw's dermabrader. Dermabrasion is expanded 5 mm beyond margins of recipient area.</p> <p>Devices: Manekshaw's dermabrader,</p> <p>Intervention 2: NCECS</p> <p>Procedure: Micro needling is performed on recipient area using micro needling device.</p> <p>Next, an 18 G syringe is used to apply non-cultured epidermal cell suspension on the area. The suspension is spread evenly.</p> <p>Devices: Micro needling device containing 540 microneedles in 8 rows, each 0.25 mm in length</p> <p>Intervention 3: NCECS</p> <p>Procedure: Liquid nitrogen spray is used to generate blisters on achromic areas. The spray remains for 10-20 seconds. Twenty-four hours later, an 18 G syringe is used to empty the blister and apply non-cultured epidermal cell suspension on lesions. The suspension is spread evenly.</p> <p>Devices: N/A</p> <p>Note: Each patient has at least 3 depigmented lesions. Lesions randomly receive one of the interventions.</p>	<p>No. of lesions with more than 75% repigmentation: 1</p> <p>No. of lesions with proper color match: 8</p> <p>Lesions undergone intervention 2</p> <p>Intervention 3 (36 lesions)</p> <p>No. of lesions with more than 75% repigmentation: 17</p> <p>No. of lesions with proper color match: 7</p> <p>(24)</p>
5	NCT00631865	Autologous transplantation of melanocytes for treatment of vitiligo skin	Completed (phase III)	February 2009-May 2015	10	<p>Intervention: NCECS</p> <p>Procedure: A biopsy sized 1 cm² is harvested from patients' normal skin. Biopsies are utilized to create melanocyte suspensions. Next, the suspension is directly injected into epidermis.</p> <p>Devices: N/A</p>	<p>No. of patients with more than 75% repigmentation: 4 (23).</p>

Note:
According to clinical trials.gov the number of recruited patients in this study is 300; yet, we authors changed it to 10 patients as reported in the related publication.

Table 1: Continued

N	Trial code	Trial official title	Status	Trial start and end	No. of patients	Intervention	Results
6	NCT01640678	Autologous cell suspension grafting using ReCell in vitiligo and piebaldism patients: a randomized controlled pilot study	Completed (phase IV) Note: According to clinicaltrials.gov the status of this study is "unknown"; yet, based on published result we authors changed it to "completed".	June 2012-December 2013	3 Note: According to clinicaltrials.gov the number of recruited patients in this study is 10; yet, based on published reports, only 3 patients were suffering vitiligo and the other 7 were cases of piebaldism.	Intervention 1: NCECS Procedure: Patients received epidermal cell suspension obtained using ReCell. Recipient sites were prepared using laser and suspensions were sprayed on them. Afterwards, patients undergo phototherapy. Devices: ReCell autologous cell harvesting device, CO ₂ laser (10,600 nm), UV lamp Intervention 2: CO ₂ laser and UV lamp Procedure Patients undergo laser therapy and Devices Devices: CO ₂ laser (10,600 nm), UV lamp	Effect of preparation procedures: Superficial full surface ablation with 144 micrometer depth is an efficient method to prepare recipient area. On contrary, fractional CO ₂ laser is not an effective method before cell suspension transplantation. Note: Note: These conclusions are derived from data of 10 patients of which 3 had vitiligo and results were not separated. Therefore, the presented conclusion is not reliable (25).
7	NCT02156427	A multicenter double-blind placebo-controlled trial of non-cultured epidermal cellular grafting versus hyaluronic acid for repigmenting stable leukoderma (vitiligo and piebaldism)	Completed (phase III)	April 29, 2014-April 10, 2018	27	Intervention 1: NCECS Procedure: patients receive keratinocytes and melanocytes cell suspensions prepared with VitiCell. Suspensions contain hyaluronic acid. Devices: VitiCell Intervention 2: Placebo Placebo Procedure: patients receive hyaluronic acid. Devices: N/A Note: Each patient has at least 2 depigmented lesions on trunk or extremities. Lesions randomly receive one of the interventions	Intervention 1 Group A: Treated areas located at hand, elbow and wrist (11 patients) No. of patients with more than 50% repigmentation: None Group B: Treated areas located at areas other than those in group A (16 patients) No. of patients with more than 50% repigmentation: 8 Duration of follow-up: at least 12 months Intervention 2 Group A: Treated areas located at hand, elbow and wrist (11 patients) No. of patients with more than 50% repigmentation: None

Table 1: Continued

N	Trial code	Trial official title	Status	Trial start and end	No. of patients	Intervention	Results
							Group B: Treated areas located at areas other than those in group A (16 patients)
							No. of patients with more than 50% repigmentation: 1
							Follow-up duration: at least 12 months
							Overall, out of total 27 patients, 9 had more than 50% repigmentation (22).

Table 2: Ongoing ATMP-based clinical trials for vitiligo treatment

N	Trial code	Trial official title	Status	Trial start and end	No. of patients	Intervention
1	NCT04271501	A prospective blinded randomized within-subject controlled clinical feasibility study to evaluate Recell and melanocyte keratinocyte transplantation procedure for repigmentation of stable vitiligo lesions	Recruiting	September 25, 2020-December 2021	10	<p>Intervention 1: NCECS</p> <p>Procedure: Implementation of melanocyte keratinocyte (MK) suspension diluted 1:5 to surgically prepared depigmented regions.</p> <p>Devices: Recell and UVB lamp</p> <p>Intervention 2: NCECS</p> <p>Procedure: Implementation of MK suspension diluted 1:10 to surgically prepared depigmented regions</p> <p>Devices: Recell and UVB lamp</p> <p>Intervention 3: NCECS</p> <p>Procedure: Implementation of MK suspension diluted 1:20 to surgically prepared depigmented regions</p> <p>Devices: Recell and UVB lamp</p>
2	NCT04374435	Evaluating the efficacy of the melanocyte keratinocyte transplantation procedure in the treatment of vitiligo	Recruiting	September 29, 2017 - December 1, 2021	17	<p>Intervention 1: NCECS</p> <p>Procedure: Donor cells are obtained from a 2×2 cm² region on patient's thigh by a surgical blade. Cells are dissociated into one cell suspension. The host area is removed with laser. Half of cells are applied to the host area.</p> <p>Devices: Erbium YAG laser</p>

Table 2: Continued

N	Trial code	Trial official title	Status	Trial start and end	No. of patients	Intervention
						Intervention 2: NCECS Procedure: Donor cells are obtained from a 4×2 cm ² region on patient's thigh containing epidermis. The procedure carried out using Negative Pressure Instrument. Cells are dissociated into one cell suspension. Half of cells are applied the host area. Devices: Negative pressure instrument Intervention 3: NCECS Procedure: Donor cells are obtained from a 4×2 cm ² region on patient's thigh containing epidermis. Cells are not dissociated. The procedure carried out using Negative Pressure instrument. The epidermis cells are applied to the host area. Devices: Negative pressure instrument
3	NCT04320160	Structural evaluation of human melanocytes after the use of autologous platelet-rich plasma versus fractional carbon dioxide laser (Fr:CO ₂ Laser) in treatment of vitiligo: a histological, immunohistochemical and molecular study	Not yet recruiting	August 1, 2020 - October 24, 2022	30	Intervention: PRP Procedure: Eight milliliter of patient's blood is centrifuged at 1,500 rpm for 5 minutes. Then, injected in areas separated 1mm with intradermal microinjections - 0.1 mL per injection. Devices: 30-G needle Intervention 2: Fractional CO ₂ laser Procedure: Fifteen lesions are treated with laser. Scanner spot size is adjusted according to lesion size. Adopted density is 0.6 in the static mode. Two passes with minimal overlap is delivered. A thin rim of unaffected skin is also treated. Devices: Fr: CO ₂ laser (10,600 nm; KES corporation, Beijing, China)
4	NCT03497208	Comparative study of surgical treatment of vitiligo: microneedling versus microneedling with suspension of un-cultured epidermal cells	Unknown	March 13, 2018 - December 13, 2019	10	Intervention 1: NCECS Procedure: Cells are obtained from patients scalp skin and melanocytes and keratinocytes are isolated as suspension. Then, micro needling dermabrasion is performed followed by application of suspension in affected areas. Fifteen days' post-surgery, patients are subjected to NB-UVB phototherapy sessions twice a week. Devices: 0.25 mm needles, NB-UVB lamp

Table 2: Continued

N	Trial code	Trial official title	Status	Trial start and end	No. of patients	Intervention
						<p>Intervention 2: Micro needling and phototherapy</p> <p>Procedure: Micro needling dermabrasion is performed. Fifteen days' post-surgery, patients are subjected to NB-UVB phototherapy sessions twice a week.</p> <p>Devices: 0.25 mm needles, NB-UVB lamp</p>
5	NCT03717025	A comparative study between autologous mini punch grafting, suction blister grafting and non-cultured epidermal cell suspension on resistant sites in stable vitiligo	Unknown	July 1, 2017 - November 2018	20	<p>Intervention 1: Mini punch grafting</p> <p>Procedure: Skin grafts are obtained from superior lateral part of thigh or gluteal region with 2-2.5 mm distance from each other. Grafting is performed by mini punch devices. Afterward, grafts are directly transplanted into recipient region.</p> <p>Devices: Mini punch device</p> <p>Intervention 2: Suction blister epidermal grafting</p> <p>Procedure: Blisters are acquired from superior lateral part of thigh by mean of suction apparatus. Recipient region is surgically prepared by dermabrasion.</p> <p>Devices: Suction apparatus</p> <p>Intervention 3: NCECS</p> <p>Procedure: Split thickness skin graft procedure is utilized to acquire cells from a donor site sized 1/10 of recipient region. The specimen is proceeded into suspension and transferred into dermabraded recipient region.</p>
6	NCT01923142	Double blind within-subject controlled study of autologous hair follicle outer-root-sheath melanocytes transplantation in the treatment of vitiligo	Terminated (Phase II)	January 2014 - June 2014	4	<p>Intervention 1: ORSHFS</p> <p>Procedure: A suspension of autologous outer-root-sheath melanocytes is implemented into dermabraded areas. Suspension is prepared from patient's hair follicles and patient's serum in affected areas. Then, UVB phototherapy sessions are implemented starting from 5th week after procedure until the end of 12th week. The sessions are 3 days per week.</p> <p>Devices: UVB lamp</p> <p>Intervention 2: Placebo</p>

Table 2: Continued

N	Trial code	Trial official title	Status	Trial start and end	No. of patients	Intervention
						<p>Procedure: A suspension of saline and patient's serum in affected areas is implemented into dermabraded areas. Then, UVB phototherapy sessions are implemented starting from 5th week after procedure until the end of 12th week. The sessions are 3 days per week.</p> <p>Devices: UVB lamp</p>
7	NCT03022019	Autologous cell suspension grafting using ReNovaCell in non-segmental vitiligo patients: a randomized controlled study	Terminated	December 2016 - May 14, 2019	17	<p>Intervention 1: NCECS</p> <p>Procedure: Prior to study, patients undergo NB-UVB (311 nm) sessions and receive anti-inflammatory treatment for 6 months. The phototherapy is continued until end of study. Afterwards, ReNovaCell is utilized to acquire cells for autologous epidermal cell suspension.</p> <p>Devices: ReNovaCell, UVB lamp</p> <p>Intervention 2: Anti-inflammatory treatment and UVB lamp</p> <p>Procedure: Prior to study, patients undergo NB-UVB (311 nm) sessions and receive anti-inflammatory treatment for 6 months. The phototherapy is continued until end of study.</p> <p>Devices: UVB lamp</p> <p>Note: Each patient receives both interventions on two comparable specified lesions.</p>
8	NCT03155698	Treatment of acral vitiligo: narrowband ultraviolet-B and microneedling with and without platelet rich plasma	Not yet recruiting	August 2021 - December 2021	50	<p>Intervention 1: PRP</p> <p>Procedure: Micro needling is performed using Dermapen for 10 minutes. Micro needling is carried out in four directions on affected skin; vertical, horizontal and the two diagonal. Afterwards, PRP is tropically placed. The mentioned procedure is repeated every 15 days. Along with the stated procedure, NB-UVB phototherapy with 2 sessions per week for 6 months is performed. Dosing starts from 0.21 J/cm² regardless of skin type and increases every session by 20% until achieving minimal erythema dose.</p> <p>Devices: Dermapen, NB-UVB lamp</p> <p>Intervention 2: Micro needling and NB-UVB</p>

Table 2: Continued

N	Trial code	Trial official title	Status	Trial start and end	No. of patients	Intervention
						<p>Procedure: Micro needling is performed using Dermapen for 10 minutes. Micro needling is carried out in four directions on affected skin; vertical, horizontal and the two diagonal. Along with the stated procedure, NB-UVB phototherapy with 2 sessions per week for 6 months is performed. Dosing starts from 0.21 J/cm² regardless of skin type and increases every session by 20% until achieving minimal erythema dose.</p> <p>Devices: Dermapen, NB-UVB lamp</p>
9	NCT01629979	Efficacy and tolerance of transplantation of harvested epidermal cells and narrow-band UVB in vitiligo	Completed (Phase II/ III)	May 2011 - November 2012	23	<p>Intervention 1: NCECS</p> <p>Procedure: The recipient area is dermabraded by laser. Using a dermatome, a superficial skin sample is obtained and converted into suspension. Then, the suspension is spread on recipient area. After 4 weeks, lesions undergo NB-UVB therapy 2 sessions per week for 3 months.</p> <p>Devices: Erbium: Yag laser, NB-UVB band</p> <p>Intervention 2: UVB treatment</p> <p>Procedure: After 4 weeks, untreated lesions undergo NB-UVB therapy 2 sessions per week for 3 months.</p> <p>Devices: NB-UVB band</p> <p>Note: Each patient has at least 2 depigmented lesions. Lesions each receive one of the interventions.</p>
10	NCT01822379	Comparative study of the use of trypsin versus dispase in melanocyte-keratinocyte transplantation for the treatment of vitiligo	Withdrawn (Phase II/ III)	May 2010 - July 2012	0 (never initiated)	<p>Intervention 1: NCECS</p> <p>Procedure: Trypsin is used to isolate melanocytes and keratinocytes.</p> <p>Devices: N/A</p> <p>Intervention 2: NCECS</p> <p>Procedure: Dispase is used to isolate melanocytes and keratinocytes.</p> <p>Devices: N/A</p> <p>Note: Each patient has at least 2 depigmented lesions. Lesions each receive one of the interventions.</p>

Table 2: Continued

N	Trial code	Trial official title	Status	Trial start and end	No. of patients	Intervention
11	NCT01511965	Study of applications of autologous epidermal cells in liquid phase in the treatment of vitiligo	Completed (Phase II/III)	May 2011 - November 2012	23	<p>Intervention 1: NCECS</p> <p>Procedure: Epidermal cells are obtained from the patient and convert into suspensions using Viticell. Then recipient area is desepidermised with utility of laser. Suspensions are applied to lesions. After the washout period, patients receive phototherapy.</p> <p>Devices: Viticell</p> <p>laser Erbium: YAG, UVB lamp</p> <p>Intervention 2: NCECS</p> <p>Procedure: Patients receive phototherapy. After the washout period, epidermal cells are obtained from the patient and convert into suspensions using Viticell. Then recipient area is desepidermised with utility of laser. Suspensions are applied to lesions.</p> <p>Devices: Viticell, laser Erbium: YAG, UVB lamp</p>

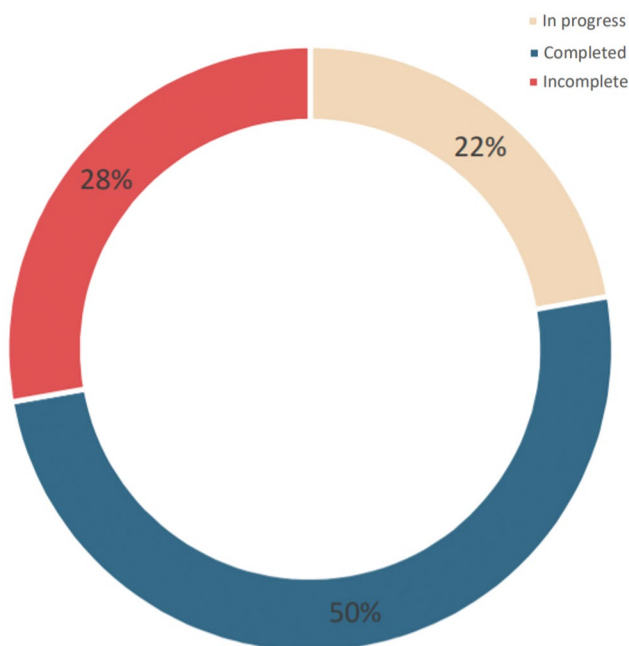


Fig.1: Status of clinical trials examining advanced therapy medical products (ATMPs) in treatment of vitiligo.

Promising ATMPs for treatment of vitiligo, new comings

Mesenchymal stromal cells

To identify the difference between normal skin and

vitiligo normal-lesional junction skin, RNA-sequencing test has been performed on different skin samples. The results illustrated higher expression of *FoxO*, and phosphate and tensin homolog (*PTEN*) in the affected skin. Therefore, *PTEN* can be recognized as initiation factor for vitiligo (27). MSCs can release exosomes which play a key role in the repairment of affected skin by inducing PTEN/mTOR pathway. So MSCs cause an increase in phosphatidylinositol 3 kinase, protein kinase B and mTOR signaling and decrease in PTEN leads to protection against oxidative stresses in melanocytes along with depletion in their apoptosis rate. MSCs suppress immune reactions and mediate mechanisms that change the T-cell subset polarization from proinflammatory (Th1, Th17) subsets to anti-inflammatory Th2 and Treg cells. On the other hand, the anti-inflammatory cytokines IL-10 and TGF-β are highly expressed on Treg cells, which directly suppress responder T cells. Briefly, MSCs modulate immune destruction of melanocytes by regulating cytokine secretion and the balance of T-cell subsets.

Moreover, extracellular vesicles (EVs) released from MSCs, mediate immunomodulatory effects (28). MSCs have major impact on improvement of detoxification, cell proliferation and morphology of melanocytes. MSCs can cause a rise in nuclear factor-erythroid related factor-2 (NFERF2) which promotes the antioxidant response in melanocytes. MSCs can be considered as

promising therapeutic modality for vitiligo in future (27). It is worthwhile to mention that utilizing MSCs is deemed to rise controversy. Some studies indicate that MSCs inhibit melanocyte differentiation through over-expression of transforming growth factor- β 1 (TGF β 1). Overexpression of this factor down-regulates tyrosinase leading to decline in production of melanin (29).

Moreover, in a study conducted by Paino et al. (30) they have shown that dental pulp stem cells (DPSCs) are capable of spontaneously differentiating into mature melanocytes. Despite the lack of enough data about the exact mechanisms that mediate immunomodulatory effects of MSCs in vitiligo, MSC therapy is common because patients have benefits after MSCs injection (28).

Induced pluripotent stem cells

Also it has been shown that genetically stable melanocytes can be efficiently differentiated from transgene-free human induced pluripotent stem cells (hiPSCs) generated from two different types of cutaneous cells: human primary melanocytes (HMs) and human dermal fibroblasts (HDF51) (31). On the other hand, Mull et al. (32), have proved that it is possible to harvest sufficient amount of patient-specific melanocytes by the differentiation of hiPSCs for potential therapeutic purposes.

Multi-lineage differentiating stress enduring cells

MUSE cells are pluripotent cells available in mesenchymal tissues regulating regeneration and healing after tissue damage. One notable superiority of these cells over embryonic stem cells is that they are non-tumorigenic. The other favorable feature of MUSE cells is their immunomodulatory effect which suggest a promising therapeutic modality for unstable vitiligo. Moreover; these cells decrease the chance of graft rejection and cause decline in CD8⁺ T cells (33). All mentioned methods are potential candidates that may enter clinical trials.

Clinical trials using ATMPs for vitiligo

We checked www.clinicaltrial.gov for ATMP products in vitiligo patients. After analysis, none of them offered conclusive results; yet, two reasonable recommendations which were proposed are listed here:

Results showed that cryoblebbing is a better method to prepare recipient area for transplantation of MKCS compared to CO₂ laser. Yet, this difference is more noticeable in lesions located at the distal of fingers. All the lesions (n=10) at the mentioned locations which were prepared by cryoblebbing had > 90% repigmentation, while none of the CO₂ laser prepared lesions (n=24) showed such improvements (20).

Also, it was noticed that in patients suffering from vitiligo with stability of 3 to 6 months, a combination of NCECS and non-cultured dermal cell suspension is

likely to have satisfactory result. All patients underwent such method had more than 75% repigmentation (26).

Results of other trails, can offer valuable insights for designing new clinical trials for vitiligo using ATMPs.

In patients receiving NCECS, dermabrasion and using liquid nitrogen might be more efficient methods to prepare recipient sites comparing to dermaroller. Nearly half of the lesions underwent these two methods (dermabrasion and liquid nitrogen) had successful treatment (24).

In lesions located at hands, wrist and elbow, preparing NCECS might not be an optimal procedure. None of the patients had more than 50% repigmentation (22).

In patients with more than 12 months' stability, sole application of NCECS and in combination with non-cultured dermal cell suspension had 60% (6 out of 10 patients) and 70% (7 out of 10 patients) successful treatment rate respectively (26).

Since the mentioned studies used autologous cells from the patients in their intervention, they transplanted all the harvested cells from biopsy sites that didn't mention the number of cells.

The most common type of intervention applied was NCECS transplantation (Fig.2). The reason that NCECS is more desirable comparing to ORSHFS is the presence of keratinocyte-derived growth factors. Keratinocytes produce endothelin-1, stem cell factor, BFGF and nerve growth factor regulating melanogenesis (33).

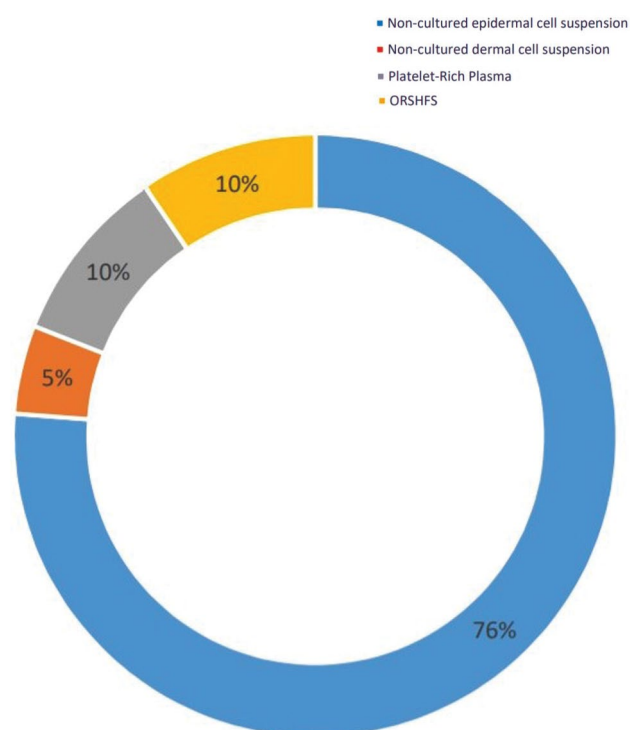


Fig.2: Types of interventions applied for treatment of vitiligo.

Moreover, in a study by Saleh et al. (34), co-administration of adipose derived stromal cells with melanocytes-derived from hair follicle was reported a safe and effective treatment modality for stable localized vitiligo in patients who were resistant to other methods of therapy.

Affordability and cost-effectiveness

The main issue in ATMPs is not cost-effectiveness, but affordability. This issue can be solved by three main approaches. First, is considering loans for patients from a third party (governments and banks). Second, the producer can arrange instalment payment programs. The last solution is termination of repayment process in case of non-successful treatment, side effects and mortality (35).

A national success for Iranian scientists

As we mentioned before, RecolorCell® is a recently IR-FDA approved cell-based product for vitiligo. The production line was GMP-certified at Cell Tech Pharmed Co., Tehran, Iran. The confirmatory clinical studies were conducted at Royan institute and published in international journals (30, 31).

Conclusion

NCECS is the main ATMP-based product for vitiligo treatment. Nearly half of the lesions treated with NCECS had successful treatment. Dermabrasion and liquid nitrogen are suitable methods before application of NCECS. Furthermore, combination of NCECS and non-cultured dermal cell suspension showed significant results. New ATMPs applying MSCs and MUSE cells propose a promising future in vitiligo treatment. Although ATMPs are cost-effective in general, the main issue is affordability which can be overcome by providing loans from third party and instalment payment arrangements from the producer.

Acknowledgements

There is no financial support and conflict of interest in this study.

Authors' Contributions

Sh.Gh., M.A.; Drafted the manuscript. Sh.K., A.B.; Reviewed and edited the manuscript. L.A.F., M.V.; Edited and confirmed the manuscript. All authors read and approved the final manuscript.

References

1. Zhang Y, Cai Y, Shi M, Jiang S, Cui S, Wu Y, et al. The prevalence of vitiligo: a meta-analysis. *PLoS One*. 2016; 11(9): e0163806.
2. Kubelis-López DE, Zapata-Salazar NA, Said-Fernández SL, Sánchez-Domínguez CN, Salinas-Santander MA, Martínez-Rodríguez HG, et al. Updates and new medical treatments for vitiligo (Review). *Exp Ther Med*. 2021; 22(2): 797.
3. Morrison B, Burden-Teh E, Batchelor JM, Mead E, Grindlay D, Ratib S. Quality of life in people with vitiligo: a systematic review and meta-analysis. *Br J Dermatol*. 2017; 177(6): e338-e339.
4. Van TN, Minh TT, Huu DL, Huu SN, Thanh TV, Huu ND, et al. Successful treatment of vitiligo vietnamese patients with Vitilinox®

- herbal bio-actives in combination with phototherapy. *Open Access Maced J Med Sci*. 2019; 7(2): 283-286.
5. Karagaiah P, Schwartz RA, Lotti T, Wollina U, Grabbe S, Goldust M. Biologic and targeted therapeutics in vitiligo. *J Cosmet Dermatol*. 2023; 22(1): 64-73.
6. Karagaiah P, Valle Y, Sigova J, Zerbinati N, Vojvodic P, Parsad D, et al. Emerging drugs for the treatment of vitiligo. *Expert Opin Emerg Drugs*. 2020; 25(1): 7-24.
7. Ramírez-Marín HA, Tosti A. Evaluating the therapeutic potential of ritlecitinib for the treatment of alopecia areata. *Drug Des Devel Ther*. 2022; 16: 363-374.
8. Kadry M, Tawfik A, Abdallah N, Badawi A, Shokeir H. Platelet-rich plasma versus combined fractional carbon dioxide laser with platelet-rich plasma in the treatment of vitiligo: a comparative study. *Clin Cosmet Investig Dermatol*. 2018; 11: 551-559.
9. Chen J, Yu N, Li H, Tang Y, Zhu H. Meta-analysis of the efficacy of adding platelet-rich plasma to 308-nm excimer laser for patients with vitiligo. *J Int Med Res*. 2022; 50(9): 3000605221119646.
10. Saberi S, Karamzadeh R, Moghadam P, Kadivari M, Eghbal-Behbahani B, Heydari Z, et al. Research performance in stem cell science and regenerative medicine in Iran: a national comprehensive observation. *Arch Iran Med*. 2019; 22(6): 318-327.
11. Chang HC, Hsu YP, Huang YC. The effectiveness of topical calcineurin inhibitors compared with topical corticosteroids in the treatment of vitiligo: a systematic review and meta-analysis. *J Am Acad Dermatol*. 2020; 82(1): 243-245.
12. Bae JM, Jung HM, Hong BY, Lee JH, Choi WJ, Lee JH, et al. Phototherapy for vitiligo: a systematic review and meta-analysis. *JAMA Dermatol*. 2017; 153(7): 666-674.
13. Hossein-Khannazer N, Torabi S, Hosseinzadeh R, Shahrokh S, Asadzadeh Aghdaei H, Memarnejadian A, et al. Novel cell-based therapies in inflammatory bowel diseases: the established concept, promising results. *Hum Cell*. 2021; 34(5): 1289-1300.
14. Lloyd-Williams H, Hughes DA. A systematic review of economic evaluations of advanced therapy medicinal products. *Br J Clin Pharmacol*. 2021; 87(6): 2428-2443.
15. Takaya K, Kato T, Ishii T, Sakai S, Okabe K, Aramaki-Hattori N, et al. Clinical analysis of cultured epidermal autograft (JACE) transplantation for giant congenital melanocytic nevus. *Plast Reconstr Surg Glob Open*. 2021; 9(1): e3380.
16. Matsumura H, Matsushima A, Ueyama M, Kumagai N. Application of the cultured epidermal autograft "JACE(®)" for treatment of severe burns: results of a 6-year multicenter surveillance in Japan. *Burns*. 2016; 42(4): 769-776.
17. Spritz RA, Santorico SA. The genetic basis of vitiligo. *J Invest Dermatol*. 2021; 141(2): 265-273.
18. Rashighi M, Harris JE. Vitiligo pathogenesis and emerging treatments. *Dermatol Clin*. 2017; 35(2): 257-265.
19. Seleit I, Bakry OA, Abdou AG, Dawoud NM. Immunohistochemical study of melanocyte-melanocyte stem cell lineage in vitiligo; a clue to interfollicular melanocyte stem cell reservoir. *Ultrastruct Pathol*. 2014; 38(3): 186-198.
20. El-Zawahry BM, Esmat S, Bassiouny D, Zaki NS, Sobhi R, Saleh MA, et al. Effect of procedural-related variables on melanocyte-keratinocyte suspension transplantation in nonsegmental stable vitiligo: a clinical and immunocytochemical study. *Dermatol Surg*. 2017; 43(2): 226-235.
21. Huggins RH, Henderson MD, Mulekar SV, Ozog DM, Kerr HA, Jabobsen G, et al. Melanocyte-keratinocyte transplantation procedure in the treatment of vitiligo: the experience of an academic medical center in the United States. *J Am Acad Dermatol*. 2012; 66(5): 785-793.
22. Bertolotti A, Leone G, Taïeb A, Soriano E, Pascal M, Maillard H, et al. Assessment of non-cultured autologous epidermal cell grafting resuspended in hyaluronic acid for repigmenting vitiligo and piebaldism lesions: a randomized clinical trial. *Acta Derm Venereol*. 2021; 101(7): adv00506.
23. Khodadadi L, Shafieyan S, Sotoudeh M, Dizaj AV, Shahverdi A, Aghdami N, et al. Intraepidermal injection of dissociated epidermal cell suspension improves vitiligo. *Arch Dermatol Res*. 2010; 302(8): 593-599.
24. Subburaj K, Thakur V, Kumaran MS, Vinay K, Srivastava N, Parsad D. A prospective, randomized clinical study to compare the efficacy of recipient site preparation using dermabrasion, cryoblisters, and dermaroller in autologous noncultured epidermal cell suspension in stable vitiligo. *Dermatol Ther*. 2021; 34(1): e14683.
25. Lommerts JE, Meesters AA, Komen L, Bekkenk MW, de Rie MA, Luiten RM, et al. Autologous cell suspension grafting in segmental

- vitiligo and piebaldism: a randomized controlled trial comparing full surface and fractional CO₂ laser recipient-site preparations. *Br J Dermatol.* 2017; 177(5): 1293-1298.
26. Thakur V, Kumar S, Kumaran MS, Kaushik H, Srivastava N, Parsad D. Efficacy of transplantation of combination of noncultured dermal and epidermal cell suspension vs epidermal cell suspension alone in vitiligo: a randomized clinical trial. *JAMA Dermatol.* 2019; 155(2): 204-210.
 27. Zhu L, Lin X, Zhi L, Fang Y, Lin K, Li K, et al. Mesenchymal stem cells promote human melanocytes proliferation and resistance to apoptosis through PTEN pathway in vitiligo. *Stem Cell Res Ther.* 2020; 11(1): 26.
 28. Chang WL, Lee WR, Kuo YC, Huang YH. Vitiligo: an autoimmune skin disease and its immunomodulatory therapeutic intervention. *Front Cell Dev Biol.* 2021; 9: 797026.
 29. Klar AS, Biedermann T, Michalak K, Michalczyk T, Meuli-Simmen C, Scherberich A, et al. Human adipose mesenchymal cells inhibit melanocyte differentiation and the pigmentation of human skin via increased expression of TGF- β 1. *J Invest Dermatol.* 2017; 137(12): 2560-2569.
 30. Paino F, Ricci G, De Rosa A, D'Aquino R, Laino L, Pirozzi G, et al. Ecto-mesenchymal stem cells from dental pulp are committed to differentiate into active melanocytes. *Eur Cell Mater.* 2010; 20: 295-305.
 31. Jones JC, Sabatini K, Liao X, Tran HT, Lynch CL, Morey RE, et al. Melanocytes derived from transgene-free human induced pluripotent stem cells. *J Invest Dermatol.* 2013; 133(8): 2104-2108.
 32. Mull AN, Zolekar A, Wang YC. Understanding melanocyte stem cells for disease modeling and regenerative medicine applications. *Int J Mol Sci.* 2015; 16(12): 30458-30469.
 33. Razmi TM, Afra TP, Parsad D. Vitiligo surgery: a journey from tissues via cells to the stems! *Exp Dermatol.* 2019; 28(6): 690-694.
 34. Saleh AA, Salam OHA, Metwally GH, Abdelsalam HA, Hassan MA, Sosa WS. Comparison treatment of vitiligo by co-culture of melanocytes derived from hair follicle with adipose-derived stem cells with and without NB-UVB. *Pigmentary Disorders.* 2017; 4(256): 1-8.
 35. Hampson G, Towse A, Pearson SD, Dreitlein WB, Henshall C. Gene therapy: evidence, value and affordability in the US health care system. *J Comp Eff Res.* 2018; 7(1): 15-28.
-