

Mandibular angle fracture following closed extraction of lower third molar: A case report and systematic review

Fatemeh Latifi^a, Mehrdad Dehghanpour Barouj^a, Mohammad Esmaeelinejad^b, Mahtab Kheirkhahi^c

^a Dept. of Oral & Maxillofacial Surgery, School of Dentistry, Shahid Beheshti University of Medical Sciences, Tehran, Iran.

^b Dept. of Oral & Maxillofacial Surgery, School of Dentistry, Semnan University of Medical Sciences, Semnan, Iran.

^c Dept. of Oral & Maxillofacial Radiology, School of Dentistry, Semnan University of Medical Sciences, Semnan, Iran.

Correspondence to Mehrdad Dehghanpour Barouj (email: mdmehrdad26@yahoo.com).

(Submitted: 3 July 2018 – Revised version received: 1 December 2018 – Accepted: 5 December 2018 – Published online: Summer 2018)

Objectives Mandibular third molar extraction is among the most commonly performed dental procedures. Fracture of the angle of mandible after third molar extraction is a rare complication of this procedure.

Case Herein, we report fracture of the right angle of mandible immediately after extraction of mandibular right third molar in a 38-year old healthy female patient, which was surgically managed. A review of the relevant literature is also presented. Thirty four cases of mandibular fracture following third molar extraction are reported in the literature. Most of these cases were removed surgically.

Conclusion Systematic review of papers showed that angulation of impacted third molar is one of the most related factors in following fractures of mandibular angle.

Keywords Third molar, Mandible, Mandibular fractures

Introduction

Mandibular third molar extraction is among the most commonly performed dental procedures^{1, 2}. Major peri-operative complications of this procedure include fracture of the adjacent tooth, trauma to the inferior alveolar nerve or lingual nerve, displacement of tooth into the sublingual or submandibular space and rarely mandibular fracture³. Pain, swelling, trismus, infection and delayed jaw fracture are among the most common postoperative complications³⁻⁵. Mandibular fracture occurs in case of applying excessive force or inadequate bone strength. Reduction in bone strength often occurs due to physiological factors such as osteoporosis and ridge atrophy or pathological factors such as presence of cysts and tumors in bone. Applying excessive force for tooth extraction or during the surgical procedure may result in mandibular fracture during or after surgery^{6, 7}. Immediate mandibular fracture following third molar extraction has been rarely reported^{8, 9}. Herein, we report a mandibular fracture case following third molar removal as it has been operated soon after the occurrence of the fracture.

Review of the literature

The PICO (population, intervention, comparison, and outcome) question was stated as follows: In patients with impacted third molar does different impaction types effect on the following mandibular fracture?

An electronic search was carried out in PubMed; Embase and Cochrane databases according to Preferred Reporting Items for Systematic review and Meta-Analysis Protocols (PRISMA-P) 2015 statement¹⁰ and after screening (Figure 1), nine relevant articles were chosen out of 144. The

searched keywords were “surgical extraction”, “extraction”, “lower third molar” and “mandibular fracture”.

The inclusion criteria were case reports on closed extraction or surgical extraction of mandibular third molars and fracture of mandible following tooth extraction.

The data extracted from the articles are categorized in Table 1 under titles of author(s), publication year, tooth number, method of extraction, type of fracture, and treatment/management.

Literature Review

Thirty four mandibular fracture cases following third molar extraction are reported in nine papers. All the cases were removed surgically. Most of them were in mesioangular position and fully impacted. All fractures happened either immediately or within 6 months. Most of the cases were treated by open reduction and internal fixation technique.

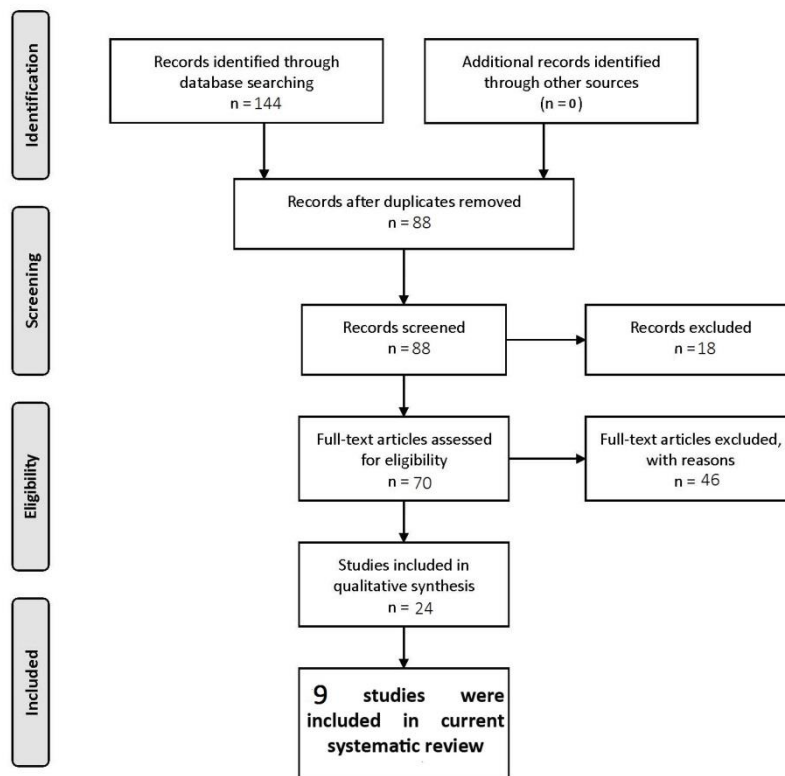
Materials and methods

Case

A 38 year-old female patient was referred to the Oral and Maxillofacial Surgery Department of Shahid Beheshti University of Medical Sciences, Tehran, Iran by her general dentist due to fracture of the angle of mandible noticed after extraction of her mandibular right third molar. On extra-oral clinical examination, a step was palpated in the right inferior border of the mandible. The patient complained of hypoesthesia in the path of the inferior alveolar nerve at the right side. Intraoral clinical examination revealed that the patient’s occlusion was off and she had right posterior open bite. Empty socket of right mandibular third molar was evident.

Table 1- Categorized papers reported the mandibular fracture following third molar extraction

References	Number of patients	Patients age	Patients gender	Type of impaction	Type of fracture	Time of fracture	Procedure
Krimmel et al. (2000) ²⁰	6	45	5 M and one F	Fully impacted	Without displacement	Within two weeks	ORIF
Wagner et al. (2005) ¹⁸	17	49	One female patient and the others were male	All types of pell and Gregory classification	Displacement in 5 cases	Intraoperative or Within a month	ORIF in 6 cases, CR in 8 cases and no treatment in 3 cases
Woldenberg et al. (2007) ⁹	1	37	Female	Vertical fully impacted	Without displacement	At the time of surgery	CR
Kao et al. (2010) ¹¹	1	54	Male	Mesioangular fully impacted	Without displacement	After 6 weeks	Open reduction without fixation
Cankaya et al. (2011) ⁸	2	33 and 35 year old	Male and female	Mesioangular/ one deeply impacted and one of them partially impacted	Without displacement	At the time of surgery	CR and the other no treatment
O'zcakir-Tomruk and Arslan (2012) ²¹	2	32 and 34 year old patients	Both female	Partially erupted	With displacement	During surgery	ORIF
Cutilli et al. (2013) ¹⁷	3	32	male	Two mesioangular and one vertical case	Without displacement	After surgery and within three weeks	ORIF
Xu et al. (2014) ²²	1	20	Female	Mesioangular fully impacted	Without displacement	At the time of surgery	ORIF
Correa et al. (2014) ²³	1	52	Male	Distoangular and fully impacted	With displacement	After 15 days	ORIF

**Figure 1-** Flowchart diagram of included articles.

Patient's medical history was unremarkable and she had no systemic condition. After clinical examination, a panoramic

radiograph was obtained (Figure 2), which revealed fracture of the right angle of the mandible and empty socket of

mandibular right third molar tooth.

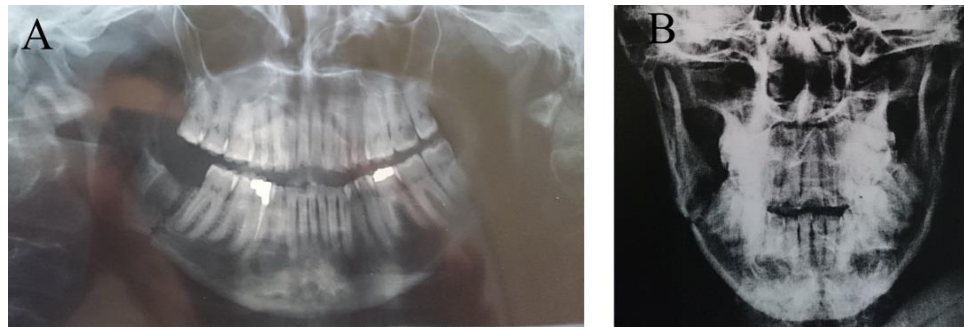


Figure 2- Radiographic images of the patient's mandible immediately after tooth extraction. A- Panoramic view. B- Poster anterior (PA) view of the mandible.

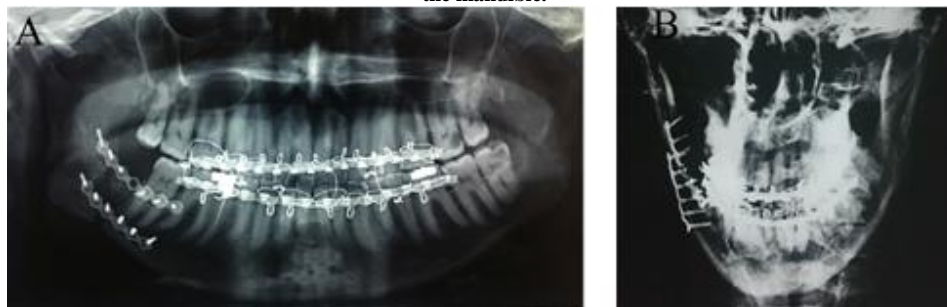

Figure 3- Radiographic images of the patient's mandible after open reduction and internal fixation. A- Panoramic view. B- Poster anterior (PA) view of the mandible

The patient underwent fixation surgical procedure and the broken pieces were fixed with two mini-plates, the superior one in monocortical manner to prevent the teeth roots damage and the inferior one was applied bicortically¹¹ (Figure 3). The patient was discharged from the hospital two days after surgery. Elastic guides were used at both sides to limit jaw movements during the six-week follow up period. After six weeks, the patient had normal occlusion and could open her mouth by 45 mm. The arch bar was then removed since the patient gained full recovery.

Discussion

Fracture of the angle of mandible following third molar extraction is extremely rare. Fracture may occur during surgery, which is referred to as immediate fracture, or may occur within four weeks after completion of surgical procedure^{7, 12, 13}, which is classified as late/delayed fracture. Determining the prevalence rate of mandibular fracture following mandibular third molar extraction is difficult. Mandibular fracture following third molar extraction is multifactorial and depends on patient's age, sex, level of impaction of tooth, ratio of space occupied by the impacted tooth in the jaw, presence of bone defects, cysts and tumors, having a hard diet after surgery and technique of surgery^{6, 8}. The mandible becomes weak by aging due to the reduction in elasticity of bone. The majority of mandibular fractures following mandibular third molar extraction have been reported in patients over 40 years of age. Moreover, ankylosis of third molars in the elderly further complicates their extraction and necessitates osteotomy in most patients

^{14, 15, 16}. Thus, sectioning of the tooth into smaller pieces is highly recommended in the elderly in order to prevent excessive bone removal.

The role of gender in mandibular fracture is related to the bite force. The frequency of mandibular fracture is higher in males due to having a stronger bite force than females⁶. Level of impaction of tooth is another important factor in this respect. The higher the level of impaction (the deeper the tooth), the greater the amount of removed bone and the greater the magnitude of jaw weakening.

The space occupied by the impacted tooth in the jaw is another important factor in this respect. The ratio of occupied space to the entire jaw can be assessed via buccal and lingual image reconstruction by computed tomography (CT) scan. If this ratio is >50%, the patient would be classified as having a high risk of mandibular fracture following extraction. In such cases, special care must be taken during and after surgery^{17, 18}. Bone defects, odontogenic cysts and tumors and periodontal disease can all weaken the jawbone; all these conditions are more common in patients older than 40 years^{3, 6}.

Mandibular fracture during surgical procedures occurs due to inappropriate use of instruments or applying excessive force, mainly by young, inexperienced dentists. Postoperative mandibular fracture often occurs due to excessive bite force. It is often reported by patients as crepitation and is not radiographically detectable in early phases^{19, 20, 21}.

The incidence of mandibular fracture in the right and left sides has not been commonly reported. Wagner et al. reported that 70% of the cases of mandibular fractures

occurred in the left side; the reason was explained to be the easier application of instruments, applying a more controlled force and better accessibility in the right side of patients^{22, 23}.

The presented patient was a 38 year-old female with a fully erupted mandibular right third molar. She was systemically healthy and had no jaw pathology. To the best of authors' knowledge, there is no reported case of fracture of the angle of mandible following closed extraction of third molar in a healthy patient in the literature. The only reported case of fracture following closed extraction of third molar occurred in a 31 year-old male with osteogenesis imperfecta, who was under treatment with alendronate¹⁹. Thus, the current report is the only one reporting immediate fracture of the angle of mandible following closed extraction of third molar in a healthy patient.

Conclusion

Systematic review of papers showed that angulation of impacted third molar is one of the most related factors in following fractures of mandibular angle.

Acknowledgements:

We would like to express our gratitude and appreciation to Dr Mojdeh Kalantar Motamedi for editing the manuscript.

Conflict of Interests

None Declared ■

References

- Haug RH, Perrott DH, Gonzalez ML, Talwar RM. The american association of oral and maxillofacial surgeons age-related third molar study. *J Oral Maxillofac Surg.* 2005 Aug; 63(8):1106-14.
- Msagati F, Simon EN, Owibingire S. Pattern of occurrence and treatment of impacted teeth at the Muhimbili National Hospital, Dar es Salaam, Tanzania. *BMC Oral Health.* 2013 Aug;13:37.
- Bouloux GF, Steed MB, Perciaccante VJ. Complications of third molar surgery. *Oral Maxillofac Surg Clin North Am.* 2007 Feb;19(1):117-28.
- Blondeau F, Daniel NG. Extraction of impacted mandibular third molars: postoperative complications and their risk factors. *J Can Dent Assoc.* 2007 May;73(4):325.
- Janakiraman EN, Alexander M, Sanjay P. Prospective analysis of frequency and contributing factors of nerve injuries following third-molar surgery. *J Craniofac Surg.* 2010 May;21(3):784-6.
- Chrcanovic BR, Custodio AL. Considerations of mandibular angle fractures during and after surgery for removal of third molars: a review of the literature. *Oral Maxillofac Surg.* 2010 Jun;14(2):71-80.
- Libersa P, Roze D, Cachart T, Libersa JC. Immediate and late mandibular fractures after third molar removal. *J Oral Maxillofac Surg.* 2002 Feb;60(2):163-5.
- Cankaya AB, Erdem MA, Cakarar S, Cifter M, Oral CK. Iatrogenic mandibular fracture associated with third molar removal. *Int J Med Sci.* 2011;8(7):547-53.
- Woldenberg Y, Gatot I, Bodner L. Iatrogenic mandibular fracture associated with third molar removal. Can it be prevented? *Med Oral Patol Oral Cir Bucal.* 2007 Jan;12(1):E70-2.
- Moher D, Shamseer L, Clarke M, Ghersi D, Liberati A, Petticrew M, et al. Preferred reporting items for systematic review and meta-analysis protocols (PRISMA-P) 2015 statement. *Syst Rev.* 2015 Jan 1;4:1.
- Haug RH1, Barber JE, Reifeis R. A comparison of mandibular angle fracture plating techniques. *Oral Surg Oral Med Oral Pathol Oral Radiol Endod.* 1996 Sep;82(3):257-63..
- Al-Belasy FA, Tozoglu S, Ertas U. Mastication and late mandibular fracture after surgery of impacted third molars associated with no gross pathology. *J Oral Maxillofac Surg.* 2009 Apr;67(4):856-61.
- Kao YH, Huang IY, Chen CM, Wu CW, Hsu KJ, Chen CM. Late mandibular fracture after lower third molar extraction in a patient with Stafne bone cavity: a case report. *J Oral Maxillofac Surg.* 2010 Jul;68(7):1698-700.
- Alessandri Bonetti G, Pelliccioni GA, Checchi L. Management of bilaterally impacted mandibular second and third molars. *J Am Dent Assoc.* 1999 Aug;130(8):1190-4.
- Franklin CD. Ankylosis of an unerupted third molar by inostosis of enamel. A case report. *Br Dent J.* 1972 Oct;133(8):346-7.
- Murakami K, Yamamoto K, Tsuyuki M, Sugiura T, Tsutsumi S, Kirita T. Theoretical efficacy of preventive measures for pathologic fracture after surgical removal of mandibular lesions based on a three-dimensional finite element analysis. *J Oral Maxillofac Surg.* 2014 Apr;72(4):833.e1-18.
- Cutilli T, Bourelaki T, Scarsella S, Fabio DD, Pontecorvi E, Cargini P, et al. Pathological (late) fractures of the mandibular angle after lower third molar removal: a case series. *J Med Case Rep.* 2013 Apr 30;7:121.
- Wagner KW, Schoen R, Wongchuensoontorn C, Schmelzeisen R. Complicated late mandibular fracture following third molar removal. *Quintessence Int.* 2007 Jan;38(1):63-5.
- Gallego L, Junquera L, Pelaz A, Costilla S. Pathological mandibular fracture after simple molar extraction in a patient with osteogenesis imperfecta treated with alendronate. *Med Oral Patol Oral Cir Bucal.* 2010 Nov 1;15(6):e895-7.
- Krimmel M, Reinert S. Mandibular fracture after third molar removal. *J Oral Maxillofac Surg.* 2000 Oct;58(10):1110-2.
- Özçakir-Tomruk C, Arslan A. Mandibular angle fractures during third molar removal: a report of two cases. *Aust Dent J.* 2012 Jun;57(2):231-5
- Xu JJ, Teng L, Jin XL, Lu JJ, Zhang C. Iatrogenic mandibular fracture associated with third molar removal after mandibular angle osteotomy. *J Craniofac Surg.* 2014 May;25(3):e263-5.
- Correa AP, Faverani LP, Ramalho-Ferreira G, Ferreira S, Avila Souza F, de Oliveira Puttini I, et al. Unerupted lower third molar extractions and their risks for mandibular fracture. *J Craniofac Surg.* 2014 May;25(3):e228-9.

How to cite:

Fatemeh Latifi, Mehrdad Dehghanpour barouj, Mohammad Esmaeelinejad, Mahtab Kheirkhahi. Mandibular angle fracture following closed extraction of lower third molar: A case report and systematic review. *J Dent Sch* 2018;36(3):104-107