

Epithelioid Type of Paratesticular Leiomyosarcoma: A Case Report and Literature Review

MOHAMMADI TORBATI P^{1*}, ZHAM H²

¹*Department of Pathology, Shaheed Labbafinejad Medical Center, Shaheed Beheshti University of Medical Sciences, Tehran, Iran*

²*Department of Pathology, Mahdiah Medical Center, Shaheed Beheshti University of Medical Sciences, Tehran, Iran*

KEY WORDS: leiomyosarcoma, scrotal mass, testicular tunica

Introduction

Paratesticular leiomyosarcoma is a rare neoplasia, which has been reported in less than 100 cases so far. According to its prevalence, this neoplasia is originated from testicular tunica (48%), spermatic cord (48%), epididymis (2%) and dartos muscle, as well as subcutaneous tissue of scrotum (2%).^(1,2,3) This lesion is seen in all age groups. However, it is mostly diagnosed in the 6th decade and more than 80% of patients are over 40 years old.⁽⁴⁾ Leiomyosarcoma is the result of neoplastic transformation of smooth muscle cells or multipotential mesenchymal cells in various sites of the body.^(1,5) The behavior of these lesions depends on the site of origination, but little is known for grading of such tumors in paratesticular region.^(4,6) Like other mesenchymal tumors of this region, leiomyosarcoma is manifested as a painless mass without hydrocele and the disease may be symptomatic in less than one year. Size of tumor is usually between 2 and 9 cm with a mean of 5 cm. Almost all cases are primary lesions rather than the extension of a retroperitoneal lesion.⁽²⁾

Case Report

An 18-year-old male was referred with a painless, firm, and gradually growing right scrotal mass. The history, physical examination, and ultrasonographic findings, which indicated a solid oval mass were compatible with testicular tumor, thus, radical orchidectomy was performed.

Accepted for publication in August 2003

**Corresponding author: Department of Pathology, Shaheed Labbafinejad Medical Center, Boustan 9, Pasdaran, Tehran, Iran. Postal code: 16666. Tel: +98 21 2549010-16, Fax: +98 21 2549039.*



FIG. 1. Gross appearance of the tumor

Macroscopically, a firm solid homogeneous gray-white mass with a dimension of 52 × 39 mm involving a relatively large area of tunica albuginea was observed. However, no sign of testis involvement was seen. The mass had a clear demarcation without degenerative changes (fig. 1).

Spindle cells with delicate eosinophilic cytoplasm within crossed or vertically decorated bands were noted in microscopic study. Furthermore, a considerable part of lesion with a different microscopic feature consisted of irregular tubules, cellular masses, and trabeculae made by a range of cubic to flat epithelioid cells were seen as well as different amounts of eosinophilic cytoplasm, some of which were vacuolized (fig. 2). The above-mentioned findings suggested three differential diagnoses: adenomatoid tumor, epithelioid leiomyosarcoma, and malignant mesothelioma.

Immunohistochemical stain was used to differentiate the lesions from each other and the results were as follows:

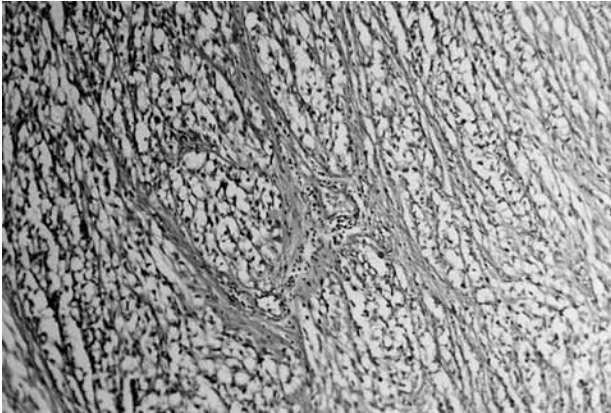


FIG. 2. Epithelioid cells arranged in solid sheets

1. Negative reaction with calretinin marker, thrombomodulin, and cytokeratin cocktail;
2. Strong positive reaction with vimentin, smooth muscle actin, muscle specific actin, and desmin (fig. 3).

The findings were compatible with the diagnosis of leiomyosarcoma. Following the final diagnosis, abdominal and chest CT scan were performed to rule out any other neoplastic origin.

Discussion

The low prevalence of this disease has limited the evaluation of its clinical course and the adaptation of a therapeutic regimen with high confidence.⁽⁷⁾ However, there are two basic points which should be concerned; firstly, considering all differential diagnoses of spindle cell paratesticular tumors and to assure leiomyosarcoma diagnosis, and secondly, grading of leiomyosarcoma.

Differential diagnoses are as follows.⁽⁶⁾

- 1- Subcutaneous scrotal leiomyoma: this tumor could have polymorphic nucleus, but two mitoses in every HPF indicates sarcomatous change.⁽⁸⁾
- 2- Malignant mesothelioma: it is usually manifested with the development of progressive hydrocele, and contrary to leiomyosarcoma, it has an infiltrative margin. Sarcomatoid mesothelioma has an extremely collagenized background. Differentiation is made by immunohistochemical staining.^(9,10)
- 3- Fibrosing inflammatory pseudotumors: They are always associated with a significant inflammation. When inflammation severity is more than usual in leiomyosarcoma or inflammatory pseudomotor positively reacts with desmin, diagnosis would be difficult. Cases of fibroblastic proliferation of pseudosarcoma such as nodular fasciitis are reported in this

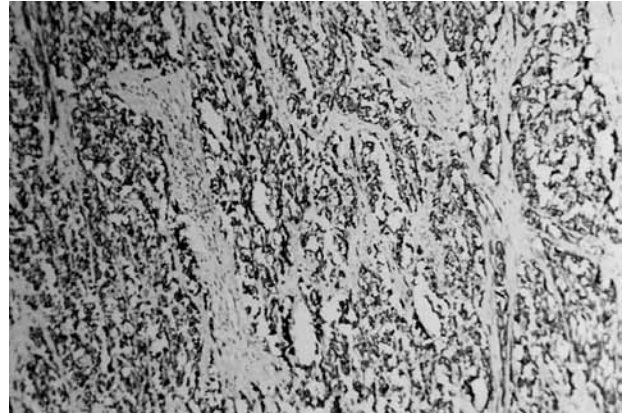


FIG. 3. Immunoreactivity with desmin, clone: D33

- region. These tumors have mitosis but their nuclei are pale, regular, and spindle shape.⁽¹¹⁾
- 4- Deep invasive fibromatosis: it has an infiltrative growth and it is completely firm. This lesion consists of wavy myofibroblastic or fibroblastic bands within an extremely collagenized background. Immunohistochemical staining and electronic microscopy are used for differentiation.⁽¹²⁾

The grading of paratesticular leiomyosarcoma is based on the evaluation of the number of mitoses (the mean number of mitoses in 5 HPF in a part of tumor with the highest mitosis rate and cellularity), the percentage of necrosis and the severity of nuclear pleomorphism. These are important in predicting biologic behavior:

Grade 1: Tumors with no necrosis, less than 6 mitoses in 10 HPF, and mild disseminated pleomorphism.

Grade 2: Tumors with focal necrosis (<15%), more than 6 mitoses in 10 HPF, or obvious nuclear pleomorphism.

Grade 3: Tumors with vast necrosis (>15%), regardless of the number of mitoses or the severity of pleomorphism.

Significant regions with epithelioid change, like what has been seen in this case, was only reported in 4% of cases.^(13,14)

The considerable increase in the number of mitoses in this region which is associated with serious biologic behaviour, is a remarkable point.

In brief, attention to the following points is recommended:

1. Since the lesions are mostly low grade and have better biologic behavior, grading of paratesticular leiomyosarcoma would be of great importance. Grade 3 lesions are extremely invasive.^(7,15)
2. The results of long-term follow-up of patients

indicate that the use of radiotherapy following radical orchidectomy decreases local recurrence and distant metastasis, particularly in grade 3 lesions.⁽¹⁵⁾

3. Since the tendency to hematogenic metastasis is high, the effect of retroperitoneal lymphadenectomy is unclear and generally not suggested.⁽¹⁶⁾
4. Immunohistochemical staining of more than 40% of nuclei with Ki-67 marker indicates poor prognosis; therefore, this staining is suggested to be added to other criteria for tumor grading.
5. It seems that chemotherapy has only a palliative role.⁽¹⁷⁾

References

1. Banik S, Guha PK. Paratesticular leiomyosarcoma: a clinicopathologic review. *J Urol* 1995; 121: 823-6.
2. Tolley DA, Buckley PM. Leiomyosarcoma of the spermatic cord. *Br J Urol* 1981; 53: 193.
3. Davides KC, King LM. Primary leiomyosarcoma of the epididymis. *B J Urol* 1985; 114: 642-4.
4. Donovan MG, Fitzpatrick JM. Paratesticular leiomyosarcoma. *Br J Urol* 1987; 60: 590.
5. Bianchi G, Tallarigo C, Lotto A. About Two cases of leiomyosarcoma of the spermatic cord. *Acta Urol Brit* 1994; 52: 483-6.
6. Folpe A, Weiss S. Paratesticular soft tissue neoplasms. *Semin Diagn Pathol* 2000; 17: 307-18.
7. Soosay GN, Parkinson MC, Paradinas J, et al. Paratesticular sarcoma revisited: a review of cases in the British Testicular Tumor Panel and Registry. *Br J Urol* 1996; 77: 143-6.
8. Slone S, Connor D. Scrotal leiomyomas with bizarre nuclei. *Mod pathol* 1998; 11: 282-7.
9. Hurlimann J. Desmin and neural marker expression in mesothelial cells and mesotheliomas. *Hum Pathol* 1994; 25: 753-7.
10. Miettinen M. Immunoreactivity for cytokeratin and epithelial membrane antigen in leiomyosarcoma. *Arch Pathol Lab Med* 1998; 112: 637-40.
11. Jones A, Yong RH. Benign fibromatous Tumors of the paratesticular region. *Am J Surg Pathol* 1997; 21: 296-305.
12. Lai FM, Allen PW. Aggressive fibromatosis of the spermatic cord. *Am J Clin Pathol* 1995; 104: 403-7.
13. Pianan S, Roncaroli F. Epithelioid leiomyosarcoma of retroperitoneum with granular cell change. *Histopathology* 1994; 25: 90-3.
14. Salm R, Evans DJ. Myxoid leiomyosarcoma. *Histopathology* 1985; 9: 159-69.
15. Wile AG, Evans HL. Leiomyosarcoma of soft tissue: a clinicopathologic study. *Cancer* 1991; 48: 1022-32.
16. Weitzner S. Leiomyosarcoma of spermatic cord and retroperitoneal lymph node dissection. *Am Surg* 1993; 39: 352-4.
17. Fisher C, Goldman J, Epstein J. Leiomyosarcoma of the paratesticular region. *Am J Surg Pathol* 2001; 25: 1143-49.