

Renal Malakoplakia Simulating Neoplasm in a Child: Successful Medical Management

KAJBAFZADEH AM*, BAHARNOORI M

*Department of Pediatric Urology and Renal Transplantation, Children Medical Center, Tehran
University of Medical Sciences, Tehran, Iran*

KEY WORDS: renal malakoplakia, Wilm's, bethanechol chloride, macrophage, diagnosis

Introduction

Renal malakoplakia (RM) is a rare granulomatous disorder of adults, with less than 8 cases reported in pediatric age group in the literature. Published cases of RM were collected from the archival literature by searching the MEDLINE database and by reviewing bibliographic references contained in articles on renal malakoplakia. Ninety-six cases of RM have been published over the past 37 years.

Renal malakoplakia presents with fever, flank pain, and a palpable mass, which may be confused with a renal tumor or other infectious processes. The clinical diagnosis of renal malakoplakia is difficult and usually only proved by pathologic findings of Michaelis-Gutmann bodies after nephrectomy. We report a child with renal parenchymal malakoplakia presenting with a renal neoplasm and successfully treated medically with no recurrence in a five year follow-up period.

Case Report

A 10-year-old boy suffering from fever and headache for 20 days before admission in the pediatric infectious disease ward had been evaluated as a fever of unknown origin (FUO) at a local hospital. He was initially diagnosed as Salmonellosis. Antibiotic regimen was not effective (a 7 day course of chloramphenicol). The patient was transferred to our urology department with the initial diagnosis of huge renal mass, most probably a Wilm's tumor. On physical examination the child was severely ill, with day and night fever, tachycardia, and right flank tenderness. A huge soft tissue mass was noted on

the right upper quadrant, fixed to the surrounding muscles. His erythrocyte sedimentation rate (ESR) was 110 mm/h in the first hour (normal 5 to 10 mm/h). All admission laboratory data were normal except for mild anemia and moderate leukocytosis. Renal ultrasound showed a right kidney huge solid mass with some cystic formation with mixed echo pattern. Abdominal CT scan confirmed the right renal solid mass measuring 111 × 69 × 61 mm with some necrosis and cyst formation (fig. 1). On physical examination, the child was cachectic with a large right flank mass. Renal cortical scan by 99m Tc dimercaptosuccinic acid (DMSA) showed normal left kidney with a large photopenic area at the right lateral renal border (fig. 2). A true cut needle biopsy failed and an open biopsy was taken from the right flank mass. The histopathological reports showed severe inflammation with infiltration of foamy histiocytes, compatible with malakoplakia (fig. 3). Following confirmation of initial diagnosis, a trial treatment with bethanechol chloride, 12.5 mg three times daily, trimethoprim-sulfamethoxazole, one adult tablet per 12 hours, and ascorbic acid, 500 mg three times daily for 21 days, was initiated. He was afebrile three days after starting the new regimen. The general condition, as well as his appetite, improved. A repeat renal ultrasound and a CT scan confirmed dramatic renal mass shrinkage and decrease in the size and appearance of the mass (fig. 4) three weeks following the treatment. Subsequently, the patient was followed for 46 months and renal ultrasound showed normal renal size with no detectable tumor.

Discussion

The most common presenting signs and symptoms of renal malakoplakia are fever, flank pain, or a palpable flank mass. Two basic patterns of

Accepted for publication in April 2004

**Corresponding author: 2nd Floor, No. 36, 7th*

Street, Saadat-Abad, Tehran 19987, Iran.

email: kajbafzd@sina.tums.ac.ir

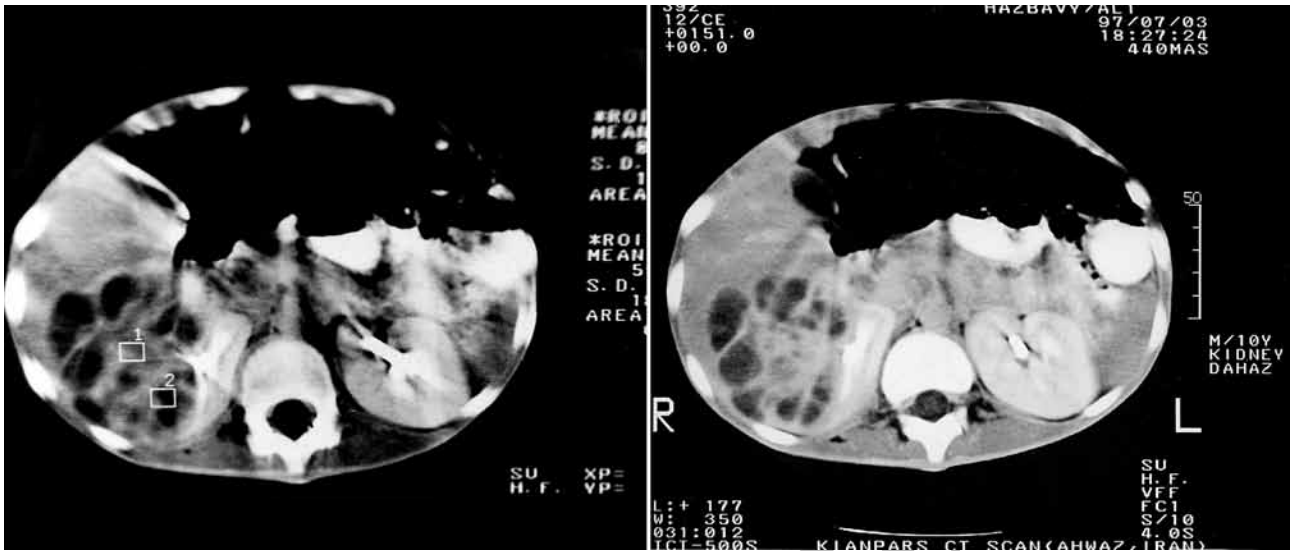


FIG. 1. Abdominal CT Scan before medical management showed right renal solid mass with some necrosis and cyst formation.

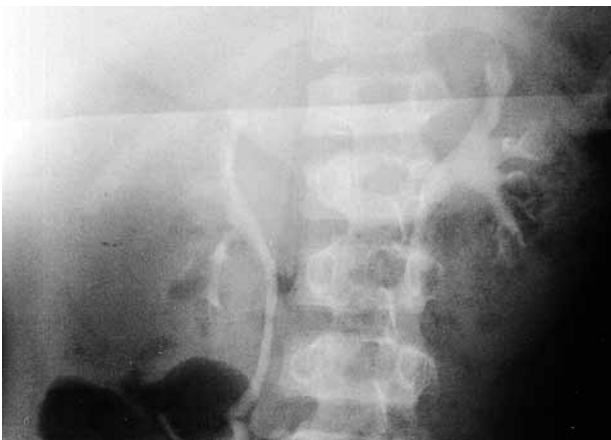

FIG. 2. Intravenous urogram showed a soft tissue mass on the lateral border of right kidney causing caliceal elongation and distortion.

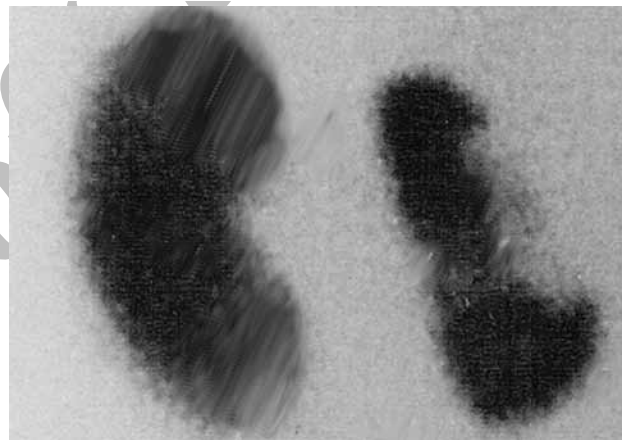


FIG. 3. The Renal cortical scan by Tc-99m DMSA showed normal left kidney with a photopenic area at the right lateral renal border.

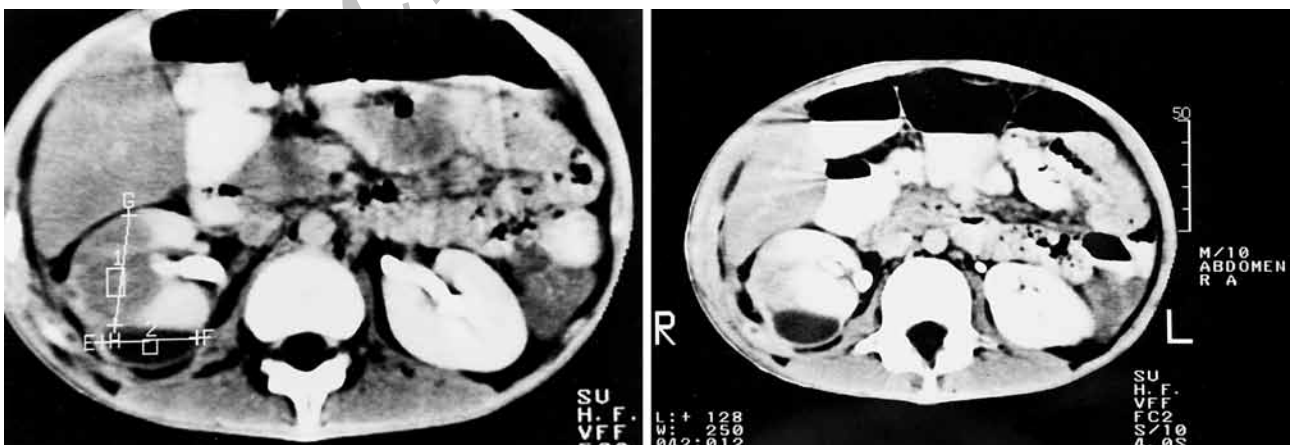


FIG. 4. CT scan three weeks following medical management noted dramatic mass shrinkage.

malakoplakia have been described: multifocal and unifocal.^(1,2) Multifocal type accounts for 75% of the reported cases and is bilateral in about half of the cases. Unifocal disease usually appears as a large yellow-gray mass measuring 2.5 cm to 9

cm in diameter.⁽¹⁾ The mass is usually smooth and well margined and central necrosis or cyst formation may be present. Histological examination reveals aggregates of large histiocytic cells (Von Hanseman cells) admixed with an infiltrate

of lymphocytes, plasma cells, and interspersed well-defined bundles of fibroblasts and collagen. Von Hansemann histiocytes contain Michaelis-Gutmann bodies, concentrically laminate and calcific inclusions pathognomonic of malakoplakia.

Patients with solitary kidney or bilateral upper tract involvement may present with azotemia or uremia. Dramatic improvement has also been reported in patients treated with cholinergic agents and ascorbic acid.⁽²⁾ Both agents have corrected cellular abnormalities as well as enhancing phagocytosis by improving microtubule and vacuole formation. Cholinergic actions may also include improving bactericidal function through enhancing super oxide production and release. It is known that the cholinergic agonists raise intra-

cellular cyclic guanine monophosphate (cGMP)/cyclic adenosine monophosphate (cAMP) ratio and stimulate the production of tumor necrosis factor that enhances the microbiocidal function of macrophages.⁽³⁾

References

1. Hartman DS, Davis CJ Jr, Lichtenstein JE, Goldman SM. Renal parenchymal malakoplakia. *Radiology* 1980; 136: 33-42.
2. Abdou NI, NaPombejara C, Sagawa A, et al. Malakoplakia: evidence for monocyte lysosomal abnormality correctable by cholinergic agonist in vitro and in vivo. *N Engl J Med* 1977; 297: 1413-19.
3. Kajbafzadeh AM. Malakoplakia of the testis [correspondence]. *Br J Urol* 1995; 76: 276.

Archive of SID