

Case Reports

Malignant Mesothelioma of the Spermatic Cord: Case Report and Review of the Literature

Peyman Mohammadi Torbati,^{1*} Mahmoud Parvin,¹ Seyyed Amirmohsen Ziaee²

¹*Department of Pathology, Shaheed Labbafinejad Medical Center, Shaheed Beheshti University of Medical Sciences, Tehran, Iran*

²*Department of Urology, Shaheed Labbafinejad Medical Center, Shaheed Beheshti University of Medical Sciences, Tehran, Iran*

KEY WORDS: paratesticular tumors, malignant mesothelioma, spermatic cord

Introduction

Paratesticular malignant mesothelioma is a rare tumor, previously reported in only 76 cases. Most of these lesions originate from the tunica vaginalis, and few cases arise from the epididymis or spermatic cord. Middle-aged men are most often affected, although an age range of 7 of 84 years has been reported in patients with paratesticular malignant mesothelioma.⁽¹⁾ As in benign mesothelial lesions, malignant mesothelioma almost always manifests with hydrocele,^(4,5) fluid collection of which occurs faster, leading to symptomatic disease in less than 1 year. In 41% of cases, a history of contact with asbestos has been documented.^(2,3) We report a case of malignant mesothelioma of the spermatic cord in a 52-year-old man.

Case Report

A 52-year-old man presented at our institution in July 2002 with right scrotal enlargement. He had no history of granulomatous diseases such as tuberculosis or sarcoidosis. His symptoms were limited to enlargement of scrotum and a sensation of heaviness. Changes in sexual function, hematuria, and hemospermia were not present. No unusual mass was detected on

physical examination and ultrasonography. Accordingly, he underwent right battle neck hydrocelectomy under spinal anesthesia. Since there was no apparent macroscopic lesion, histopathological examination was not performed.

One year later, the patient returned with recurrent hydrocele of the same side, and ultrasonography revealed 2 multicystic lesions in the right side of the scrotum (Figure 1). Hydrocelectomy was repeated, and 2 cysts with multiple cavities (1 that had adhered to the spermatic cord and another that had adhered to the epididymis) were excised. Macroscopic features of the 2 cysts were similar. The external surface of the cysts' walls was cream-grey, and the internal surface of both had papulonodular vegetation. Both cysts contained yellow, turbid, condensed discharge and had multiple cavities. The cyst that had adhered to the spermatic cord measured 73 × 63 mm, and the one that had adhered to the epididymis was 35 × 24 mm.

Microscopic evaluation of the cysts demonstrated neoplastic malignancies with a papulonodular growth pattern. There were foci of invasion to the underlying desmoplastic stroma. The tumoral cells were cube-shaped epithelioid, containing various amounts of eosinophilic cytoplasm, vesicular nuclei, and prominent nucleoli with a moderate mitotic activity of 3 mitoses per 10 HPF in atypical shapes (Figure 2).

Based on the aforementioned, the differential diagnoses were primary papillary adenocarcinoma, epithelioid malignant mesothelioma,

Received February 2004

Accepted June 2005

**Corresponding author: department of pathology, Shaheed Labbafinejad hospital, 9th Boustan, Pasdaran St., Tehran 1666679951, Iran.*

Tel: ++98 21 2254 9010, Fax: ++98 21 2254 9039

E-mail: p2000torbati@yahoo.com

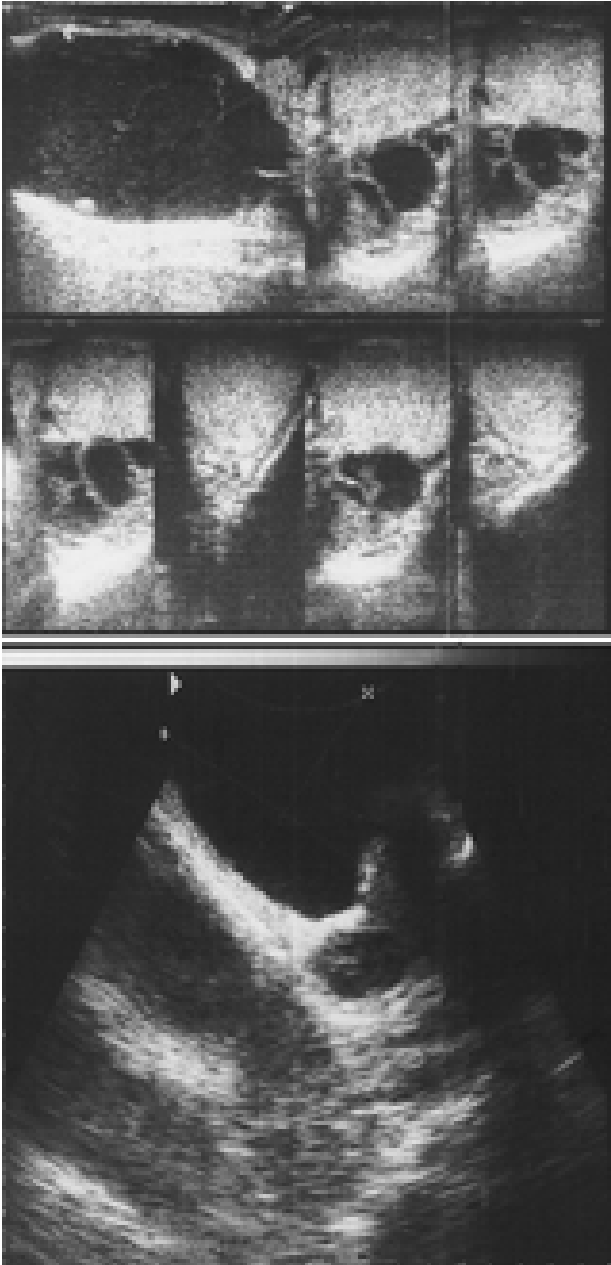


FIG. 1. Two multicystic lesions in the right scrotum on sonography

and metastatic papillary adenocarcinoma of unknown origin. To make a definite diagnosis, histochemical and immunohistochemical methods were used, and the following results were found: negative reaction for periodic acid-Schiff and mucicarmine; strong positive reaction for calretinin, thrombomodulin, and cytokeratin 5/6 markers (Figure 2); diffused positive immunostaining for epithelial membrane antigen and CA-125 makers; and negative for Leu-M1, carcinoembryonic antigen, B72.3, plasma alkaline phosphatase, human chorionic gonadotrophin, and alpha-fetoprotein. Considering the above, especially positive calretinin and thrombomodulin, malignant mesothelioma of the

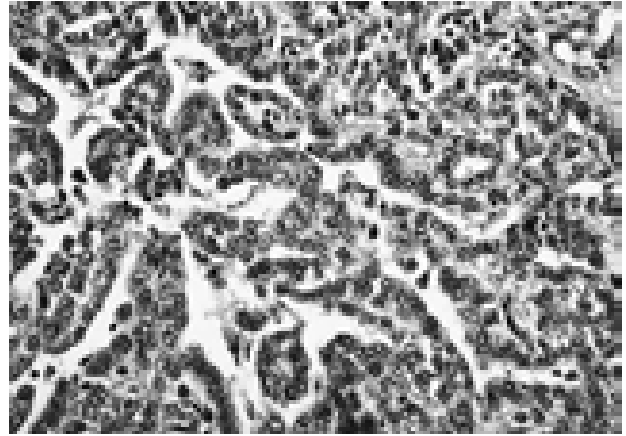


FIG. 2. Tubulopapillary feature in malignant mesothelioma (Hematoxylin-Eosin, $\times 400$)

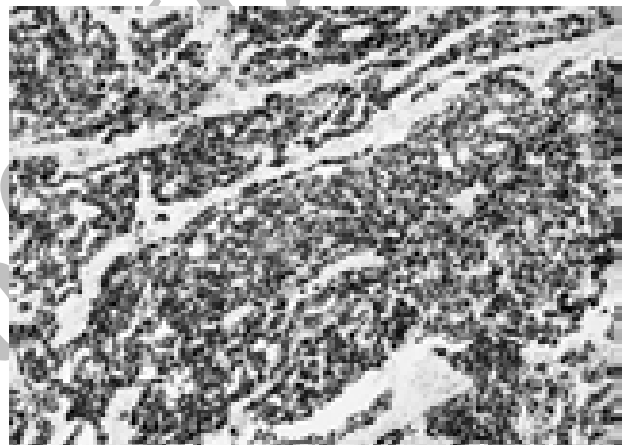


FIG. 3. Positive immunoreaction for calretinin ($\times 400$)

spermatic cord and epididymis was confirmed. Abdominal and thoracic computed tomography (CT) scans and an isotope scan of the thyroid gland and bones were done to rule out any other neoplastic foci. Distant metastases were not present.

Radical orchidectomy was done, and 9 months later, in April 2003, tumor resection was performed owing to local recurrence. In the summer of 2004, metastases to the inguinal lymph nodes were resected, and eventually, in January 2005, metastases to the ileac lymph nodes were diagnosed. The patient refused further treatment and has survived to date, without tumor resection, chemotherapy, or radiotherapy.

Discussion

Malignant mesothelioma is an uncommon neoplastic lesion, seen in middle-aged and elderly persons. Paratesticular mesothelioma is believed to originate from a serosal cavity that covers the anterior and lateral sides of the testis and

epididymis. It has been suggested that an oncogene may have a role in the pathogenesis of this tumor, and a history of contact with asbestos also has been implicated.⁽⁵⁾

Multiple fragile, cystic, or solid masses are the macroscopic feature of paratesticular mesothelioma, and light microscopy shows epithelioid cells, fusiform cells, or a mixture of these patterns. Complementary techniques, including immunostaining, immunohistochemistry, and electron microscopy can help differentiate the lesion from adenocarcinoma. Mesothelioma can produce large amounts of hyaluronic acid, which results in positive alcian blue and colloidal iron staining. However, a positive reaction to periodic acid-Schiff staining and mucicarmine is highly suggestive for ruling out malignant mesothelioma.^(6,7) On electron microscopy, microvilli are longer and thinner in malignant mesothelioma than in adenocarcinoma.⁽⁸⁾ Positive reactivity for cytokeratin cocktail, vimentin, epithelial membrane antigen, and S-100, and occasionally to desmin and bcl-2, is seen on immunohistochemistry, but reactions for carcinoembryonic antigen, Leu-M1, and B72.3 markers are almost always negative.⁽⁹⁾

Plas and colleagues reviewed 73 cases of malignant mesothelioma of tunica vaginalis diagnosed during a 30-year period.⁽¹⁰⁾ They concluded that the prognosis is poor, corresponding to a mean survival of 23 months.

Radical orchiectomy and extensive surgical resection of the suspicious sites is the definitive treatment. Chemotherapy and radiotherapy do not increase survival rate significantly, unless distant metastases are present at diagnosis.

A common clinical course of paratesticular mesotheliomas is the local recurring of the tumor and subsequently, metastases to inguinal and iliac lymph nodes.⁽¹¹⁾ It should be noted that macroscopic and histopathological examinations of scrotal lesions in patients with hydrocele are

necessary to help determine the etiology of these lesions.

References

1. Reynard JM, Hasan N, Baithun SI, Newman L, Lord MG. Malignant mesothelioma of the tunica vaginalis testis. *Br J Urol.* 1994;74:389-90.
2. Jones MA, Young RH, Scully RE. Malignant mesothelioma of the tunica vaginalis. A clinicopathologic analysis of 11 cases with review of the literature. *Am J Surg Pathol.* 1995;19:815-25.
3. Gupta NP, Agrawal AK, Sood S, Hemal AK, Nair M. Malignant mesothelioma of the tunica vaginalis testis: a report of two cases and review of literature. *J Surg Oncol.* 1999;70:251-4.
4. Whitaker D, Papadimitriou JM, Walters MN. The mesothelium; techniques for investigating the origin, nature and behaviour of mesothelial cells. *J Pathol.* 1980;132:263-71.
5. Morikawa Y, Ishihara Y, Yanase Y, et al. Malignant mesothelioma of tunica vaginalis with squamous differentiation. *J Urol Pathol.* 1994;2:95-102.
6. Kwee WS, Veldhuizen RW, Golding RP, et al. Histologic distinction between malignant mesothelioma, benign pleural lesion and carcinoma metastasis. Evaluation of the application of morphometry combined with histochemistry and immunostaining. *Virchows Arch A Pathol Anat Histol.* 1982;397:287-99.
7. McCaughey WT, Colby TV, Battifora H, et al. Diagnosis of diffuse malignant mesothelioma: experience of a US/Canadian Mesothelioma Panel. *Mod Pathol.* 1991;4:342-53.
8. Burns TR, Greenberg SD, Mace ML, Johnson EH. Ultrastructural diagnosis of epithelial malignant mesothelioma. *Cancer.* 1985;56:2036-40.
9. Holden J, Churg A. Immunohistochemical staining for keratin and carcinoembryonic antigen in the diagnosis of malignant mesothelioma. *Am J Surg Pathol.* 1984;8:277-9.
10. Plas E, Riedl CR, Pfluger H. Malignant mesothelioma of the tunica vaginalis testis: review of the literature and assessment of prognostic parameters. *Cancer.* 1998;83:2437-46.
11. Butnor KJ, Sporn TA, Hammar SP, Roggli VL. Well-differentiated papillary mesothelioma. *Am J Surg Pathol.* 2001;25:1304-9.