

A Giant Congenital Posterior Urethral Diverticulum Associated with Renal Dysplasia

Shahram Mousavi, Abdolrasoul Mehrsai, Mohammadreza Nikoobakht, Amir Reza Abedi, Sepehr Salem, Gholamreza Pourmand

Keywords: congenital, urethra, diverticulum, mullerian ducts, renal dysplasia

Urol J (Tehran). 2006;4:247-9.
www.uj.unrc.ir

INTRODUCTION

There is a paucity of information about congenital posterior urethral diverticulum (PUD). In the English literature, only 3 cases have been reported.⁽¹⁻³⁾ We report a unique case of PUD in association with renal dysplasia.

CASE REPORT

A 19-year-old man with a history of recurrent urinary tract infection (UTI) due to *Escherichia coli*, chronic urinary obstructive symptoms, and incomplete bladder emptying since childhood presented to Sina Hospital. The patient did not mention any history of the urethral trauma, instrumentation, or surgical intervention. Physical examination revealed a massive bladder distention up to the umbilicus. Examination

of the external genitalia was unremarkable. Serum creatinine level was 1.3 mg/dL and other biochemistry results were within the reference ranges.

In the evaluations performed by ultrasonography and renal scintigraphy, the right kidney was absent and the left one showed compensatory hypertrophy. A large bladder and a large mass in the left side of the pelvis with multiple hyperechoic masses were seen. On CT scan, there was a large cystic mass beginning from the lower pole of the right kidney extending into the pelvis (Figure 1). There was another cystic mass, posterior to the first one, which was at a lower level in the pelvis. The left kidney was normal with significant ureteral dilatation. Voiding cystourethrography (VCUG) showed a giant diverticulum, communicating with the urethra, shifting the bladder to the right side. Also, left vesicoureteral reflux was noted (Figure 2).

On urethrocystoscopy, an orifice was seen adjacent to the verumontanum. The ureteroscope was advanced into a capacious pouch full of debris. Its volume was approximately 500 milliliters. There was a long prostatic urethra (approximately 4 cm) and an elevated bladder neck. A huge moderately trabeculated bladder with a fully developed trigone was observed. Although the left ureteral orifice was

Urology Research Center, Sina Hospital, Tehran University of Medical Sciences, Tehran, Iran

Corresponding Author:

Shahram Mousavi, MD

Urology Research Center,

Sina Hospital, Hasan-Abad sq,

Tehran, Iran

Tel: +98 21 6671 7447

Fax: +98 21 6671 7447

E-mail: shahram_moosavi1353@yahoo.com

Received January 2006

Accepted July 2006

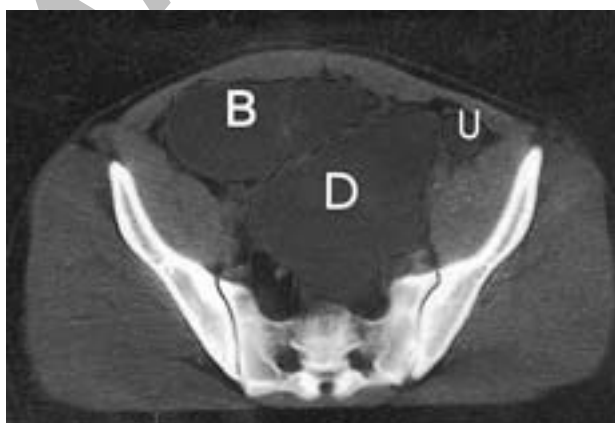


Figure 1. A slice from the abdominopelvic CT scan. B indicates the bladder; D, diverticulum; and U, the ureter.

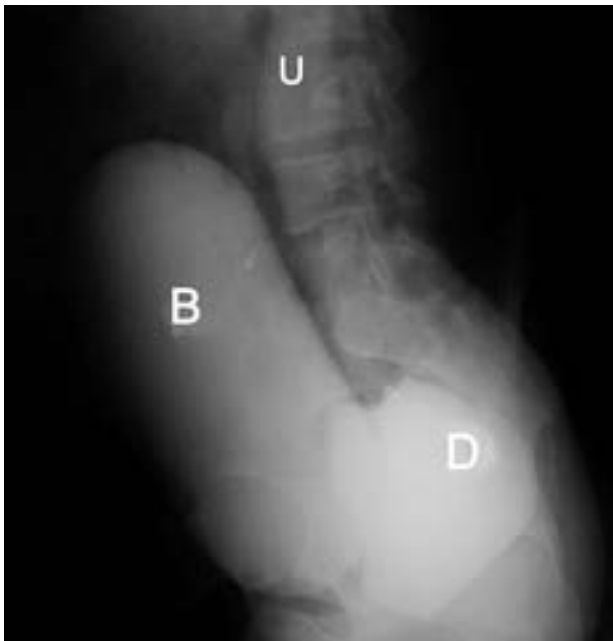

Figure 2. Lateral view of the bladder, the diverticulum, and the left ureter. B indicates the bladder; D, diverticulum; and U, the ureter.

prominent, our effort to find the right ureteral orifice was not successful. Posterior urethral valve (PUV) was not detected in our evaluation.

A Foley catheter was inserted into the diverticulum. The large diverticulum was dissected from the surrounding tissues and the urinary bladder through

a lower midline incision; its communication with the posterior part of the urethra was identified and the diverticulum was resected completely (Figures 3 and 4). The right kidney was absent. The right ureter was dissected completely. Reduction cystoplasty was also performed. Foley catheters were placed into the bladder and the perivesical space. The pathologic evaluation of the tip of the resected ureter indicated features of a dysplastic kidney. The wall of the diverticulum consisted of the muscle cells and squamous epithelium.

After the catheter removal, the patient experienced a transient period of stress incontinence which was spontaneously relieved after 2 months. Vesicoureteral reflux disappeared on the follow-up VCUG. On retrograde urethrography, there was no stricture. No episode of UTI was reported during the 6 months' follow-up. The only complication reported was meatal stenosis that was corrected by meatotomy. During the follow-up period, serum creatinine levels were within the normal range with an average of 1.2 mg/dL (range, 0.9 mg/dL to 1.7 mg/dL).

DISCUSSION

Urethral diverticulum is an epithelium-lined pouch that is formed because of either distention

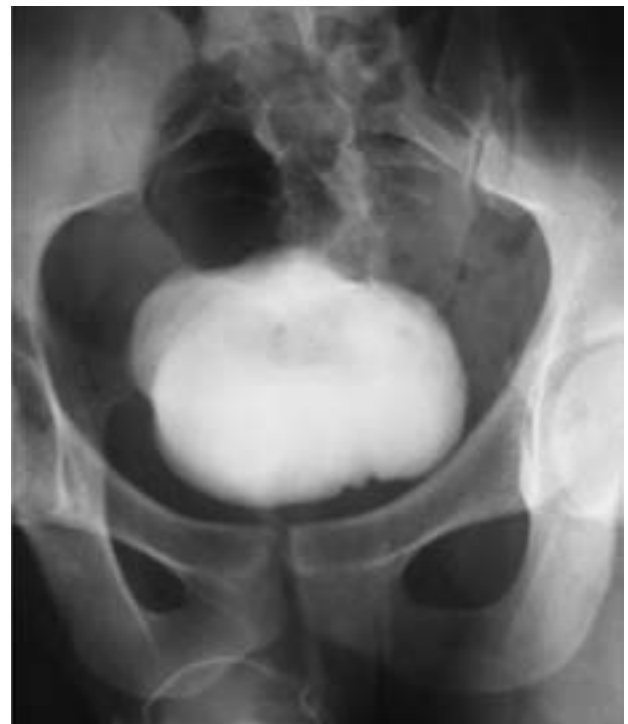
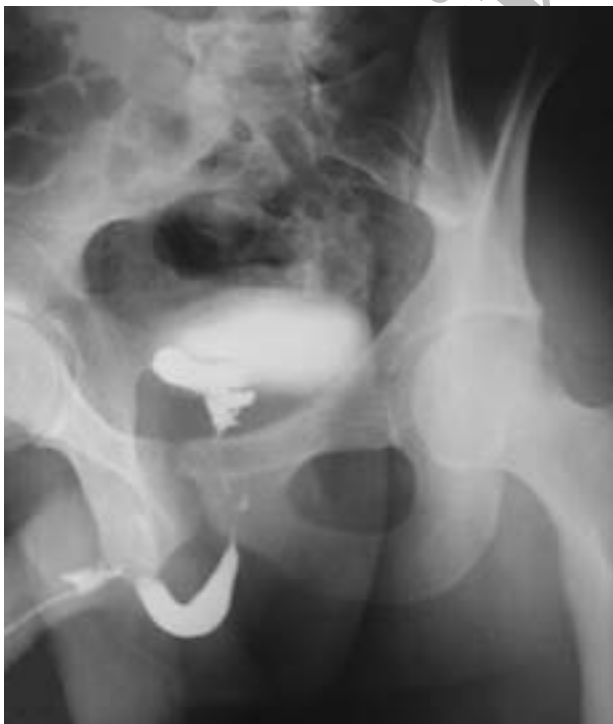
Figure 3. Retrograde urethrography. **Left,** Preoperative image. **Right,** Postoperative image.

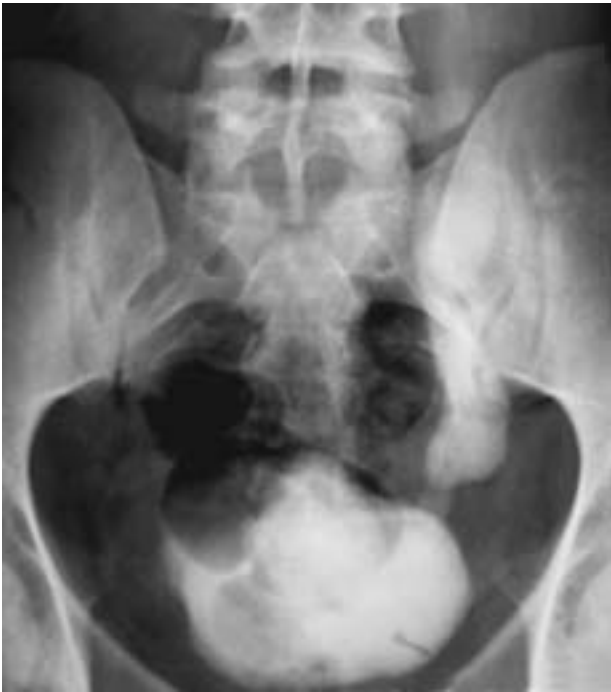

Figure 4. Postoperative voiding cystourethrography demonstrated no remained diverticula.

of a segment of the urethra or the attachment of a structure to the urethra by a narrow neck (ie, a Mullerian remnant).⁽⁴⁾ This condition, especially in men, is extremely rare and may be congenital or acquired. An acquired diverticulum usually forms due to infection, urethral stricture, and/or trauma.⁽⁵⁾ Majority of the cases with PUD are of the Mullerian origin. The remainders are formed as a result of an aborted urethral duplication. The Mullerian remnants may be prostatic utricles or Mullerian duct cysts.⁽¹⁾ Prostatic utricles do not usually require any treatment, unless they become very large causing recurrent UTIs or other complications.⁽⁴⁾ Mullerian duct cysts are cystic dilatations in the remnants of the distal ends of the fused Mullerian ducts. They rarely communicate with the urethra. If they are connected to the urethra, they usually enter the midline of verumontanum.⁽¹⁾

Esposito and colleagues reported a giant congenital PUD in a 4-year-old boy with an enlarged utricle.⁽²⁾ The 41-year-old patient described by Plank and Scholen was a case of congenital PUD simulating Mullerian duct cyst.⁽³⁾ These authors concluded that the detected cases of PUD were not of Mullerian origin in neither of the articles mentioned. Similar to Ng's report,⁽¹⁾ all features of our case including its midline location, well developed external genitalia,

and the absence of communication with genital tract imply that this is a Mullerian duct cyst.

The method of treatment depends on the size of the diverticulum and the degree of the obstruction. Small and asymptomatic lesions may just be followed up.⁽⁶⁾ Excision of the symptomatic lesions is often a surgical challenge. There are different approaches for the symptomatic lesions. Classically, they are excised through suprapubic, retroversical, or transvesical approaches^(7,8); however, while some authors have used this approach with an acceptable success rate, others have shown a lower rate of complete excision in their cases.⁽⁹⁾ A posterior approach has been advocated for the better maintenance of the erectile response.⁽¹⁰⁾ Perineal approach affords more direct access for diverticula originating at the level of the urogenital diaphragm.⁽³⁾ Our case is unique due to the existence of both renal dysplasia and congenital PUD.

CONFLICT OF INTEREST

None declared.

REFERENCES

1. Ng WT. Congenital posterior urethral diverticulum. *Aust N Z J Surg.* 1996;66:717-9.
2. Esposito G, Savanelli A, Tenore A, Tamburrini O, Palescandolo P, Di Tuoro A. Congenital giant diverticulum of the posterior urethra in a 4-year-old boy. *Z Kinderchir.* 1986;41:244-5.
3. Plank LE, Schoen WA Jr. Congenital prostatic urethral diverticulum simulating mullerian duct cyst. *J Urol.* 1960;84:144-6.
4. Jordan GH, Schlossberg SM. Surgery of the penis and urethra. In: Walsh PC, Retik AB, Vaughan ED Jr, et al, editors. *Campbell's urology.* 8th ed. Philadelphia: WB Saunders; 2002. p. 3903-4.
5. Laungani RG, Angermeier KW, Montague DK. Giant urethral diverticulum in an adult male: a complication of the artificial urinary sphincter. *J Urol.* 2003;170:1307-8.
6. Mohan V, Gupta SK, Cherian J, Tripathi VN, Sharma BB. Urethral diverticulum in male subjects: report of 5 cases. *J Urol.* 1980;123:592-4.
7. Smith JA Jr, Middleton RG. Surgical approach to large mullerian duct cysts. *Urology.* 1979;14:44-6.
8. Monfort G. Transvesical approach to utricular cysts. *J Pediatr Surg.* 1982;17:406-9.
9. Schuhrke TD, Kaplan GW. Prostatic utricle cysts (mullerian duct cysts). *J Urol.* 1978;119:765-7.
10. Wesson MB. Cysts of the prostate and urethra. *J Urol.* 1925;13:605-29.