

Plexiform Neurofibroma of Penis

Hamid Mazdak, Mohammad Reza Gharaati

Keywords: urogenital cancers, penis, neurofibroma

Urol J (Tehran). 2007;4:52-4.
www.uj.unrc.ir

INTRODUCTION

Neurofibromas are tumors originating from the Schwann cells in the neural sheath of the cranial, peripheral, and visceral nerves. The gross appearance of neurofibromas varies greatly in different lesions. Superficial tumors appear as small, soft, pedunculated, or sessile nodules protruding from the skin. But, deeper tumors are larger. Tumors resulting in diffuse tortuous enlargement of the peripheral nerves are designated as *plexiform neurofibromas*.⁽¹⁾ This particular form of neurofibroma is more commonly seen in the orbit, the neck, the back, and the inguinal region, and diffuse involvement of the nerves may make complete resection impossible. Primary neurofibromas of the penis are extremely rare. To our knowledge, since 1970, only 7 cases have been reported.^(2,3) We hereby report another case of plexiform neurofibroma of the penis.

CASE REPORT

A 5-year-old mentally and developmentally retarded boy presented with massive penile enlargement started shortly after circumcision 2 years earlier. He had a history of laryngomalacia in infancy, which had improved without surgery, and a history of tonsillectomy and left orchiopexy. There was no family history of a similar condition. Physical examination revealed massive enlargement of the entire penis with firm consistency and no tenderness (Figure 1). He did not have any cafe-au-lait spots anywhere. In addition, he had dysarthria. The kidneys and the bladder were normal on ultrasonography. Magnetic resonance imaging (MRI) revealed a large penile mass with extensive involvement of the cavernous bodies and corpus spongiosum (Figures 2 and 3).

Department of Urology, Al-Zahra Hospital, Isfahan University of Medical Sciences, Isfahan, Iran

Corresponding Author:
Mohammad Reza Gharaati, MD
Department of Urology, Al-Zahra Hospital, Sofeh St, Isfahan, Iran
Tel: +98 311 265 4766
E-mail: gharaati@resident.mui.ac.ir

Received January 2006
Accepted December 2006

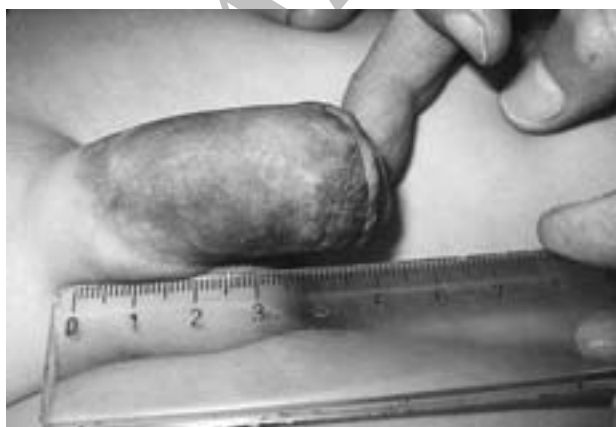

Figure 1. Penile shaft enlargement.

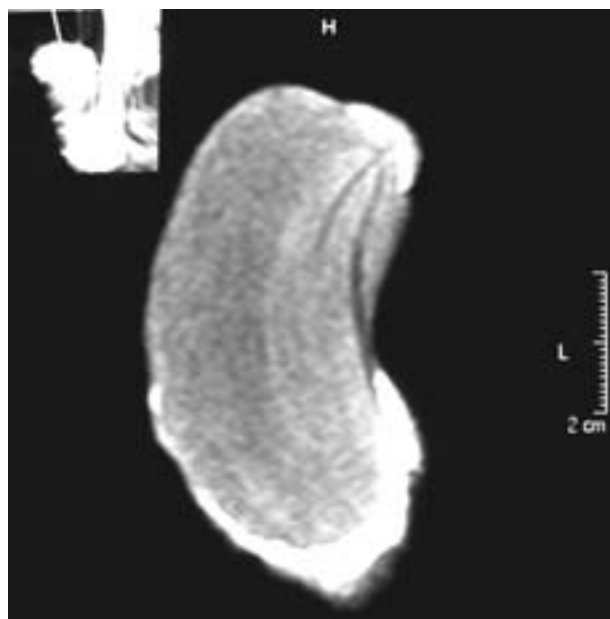


Figure 2. Magnetic resonance imaging shows a penile mass with involvement of the cavernous bodies (T1 weighted imaging).

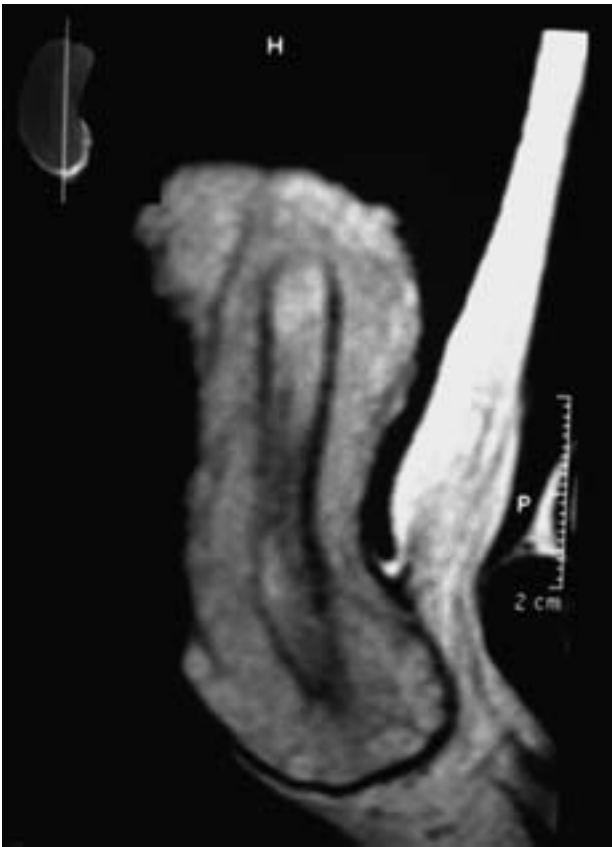

Figure 3. Penile mass (T2 weighted imaging).

Cystoscopy was indicative of a nonobstructive urethra.

He underwent operative treatment through a circumferential subcoronal incision and the penis was degloved. The large penile mass was adherent to the underlying the tunica albuginea of both corpora cavernosa and corpus spongiosum. Complete excision of the mass was impossible in the base and the dorsal aspect of the penis because of the large size of the lesion and the risk of neurovascular injury. Partial excision of the mass was therefore performed.

Histopathologic study revealed bundles of spindle cells separated by fibrous septa in a mixoid matrix, suggestive of plexiform neurofibroma (Figure 4). Immunostaining was positive for S-100 protein (a marker of the glial and Schwann cells), but negative for actin (a marker of the smooth muscle cells and myofibroblasts), desmin, and Myo-D1 (markers of the smooth and striated muscle cells).

At the 13th postoperative month, there was no significant increase in the size of the residual tumor on physical examination.

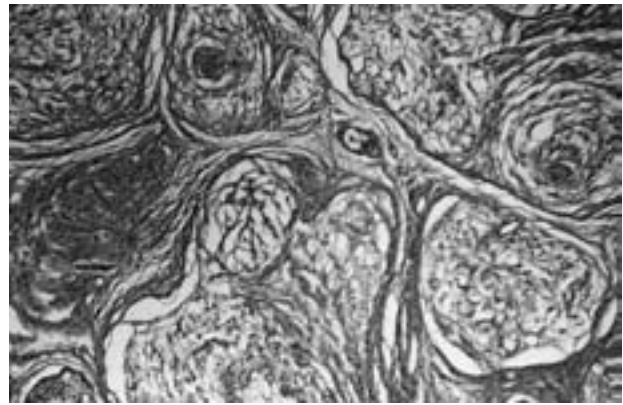


Figure 4. Histopathologic study revealed bundles of the spindle cells separated by fibrous septa in a mixoid matrix (hematoxylin-eosin, $\times 40$).

DISCUSSION

Multiple neurofibromas represent the most important component of the genetically determined disorder known as neurofibromatosis or von Recklinghausen's disease. Cafe-au-lait spots are characteristic cutaneous lesions of classic neurofibromatosis. Plexiform neurofibromas, which are usually seen in the context of type 1 neurofibromatosis, may result in massive enlargement of a limb or some other part of the body (*elephantiasis neuromatosa*).⁽¹⁾

Primary neurofibroma of the penis in children is an extremely rare disease, and since 1970, only 7 cases have been reported.^(2,3) All of the reported patients had presented with an abnormally enlarged penis. Some of them had cafe-au-lait spots on their skin, but some others had no skin lesion or any sign suggestive of cranial or visceral nerve involvement, and the huge plexiform neurofibroma of the penis had been the only manifestation of the disease.⁽³⁾ One reported patient had a large penile mass, numerous cafe-au-lait spots over his entire body, trouble in coordinating upper extremities, dysarthria, and dysphagia.⁽²⁾ In most of the previously reported cases, tumors have been small and completely excised. In 1 case, the mass was contiguous with the dorsal neurovascular bundle of the penis, and therefore, was only partially excised.⁽²⁾ In 2 other cases, partial penectomy was done because of extensive involvement of the cavernous bodies and the corpus spongiosum.^(3,4)

Unlike cutaneous neurofibromas, plexiform neurofibroma may undergo malignant transformation.⁽³⁾ Therefore, the optimal treatment

is complete excision of the tumor. However, partial resection with close follow-up is recommended when complete resection might result in major neurovascular or functional defect of the penis. Follow-up consists of periodic physical examination and MRI.⁽³⁾

REFERENCES

1. Rosenblum MK. Neuromuscular system. In: Rosay J, editor. Rosai and Ackerman's surgical pathology. 9th ed. St Louis: Mosby; 2004. p. 2266-9.
2. Littlejohn JO, Belman AB, Selby D. Plexiform neurofibroma of the penis in a child. *Urology*. 2000;56:669.
3. Rodo J, Medina M, Carrasco R, Morales L. Enlarged penis due to a plexiform neurofibroma. *J Urol*. 1999;162:1753-4.
4. Mathews R, Patil U, Uner A, Landas S, Mahanta RK. Giant neurofibroma of the penis in a child. *Br J Urol*. 1996;78:649-50.

Archive of SID