

# Real-Time Point-to-Point Wireless Intranet Connection First Implication for Surgical Demonstration and Telementoring in Urologic Laparoscopic Surgery in Khorasan

Mohammad Nadjafi-Semnani,<sup>1</sup> Nasser Simforoosh,<sup>2</sup> Nahid Ghanbarzadeh,<sup>1</sup>  
Mohammad Reza Miri<sup>1</sup>

*Keywords: laparoscopy, telemedicine,  
computer communication networks,  
distance education*

*Urol J. 2008;5:74-8.  
www.uj.unrc.ir*

## INTRODUCTION

Using communication technologies, physicians have the benefit of telemedicine to better deliver healthcare.<sup>(1)</sup> Telemedicine has been used by different specialties since 1950s, initially for forwarding the medical records of patients, and later, for other purposes such as education, training, counseling, and mentoring.<sup>(2)</sup>

Telesurgical telementoring is an advanced form of telemedicine. Utilizing current video technology, medical robots, and high-bandwidth telecommunications, experienced surgeons can guide and teach practicing surgeons new operative techniques.<sup>(1)</sup> Surgical sciences have been revolutionized by the continuous advancement of laparoscopic, endoscopic, and minimally invasive procedures during the past two decades.<sup>(3)</sup> Urology has been in the forefront of this innovation; the endourologic and laparoscopic techniques have renovated this specialty.<sup>(3)</sup> The first report of telementoring in urologic laparoscopic surgery was published in 1996.<sup>(4)</sup> In this procedure, the mentor in the remote area sees the real-time video of the surgeon's performance at the operation room in their office and can talk

and guide them accordingly. We describe the first academic report of telementoring in urologic laparoscopic surgery from Iran. This study was conducted to examine the technologic facilities in Iran for a setup of point-to-point wireless intranet connection for telementoring. We could provide adequate video and audio teleconferencing and image quality to support remote real-time surgical demonstration and telementoring.

## TELEMENTORING SETUP

We conducted a telementoring procedure with 2 multimedia workstations communicating with each other over the university's local area network (LAN). Laparoscopic extraperitoneal trigonoplasty was selected for telementoring as an educational event during the National Seminar on Neonatal Circumcision in Birjand, a city in Khorasan province, Iran, in December 15, 2005.

## Laparoscopic Procedure

Laparoscopic extraperitoneal trigonoplasty was first reported by Simforoosh and colleagues in Shahid Labbafinejad Medical Center in Tehran.<sup>(5)</sup> The mentor was the innovator of this procedure and the

<sup>1</sup>Birjand University of Medical Sciences, Birjand, Iran

<sup>2</sup>Department of Urology, Shahid Labbafinejad Medical Center and Urology and Nephrology Research Center, Shahid Beheshti University (MC), Tehran, Iran

Corresponding Author:  
Mohammad Nadjafi-Semnani, MD  
PO Box: 493 Birjand, Iran  
Tel: +98 561 222 9129  
Fax: +98 561 223 2622  
E-mail: monadjafi@gmail.com

This article has been presented as an abstract in the Engineering and Urology Society's annual meeting in Anaheim, California, May 18, 2007 and has been presented as a poster in the 25th World Congress of Endourology, Cancun, Mexico, November 1, 2007.

Received December 2007  
Accepted March 2008

laparoscopic surgeon was an experienced fellow of endourology and urolaparoscopic surgery practicing in Birjand, a city in the northeast of Iran. The patient was a 10-year-old boy who presented with abdominal and flank pain and hematuria. The intravenous urography revealed right hydronephrosis and a 22-mm calculus in the right pelvis. Voiding cystourethrography revealed bilateral vesicoureteral reflux (VUR). Grade 3 VUR was seen in the right and grade 1 in the left side. He had undergone right-side percutaneous nephrolithotomy in Emam Reza hospital, Birjand 30 days earlier and became stone free. Then, the patient presented for the therapy of VUR. His parents were informed on the different method of antireflux surgery we had planned, and they opted to undergo laparoscopic repair of his reflux. Informed consent was obtained from the parents.

The technique and results of this novel laparoscopic procedure had previously been reported.<sup>(5)</sup> This laparoscopic procedure duplicates exactly the same principles and steps which were introduced by Gil-Vernet trigonoplasty antireflux operation.<sup>(6)</sup> We performed laparoscopic trigonoplasty as follows: an 11-mm incision was made over the lower crease of the umbilicus. The rectus fascia was opened transversely at the midline. Fibrous adhesion bands between the anterior and posterior layers of the rectus sheaths up to the arcuate line were cut with scissors. Next, a finger was introduced under the rectus muscle, and the extraperitoneal space between the bladder, rectus muscles, and lateral abdominal wall was developed by posterior and lateral finger movements. This space was further developed by balloon dilation. The first trocar (10 mm) was placed by open technique in this space. Under

carbon dioxide insufflations and direct vision, 3 trocars (5 mm) were placed. The bladder was opened at low midline for about 3 cm to 4 cm with laparoscopic scissors. The ureteral orifices were then identified and 2 trimmed ureteral catheters were inserted intracorporeally into the ureters. A superficial transverse incision was made with laparoscopic scissors through the mucosa between the ureters 2 mm lateral to the orifices. Extending this incision in a U fashion around the medial aspect of the ureteral orifices, the medial aspect of both ureters was cleared of the muscles and attachments. Two 4-0 polyglactin horizontal mattress sutures were placed through both ureteral walls and the Waldeyer's sheath near the orifices, and the ureters were approximated in the midline. At this stage, both ureteral orifices were advanced medially across the previously incised mucosal trough, and thus, their submucosal tunnels were lengthened. Superior and inferior to the horizontal mattress suture, two 4-0 polyglactin sutures were placed to bring together the epithelium and convert the horizontal mucosal incision to a vertical closure line. The ureteral catheters were removed. The bladder was closed with a 2-0 polyglactin running suture. A drain was placed through the lower port.

### Multimedia Workstations Configuration

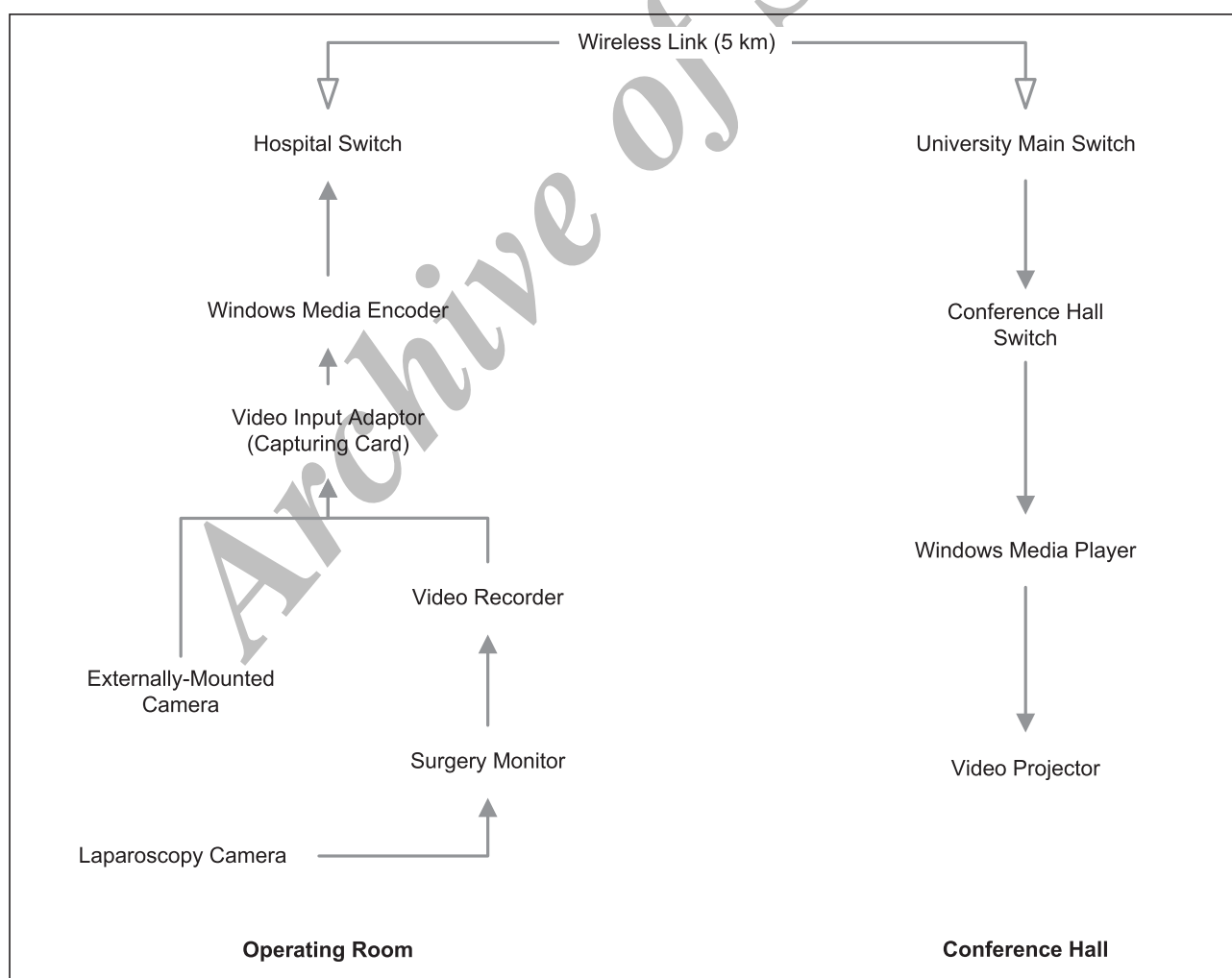
Although advanced commercially prepared packages were available for establishing this telecommunication, due to limited resources, we decided to use another efficient cost-effective setup for laparoscopic telementoring. Two multimedia workstations were setup in Birjand University of Medical Sciences main conference hall and Emam Reza Medical Center operating room (Table). These two workstations were 5

Technical Details of 2 Interactive Multimedia Workstations

Hardware	Operating Room	Conference Hall
<b>Network standards</b>	LAN (10/100) IP/H323	LAN (10/100) IP/H323
<b>Video Input Adaptor</b>	Maxtor 100 Capturing Card	None
<b>External camera</b>	Sony DCR-PC 109E	None
<b>Video hardware</b>	Panasonic VCR	None
<b>Wireless transmission rate</b>	27 Mbps	27 Mbps
<b>Microphone software</b>	Sony Wireless	Sony Wired
<b>Operating system</b>	Windows XP	Windows XP
<b>Telecommunication software</b>	Windows NetMeeting	Windows NetMeeting
<b>Video image transferring software</b>	Windows Media Encoder	Windows Media Encoder

km away from each other and were connected at a transmission rate of 27 Mbps through the university LAN by wireless point-to-point intranet connection device (Linksys Inc, Taipei, Taiwan) as shown in the Figure. The laparoscopic mentor (professor Simforoosh), who was the chairman of this educational event, and the audience of the seminar in the main conference hall of the university could see, hear, and talk to the laparoscopic surgeon interactively. The laparoscopic (internal body view) or an externally mounted camera (overview of the operating room) videos were projected alternatively on the screen. The laparoscopic surgeon could hear the mentor and the questions asked by the audience and talked to them interactively, but he did not have their pictures. The data was transmitted through the optic fiber between

the computer center of the university and the conference hall and by a category 6 cable from the operating room to the computer center in Emam Reza hospital. The Windows NetMeeting (Microsoft, Redmond, Washington, USA), two microphones, and a Sony camcorder were used for live interactive telecommunication (audio and overview of the operating room). For fast transmission of high-quality video images over the LAN, the Windows Media Encoder (Microsoft, Redmond, Washington, USA) was used. This software has many advantages including adjustment of transmission rate, ability of different LAN users to see simultaneously the transmitted videos over the LAN by free Windows Media Player software, and that the capability of broadcasting the streaming videos on the internet. After installing the Windows Media



Interactive computing multimedia workstations configuration.

Encoder on the computers in both workstations, the user in the conference hall, knowing the IP address and port number of the operating room computer, could see the videos online and project them on the conference hall screen by a video projector.

### Video Image Captures

Routine laparoscopic images were first transferred to the monitor in front of the surgeon, then to the video recorder and from the video recorder to the capturing card of the operating room computer. For capturing and transmitting the laparoscopic and external video images to the LAN without frame drop, professional Maxtor 100 capturing card (Matrox Electronic Systems Ltd, Dorval, Quebec, Canada) in the real time was used. Sony camcorder DCR-PC 109E (Sony Inc, Tokyo, Japan) was used as externally mounted camera and connected alternatively to the capturing card to transmit the external video images from operation room and surgical team.

### Image Evaluation

For evaluating the quality of the transmitted images, the opinion of the laparoscopic mentor was sought. In addition, to evaluate further, the effect of transmitting laparoscopic video images, 5 paired local and remote digital still images were “grabbed” from the video feed as previously described by Broderick and associates.<sup>(7)</sup> These images were pasted to digital graphic editing software, and then, they were opened in the Access program (Microsoft Office, Microsoft, Redmond, Washington, USA). These images were presented in a blinded fashion separately and later together as paired pictures to the laparoscopic surgeon and he was asked to evaluate the images with regard to his ability to identify the captured images and the quality of the images and to score them (scale 1 to 10 as poor to excellent).

By the setup of point to point wireless intranet connection over the university’s LAN, demonstration of a novel laparoscopic antireflux technique for the participants of an Iranian national congress became possible. Through this connection, the teleconference with adequate audio and video quality and live real-time

broadcast of laparoscopic surgery from the operating room to the university conference hall was accomplished. In addition, this connection was able to allow adequate transmission of high-quality video images to be seen by the laparoscopic mentor for surgical decision making and telementoring. The mentor in the conference hall was able to identify the Waldeyer’s sheath over the bared ureteral wall and the transmitted images were evaluated as excellent quality by him. It has been suggested by Simforoosh and colleagues that the long-term success in this laparoscopic technique depends entirely on the suturing of the ureteral walls and the Waldeyer’s sheaths to each other.<sup>(5)</sup> In addition, evaluation of the grabbed images from the operating room and the conference hall by the laparoscopic surgeon revealed that all images received the scale of 9 to 10, and he was not able to differentiate the origin of the images.

### DISCUSSION

Telementoring is defined as active real-time teaching and requires videoconferencing between the local and remote surgeons. This interaction depends on transmission of audiovisual signals simultaneously in both directions.<sup>(3)</sup> The remote surgeon acts as a preceptor to provide guidance through difficult operations. Laparoscopic surgery requires long-term practice and mentorship, and it has a steep learning curve. Telementoring would be a good answer to this demand. Telementoring can potentially enhance surgeons’ education, increase patients’ access to experienced surgeons, and decrease the likelihood of complications resulted from lack of experience with new techniques.<sup>(1)</sup> Telementoring may also be useful because it allows surgeons to teach their colleagues without any inconveniences such as traveling to the teaching seminar venues.<sup>(8)</sup>

The first published telementored laparoscopic procedures were performed by a group at Johns Hopkins in 1996 who successfully telementored 22 of 23 laparoscopic procedures including simple and radical laparoscopic nephrectomies.<sup>(4)</sup> Successful early telementoring experiences have encouraged extensive and wider application.<sup>(8)</sup> Abdirad and colleagues recently have published

the first academic telemedicine in the field of pathology from Iran.<sup>(9)</sup> To our best knowledge, this is the first report from Iran regarding telementoring in laparoscopic urologic surgery. We used a practical setup of software and LAN. We first tested the Microsoft NetMeeting software for this live telecommunication. Although it was very useful for live interactive conversation and teleconference, as was used in our study for interactive communication between laparoscopic surgeon and his mentor, due to its low quality of transmitted video images, it was not suitable for telementoring. Instead, we found that high-speed transmission of video images by Windows Media Encoder was a very efficient and cost-effective telecommunication means. Transmitted video images can be seen in any place over LAN by the media player software. Our study revealed that the quality of transmitted video images is very suitable for telementoring. We think this setup is especially useful in residency and fellowship programs in teaching hospitals where the responsible attending surgeon has to care for different surgeries in different operating rooms at the same time while sitting in his office in the main operating room. They can also continue this surveillance in all places where the LAN is accessible. Moreover, laparoscopic video images have been employed for teaching anatomy to medical students and surgical residents.<sup>(10)</sup> This setup is also useful in teaching anatomy to medical students as the transmitted image can be seen in different departments simultaneously.

Unavailability of telestrator video sketchpad in our study is one of our setup limitations. This device would be very instrumental for the mentor to illustrate the operative plan to the laparoscopic surgeon and the audience in the seminar.<sup>(3)</sup> However, our setup of connection through the university LAN could provide adequate video and audio teleconferencing and image quality to support remote real-time surgical demonstration and telementoring. This is especially useful for

developing countries where due to the limited resources, they cannot afford commercially prepared packages for telementoring in laparoscopic surgeries.

## CONFLICT OF INTEREST

None declared.

## ACKNOWLEDGEMENT

The authors would like to acknowledge the help and support of Dr Tohid Azizi for accomplishing this study.

## REFERENCES

1. Lee BR, Bishoff JT, Janetschek G, et al. A novel method of surgical instruction: international telementoring. *World J Urol.* 1998;16:367-70.
2. Rosser JC, Jr., Gabriel N, Herman B, Murayama M. Telementoring and teleproctoring. *World J Surg.* 2001;25:1438-48.
3. Varkarakis IM, Rais-Bahrami S, Kavoussi LR, Stoianovici D. Robotic surgery and telesurgery in urology. *Urology.* 2005;65:840-6.
4. Moore RG, Adams JB, Partin AW, Docimo SG, Kavoussi LR. Telementoring of laparoscopic procedures: initial clinical experience. *Surg Endosc.* 1996;10:107-10.
5. Simforoosh N, Nadjafi-Semnani M, Shahrokhi S. Extraperitoneal laparoscopic trigonoplasty for treatment of vesicoureteral reflux: novel technique duplicating its open counterpart. *J Urol.* 2007;177:321-4.
6. Gil-Vernet JM. A new technique for surgical correction of vesicoureteral reflux. *J Urol.* 1984;131:456-8.
7. Broderick TJ, Harnett BM, Doarn CR, Rodas EB, Merrell RC. Real-time Internet connections: implications for surgical decision making in laparoscopy. *Ann Surg.* 2001;234:165-71.
8. Pande RU, Patel Y, Powers CJ, D'Ancona G, Karamanoukian HL. The telecommunication revolution in the medical field: present applications and future perspective. *Curr Surg.* 2003;60:636-40.
9. Abdirad A, Sarrafpour B, Ghaderi-Sohi S. Static telepathology in cancer institute of Tehran university: report of the first academic experience in Iran. *Diagn Pathol.* 2006;1:33.
10. Satava RM. Surgical education and surgical simulation. *World J Surg.* 2001;25:1484-9.