

# Transanal Repair of Rectourethral and Rectovaginal Fistulas

Ali Razi, Seyed Reza Yahyazadeh, Mohammad Ali Sedighi Gilani,  
Seyed Mohammad Kazemeyni

**Introduction:** We evaluated the efficacy and safety of repair of the rectourethral and rectovaginal fistulas with transanal approach using the Latzko technique.

**Materials and Methods:** We repaired 8 fistulas with transanal approach. Fistulas were rectourethral in 5 patients, and in the only woman of the series, they were rectovaginal and vesicovaginal. In 3 patients, The fistulas had been diagnosed following prostatectomy, urethral stricture repair, and colonic resection and radiotherapy due to rectosigmoid cancer in 3, 2, and 1 patients, respectively. Complying with Latzko technique, the fistula orifice was exposed and a fusiform incision was made with the orifice in its center. The mucosa lying between the incision and the orifice was excised in the direction of the incision to the orifice, leaving the fistula edges to meet. Then, the edges were closed, followed by closure of the muscular layers above it. Finally, the edges of the rectal mucosa were closed

**Results:** Two patients had 2 fistulas and 4 had 1 fistula who were all managed by transanal approach. During a median follow-up period of 44 months, no serious complication was noted, except for recurrence of deep vein thrombosis in 1 patient with a positive history for this complication. Hospitalization period was 1 to 7 days.

**Conclusion:** It seems that transanal repair is a simple and effective technique with minimal complication rate in the treatment of rectourethral fistulas. Regardless of the etiology, this method can be used as the preferred therapeutic technique. Further studies are necessary to confirm our findings.

Keywords: rectal fistula, urethra, surgery, transanal approach

Urol J. 2008;5:111-4.  
www.uj.unrc.ir

Department of Urology, Shariati Hospital, Tehran University of Medical Sciences, Tehran, Iran

Corresponding Author:  
Ali Razi, MD  
Department of Urology, Shariati Hospital, North Karegar St, Tehran, Iran  
Tel: +98 912 159 0209  
Fax: +98 21 8802 6010  
E-mail: reza\_mehr@yahoo.com

Received November 2007  
Accepted March 2008

## INTRODUCTION

Rectourethral and rectovaginal fistulas, connections between the gastrointestinal and genitourinary systems, are very unpleasant complications. Patients present with recurrent urinary tract infections and passing mixed urine and stool in most of the cases. Repair of these fistulas by perineal or abdominal methods is difficult and needs extensive dissections and interposition of the omentum,

fatty tissue, or muscles. Obviously, these difficult operations are accompanied by a high rate of complications and low success rate.<sup>(1,2)</sup> Conversely, transanal repair is an easier approach with easier access, shorter operative time, and lower complication rate. However, it has not been reported very often in the literature.<sup>(3,4)</sup> The present study bears evidence to the feasibility and safety of the transanal technique of repair in

addition to its high success rate. Our aim was to determine the efficacy, simplicity, and safety of Latzko transanal approach for the treatment of rectovaginal and rectourethral fistulas.

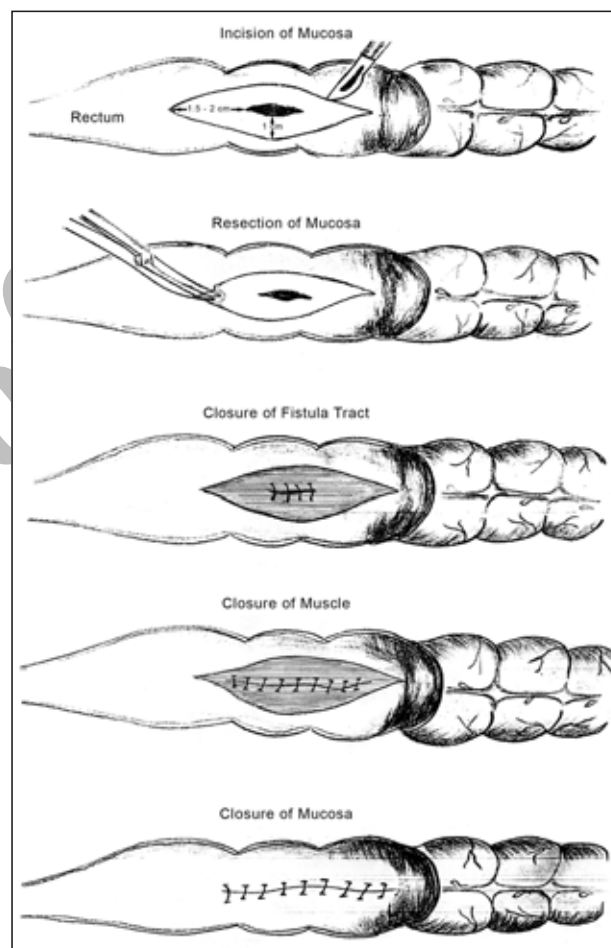
## MATERIALS AND METHODS

Between 1999 and 2006, we had 6 patients with 8 fistulas who were treated by Latzko technique. The patients' characteristics are listed in the Table. Patient 1 was referred to our center with colostomy and cystostomy. On urethroscopy and proctoscopy, 1 fistula was noted 1.5 cm in diameter 5 cm from the anal verge and another fistula, 2 cm above the first one, draining to the bulbar urethra and bladder trigone, respectively. Patient 2 had cystostomy with apparent fecaluria. On rectal examination, a rectourethral fistula 1.5 cm in diameter was discovered in the anterior rectal wall, 4 cm from the anal verge. In patient 3, cystostomy and colostomy had been done. On urethroscopy, a huge fistula (3 cm in diameter) was noted in the floor of the prostatic fossa, which was also visible through proctoscopy, 6 cm from the anal verge. In patient 3, urethroscopy revealed a fistula at the proximal bulb (1.5 cm in diameter). It was 4 cm from the anal verge on proctoscopy. In patient 4, who was a woman, 1 fistula was seen in the bladder trigone on cystoscopy, draining into the vagina, and on proctoscopy, a rectovaginal fistula (2 cm in diameter) was evident, 5 cm from the anal verge. Finally, in patient 6, a fistula, 2 cm in diameter, was seen, located 5 cm from the anal verge.

Two of the patients (patients 1 and 3) had been referred with colostomy, and for the remaining 4, we performed double-barrel colostomies 2 weeks before the reconstructive surgery. Mechanical bowel preparation was employed with irrigation through the distal part of colostomy tube until

the day of surgery. Chemical bowel preparation was performed with 4 oral doses of erythromycin and metronidazole the day before the operation.

All these patients were treated by Latzko transanal technique.<sup>(4)</sup> The patient was placed in the exaggerated lithotomy position. Afterwards, anal speculum was applied and the fistula orifice was exposed. Around the tract, a fusiform incision was made with the orifice in its center (Figure). The mucosa lying between the incision



Repair of the rectourethral and rectovaginal fistulas by the Latzko method.

Characteristics of Patients With Fistulas

Patient	Age, y	Sex	Fistula	History
1	27	Male	2 rectourethral fistulas at the floor of bulbar urethra	Tractor accident injury Extensive pelvic fracture
2	7	Male	1 rectourethral fistula to bulbar urethra	Failed operation for urethral stricture
3	66	Male	1 rectourethral fistula to prostatic urethra	Prostatectomy
4	74	Male	1 rectourethral fistula	Vigorous urethral dilatation
5	72	Female	2 vesicovaginal and rectovaginal fistulas	Colectomy and adjuvant radiotherapy
6	70	Male	1 rectourethral fistula	Prostatectomy

and the orifice was excised in the direction of the incision to the orifice, leaving the fistula edges to meet. The edges were closed by vicryl 3-0 sutures, followed by closure of the muscular layers above it. Finally, the edges of the rectal mucosa were closed (Figure). In patient 2, an appropriate speculum for his age was not accessible. Therefore, a long nasal speculum was used that created a satisfactory exposure. The colostomies were closed in all of the patients 4 to 6 weeks after the operation.

The patients were followed for a median of 44 months (11 to 94 months), and urinary and fecal continence, fecaluria, and pneumaturia were assessed regularly. Continence was defined as the absence of any need to use sanitary pads or diapers.

## RESULTS

All the fistulas were successfully repaired in all of the patients after a median follow-up period of 44 months (11 to 94 months). None of the patients reported any episodes of urinary leakage, fecaluria, or pneumaturia. Anal continence was also preserved for all of the patients. The median hospitalization period was 3 days (range, 1 to 7 days). Except for deep vein thrombosis, which occurred in the 4th patient who had a history of deep vein thrombosis too, no other major complication occurred.

## DISCUSSION

Rectourethral fistulas are not common, but occasionally occur during surgical interventions for the management of prostate diseases or urethral reconstructions. They do not usually heal spontaneously and often need surgical intervention. Various techniques have been used for the treatment of this complication including abdominal, perineal, and sometimes, mixed approaches. Few cases of transanal approaches (latzko technique) have been reported, the results of which are in accordance with ours.<sup>(3,4)</sup> Hata and colleagues reported successful treatment of rectourethral fistula in a single case,<sup>(3)</sup> and Noldus and coworkers repaired 7 fistulas of this kind in 6 patients.<sup>(4)</sup> They found transanal approach safe and effective.

Mason method has been suggested by some authors, while some have proposed a series of modifications to this method.<sup>(5,6)</sup> Some authors believe that when the rectal end of the fistula is closed, there is no need to close its vesicourethral end.<sup>(1,7-9)</sup> This has been substantiated in our small series. Garofalo and colleagues published their 20-year experience on rectal advancement flap and claimed a 100% success rate.<sup>(10)</sup> Dreznik and associates also used rectal flap in 3 of their patients with satisfactory results.<sup>(11)</sup> Visser and colleagues advocated transperineal method for the repair of rectourethral fistula. Others have used methods that are more aggressive.<sup>(12,13)</sup> Kraske method is one of the discussed methods, which follows 3 basic principles: complete separation of the urethra from the rectum, prevention from urethral injury, and sparing urinary and stool continence.<sup>(14)</sup>

It is believed that these fistulas are complicated and very difficult to repair.<sup>(1)</sup> The major point is that the first attempt to repair these fistulas is the best and subsequent attempts are not usually successful. Therefore, the first surgeon trying to repair must have the necessary expertise, should not incur further problems or complicate the situation, and should make the best decision on the treatment approach. Al-ali and colleagues reported their 30-year experience using different methods and concluded that flap advancement method with anterior approach was the best choice.<sup>(8)</sup> In some reports, abdominoperineal approach with omentoplasty has been strongly emphasized.<sup>(9)</sup> In addition to all these treatment option, this small series of transanal method bears evidence to the simplicity and safety of this technique in addition to its high success rate.

## CONCLUSION

Due to the high success rate, ease of the operation, and relatively low complication rates, we suggest that the patients with rectovaginal and rectourethral fistulas, irrelevant of the etiology (iatrogenic, traumatic, or malignancy) can be treated by transanal method as a primary procedure. Other methods such as transabdominal and perineal approaches might be better for failed surgeries. In spite of the small

current series, the very low failure rate seems promising.

### CONFLICT OF INTEREST

None declared.

### REFERENCES

1. Bukowski TP, Chakrabarty A, Powell IJ, Frontera R, Perlmutter AD, Montie JE. Acquired rectourethral fistula: methods of repair. *J Urol*. 1995;153:730-3.
2. Angioli R, Penalver M, Muzii L, et al. Guidelines of how to manage vesicovaginal fistula. *Crit Rev Oncol Hematol*. 2003;48:295-304.
3. Hata F, Yasoshima T, Kitagawa S, et al. Transanal repair of rectourethral fistula after a radical retropubic prostatectomy: report of a case. *Surg Today*. 2002;32:170-3.
4. Noldus J, Fernandez S, Huland H. Rectourinary fistula repair using the Latzko technique. *J Urol*. 1999;161:1518-20.
5. Culp OS, Calhoon HW. A variety of rectourethral fistula. Experiences with 20 cases. *J Urol*. 1964;91:560-571.
6. Renschler TD, Middleton RG. 30 years of experience with York-Mason repair of recto-urinary fistulas. *J Urol*. 2003;170:1222-5.
7. Cherr GS, Hall C, Pineau BC, Waters GS. Rectourethral fistula and massive rectal bleeding from iodine-125 prostate brachytherapy: a case report. *Am Surg*. 2001;67:131-4.
8. Al-ali M, Kashmoula D, Saoud IJ. Experience with 30 posttraumatic rectourethral fistulas: presentation of posterior transsphincteric anterior rectal wall advancement. *J Urol*. 1997;158:421-4.
9. Trippitelli A, Barbagli G, Lenzi R, Fiorelli C, Masini GC. Surgical treatment of rectourethral fistulae. *Eur Urol*. 1985;11:388-91.
10. Garofalo TE, Delaney CP, Jones SM, Remzi FH, Fazio VW. Rectal advancement flap repair of rectourethral fistula: a 20-year experience. *Dis Colon Rectum*. 2003;46:762-9.
11. Dreznik Z, Alper D, Vishne TH, Ramadan E. Rectal flap advancement—a simple and effective approach for the treatment of rectourethral fistula. *Colorectal Dis*. 2003;5:53-5.
12. Visser BC, McAninch JW, Welton ML. Rectourethral fistulae: the perineal approach. *J Am Coll Surg*. 2002;195:138-43.
13. Tiptaft RC, Motson RW, Costello AJ, Paris AM, Blandy JP. Fistulae involving rectum and urethra: the place of Parks's operations. *Br J Urol*. 1983;55:711-5.
14. Wiseman NE, Decter A. The Kraske approach to the repair of recurrent rectourethral fistula. *J Pediatr Surg*. 1982;17:342-6.