

# Laparoscopic Management of Calcified Paraganglioma of Bladder

Divya Ratna Dhawan, Arvind Ganpule, Veermani Muthu, Mahesh R Desai

Keywords: paraganglioma, pheochromocytoma, bladder neoplasms, urinary bladder, laparoscopy

Urol J. 2008;5:126-8.  
www.uj.unrc.ir

## INTRODUCTION

Paraganglioma (pheochromocytoma) of the bladder is a rare entity accounting for less than 0.5% of the bladder tumors and 1% of all pheochromocytomas.<sup>(1,2)</sup> Extra-adrenal pheochromocytoma is diagnosed in case of high suspicion, especially in bladder lesions with calcification. We report a similar case which was managed laparoscopically.

## CASE REPORT

A 26-year-old man presented with recurrent painless total gross hematuria with amorphous clots for the past 6 months, a single episode of syncopal attack 5 days prior to presentation, and occasional postmicturition headaches. He was previously diagnosed with a bladder calculus. Cystoscopy revealed an oval wide-based solid mass involving the right posterolateral bladder wall. Tissue sample was taken for histopathology examination and open surgery was contemplated, but the patient developed severe hypertension on skin incision. Therefore, the procedure was abandoned. He required intensive care and blood transfusion with assisted ventilation for 1 day. Whole body metaiodobenzylguanidine

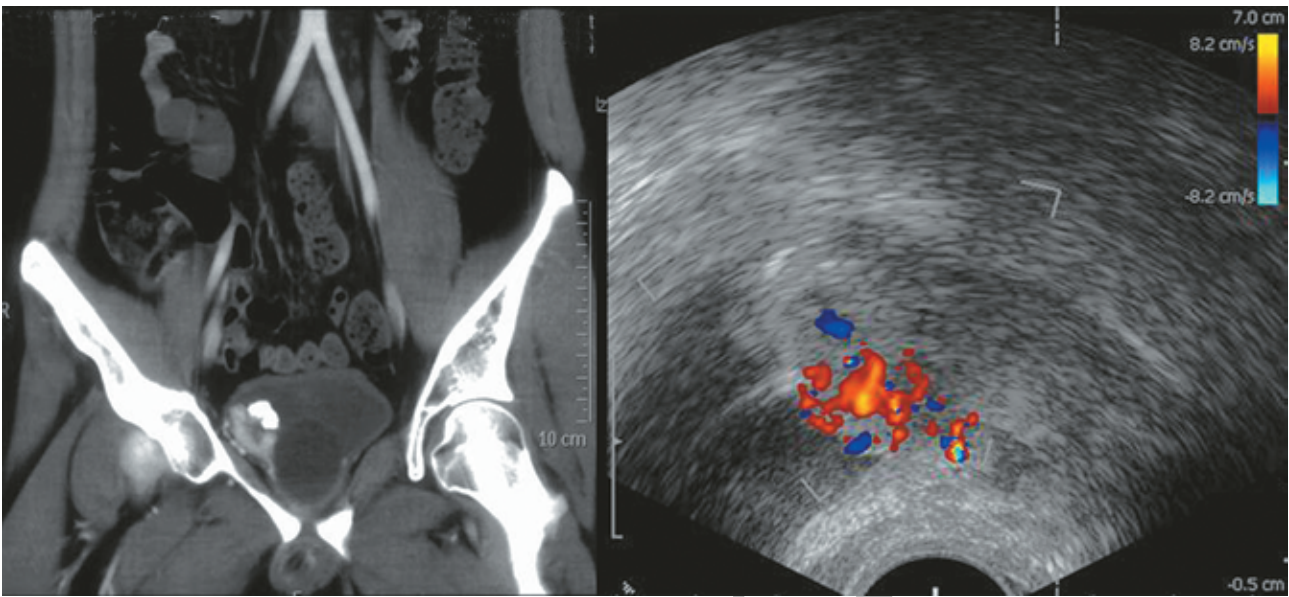
scan was normal and the 24-hour urinary value of vanillylmandelic acid was 10.7 mg (reference range, 1.5 mg to 10.6 mg). Examination of the biopsy specimen revealed paraganglioma. Abdominal radiography showed semilunar calcification in the pelvis and ultrasonography revealed a 3.4 × 2.4-cm soft tissue lesion on the right posterolateral wall of the bladder with calcification. No extravesical spread was noted on contrast-enhanced computed tomography (CT) scan. Doppler ultrasonography confirmed the extensive vascularity of the lesion (Figure 1).

The patient was prepared with long-acting alpha-blockers and beta-blockers. Five standard laparoscopic ports (three 5-mm and two 10-mm ports) were placed in fan-ray configuration. Using the laparoscopic ultrasonography, the bladder mass was delineated. Then, the bladder was partially distended by saline solution and the mass was excised with an adequate margin (Figure 2). The bladder was then closed (Figure 3) and a 20-F Foley catheter was placed periurethrally. No hypertensive crisis was observed intra-operatively. The operation lasted for 150 minutes and no blood transfusion was required. The postoperative

Department of Urology, Muljibhai Patel Urological Hospital, Nadiad, Gujarat, India

Corresponding Author:  
Mahesh R Desai, MS, FRCS, FRCS  
Department of Urology, Muljibhai Patel Urological Hospital, Dr Virendra Desai Rd, Nadiad, Gujarat, India 387001.  
Tel: +91 268 252 0323  
Fax: +91 268 252 0248  
E-mail: mrdesai@mpuh.org

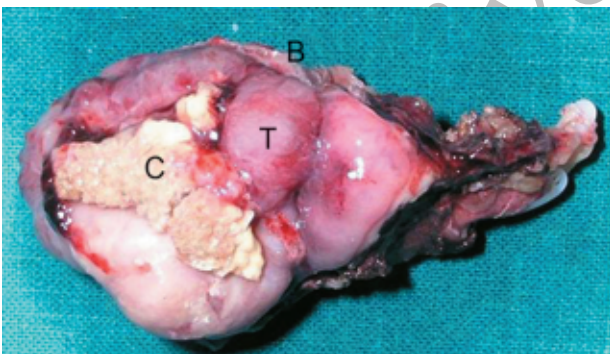
Received August 2007  
Accepted October 2007



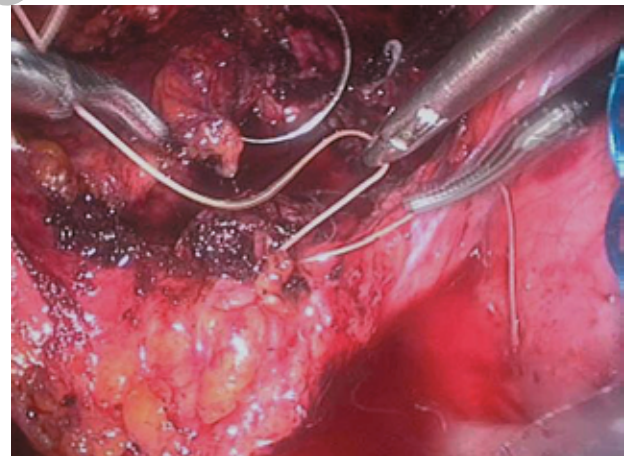
**Figure 1.** Left, Reconstructed computed tomography image shows a vesical mass with calcification. Right, Doppler ultrasonography shows high vascularity of the lesion.

recovery was unremarkable. Blood pressure returned to baseline immediately after the operation. The catheter was removed once cystography documented no leak. The 24-hour urine vanillylmandelic acid at 1 month follow-up was 5.6 mg. Histopathology and

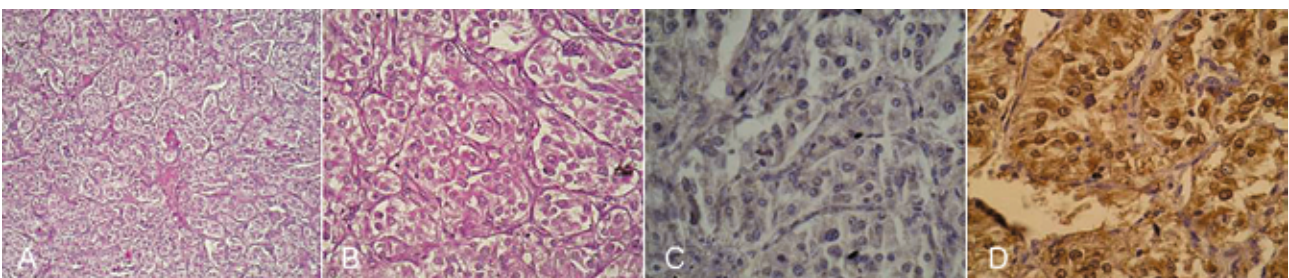
immunohistochemistry (Figure 4) confirmed the diagnosis of pheochromocytoma. At 4-month follow-up, the patient still had a normal blood pressure.



**Figure 2.** Resected specimen. C indicates calcification; T, soft tissue; and B, bladder margin.



**Figure 3.** Intraoperative view showing intracorporeal suturing after resection of the mass.



**Figure 4.** Top, Nests of spindle to polygonal cells with granular eosinophilic cytoplasm and hyperchromatic nuclei with mild pleomorphism are seen (A, hematoxylin-eosin 10; B, hematoxylin-eosin 40). C, Tumor cells were negative for cytokeratin. D, Tumor cells were positive for chromogranin.

## DISCUSSION

Vesical pheochromocytoma is a unique surgical challenge due to its presentation and potential catecholamine surge during the operative manipulation. Radiological studies, including CT scan, demonstrate ring-like calcifications of the tumor. This rare finding is suggestive of pheochromocytoma not only in the bladder but also in other sites.<sup>(3)</sup> Any bladder mass with calcification or a calculus whose position does not change should be completely evaluated with suspicion to this diagnosis. Cystoscopy may be considered when CT does not provide details. When this procedure is ignored even in patients with normal blood pressure before surgery, severe life-threatening cardiovascular complications including death can occur because of excessive catecholamine release.<sup>(4)</sup> Indiscriminate biopsy of pheochromocytomas may trigger a catastrophic crisis and must be avoided.<sup>(5)</sup>

In most cases, the diagnosis is initially missed and subsequent review of the histopathological material reveals pheochromocytoma. Transurethral resection of the tumor is not an ideal treatment since hemorrhage can be severe and uncontrollable.<sup>(3)</sup> Laparoscopic partial cystectomy for bladder pheochromocytoma has been sparingly attempted.<sup>(3,6-8)</sup> As intravesical intervention entails greater risk of catecholamine surge, solely extravesical (laparoscopic) approach and mapping of the tumor with laparoscopic ultrasonography may be a more attractive option. Shorter hospital stay, less intra-operative blood

loss, and early recovery are other advantages of the laparoscopic approach.

## CONFLICT OF INTEREST

None declared.

## REFERENCES

1. Grignon DJ. Neoplasms of the urinary bladder. In: Bostwick DG, Eble JN, editors. Urologic surgical pathology. St Louis: Mosby-Year Book; 1997. p. 214-305.
2. Singh DV, Seth A, Gupta NP, Kumar M. Calcified nonfunctional paraganglioma of the urinary bladder mistaken as bladder calculus: a diagnostic pitfall. *BJU Int.* 2000;85:1152-3.
3. Cheng L, Leibovich BC, Cheville JC, et al. Paraganglioma of the urinary bladder: can biologic potential be predicted? *Cancer.* 2000;88:844-52.
4. Samaan NA, Hickey RC, Shutts PE. Diagnosis, localization, and management of pheochromocytoma. Pitfalls and follow-up in 41 patients. *Cancer.* 1988;62:2451-60.
5. Blake MA, Kalra MK, Maher MM, et al. Pheochromocytoma: an imaging chameleon. *Radiographics.* 2004;24:S87-99.
6. Bozbora A, Barbaros U, Erbil Y, Kiliçarslan I, Yildizhan E, Ozarmagan S. Laparoscopic treatment of hypertension after micturition: Bladder pheochromocytoma. *JLS.* 2006;10:263-6.
7. Dilbaz B, Bayoglu Y, Oral S, Cavusoglu D, Uluoglu O, Dilbaz S. Laparoscopic resection of urinary bladder paraganglioma: a case report. *Surg Laparosc Endosc Percutan Tech.* 2006;16:58-61.
8. [No authors listed]. Combined laparoscopic and transurethral partial cystectomy for juxta-ureteral pheochromocytoma of the bladder. *Minim Invasive Ther Allied Technol.* 2002;11:19-22.