

Relapse of Acute Myeloid Leukemia as Isolated Bilateral Testicular Granulocytic Sarcoma in an Adult

Mojtaba Ghadiany,¹ Hamid Attarian,¹ Abbas Hajifathali,¹ Adnan Khosravi,¹ Saatat Molanaee²

Keywords: acute myeloid leukemia, bone marrow, myeloid sarcoma, recurrence

Urol J. 2008;5:132-5.
www.uj.unrc.ir

INTRODUCTION

Acute myeloid leukemia (AML) is a malignant hematologic disease characterized by bone marrow infiltration with leukemic (blast) cells. Infiltration of extramedullary organs by these cells is called granulocytic sarcoma (GS). Relapsed AML with isolated testicular GS without bone marrow involvement is very rare and only a few cases have been reported.^(1,2) We report a case of AML that relapsed as isolated bilateral testicular GS, 6.5 years after initial remission was induced by chemotherapy.

CASE REPORT

The patient was a 45-year-old man who presented with weakness in 1997. Initial laboratory examination showed a leukocyte count of $9.2 \times 10^9/L$; hemoglobin, 6.2 g/dL; and platelet count, less than $10 \times 10^9/L$. Bone marrow examination was indicative of more than 50% blasts of myeloid lineage and few Auer rods. Flow cytometry analysis confirmed AML by the following findings: CD45, 79.6%; CD3= 19.2%; CD20, 3%; CD13, 22%; CD33, 1.2%; human leukocyte antigen-DR, 64.7%; and CD34, 65.2%.

Cytogenetic study was not available.

The patient received induction chemotherapy (daunorubicin for 3 days plus cytarabine for 7 days), and complete remission was achieved. Then, he received 2 courses of chemotherapy as consolidation. He was in complete remission for 6.5 years, but in 2003, he noticed enlargement of his left testis. Therefore, he was referred to our hematology clinic. Physical examination was unremarkable except for bilateral testicular enlargement. The left testis was about 6 cm large, firm, and with a smooth surface. The right testis was a little smaller. Ultrasonography, done a month earlier, had shown that the left testis sized 4.5×3.5 cm and diffusely hypoechoic, and the right testis sized 4.0×2.7 cm with a hypoechoic mass inside. The complete blood count, beta-human chorionic gonadotropin, alpha-fetoprotein, and lactate dehydrogenase were all within normal limits. Bone marrow aspiration and biopsy showed no evidence of systemic relapse.

We did not have the facility to do immunohistochemistry examination on fine-needle

¹Department of Medical Oncology and Hematology, Taleghani Hospital, Shahid Beheshti University (MC), Tehran, Iran

²Department of Pathology, Milad Hospital, Tehran, Iran

Correspondence Author:
Mojtaba Ghadiany, MD
Taleghani Teaching Hospital,
Velenjak, Tehran, Iran
Tel: +98 21 8804 7999
E-mail: mghadiany@taleghanihospital.ir

Received April 2007
Accepted September 2007

aspiration samples. Therefore, left radical orchiectomy was done. Gross pathologic evaluation of the testis showed that it was $7.5 \times 5.5 \times 3.0$ cm, about 120 g, creamy in appearance, firm, and hemorrhagic and necrotic in some regions. On microscopic examination, the testicular tissue was infiltrated by mononuclear cells with vesicular and prominent nucleoli, some of which showed myelocytic differentiation compatible with GS (Figure 1). Two other pathologists reviewed the specimens and confirmed the diagnosis of GS. Immunohistochemistry (positive for leukocyte common antigen, CD34, CD43, c-kit, and myeloperoxidase, but negative for CD3) confirmed the above diagnosis (Figure 2).

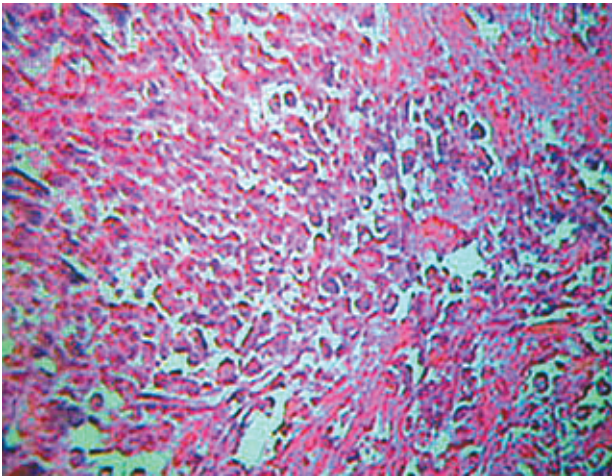


Figure 1. Diffuse infiltration of the testis with intermediate-sized cells and small nucleoli with a high-mitotic rate (hematoxylin-eosin, $\times 40$).

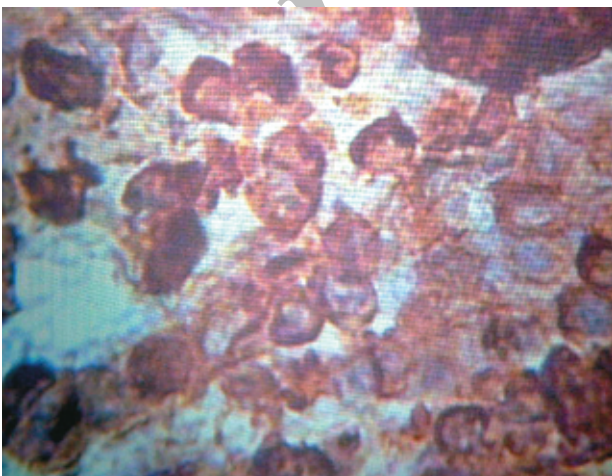


Figure 2. Expression of myeloperoxidase in most of the cells (histochemistry, $\times 100$).

Myeloperoxidase was repeated in another center and was positive. Cerebrospinal fluid was intact.

For editorial comment see p 134

Radiotherapy consultation was done and the right testis was radiated. At the end of radiotherapy, because of abdominal pain, computed tomography (CT) was ordered which showed massive multiple para-aortic lymphadenopathy plus left-side hydronephrosis. Induction chemotherapy with idarubicin plus cytarabine was started and followed by 4 cycles of high-dose cytarabine. Abdominal CT which was repeated after chemotherapy showed normal pattern without any residue. Hepatitis B surface antigen was positive; hence, bone marrow transplantation was not considered. During a 3.5-year follow-up after relapse, the patient was still in complete remission.

DISCUSSION

In 1975, Schiffer and colleagues reported a case of AML relapsed with isolated GS of the testis 4 months after complete remission by radiotherapy plus systemic chemotherapy with dounorobicine. The patient died 7 months after relapse.⁽³⁾ Litam and colleagues reported a 63-year-old man who had completed induction and intensification chemotherapy whose cancer relapsed as isolated unilateral testicular enlargement. Biopsy confirmed infiltration of acute monocytic leukemia.⁽²⁾ This case relapsed 1 month after complete remission, which was treated by radiotherapy without chemotherapy. However, the patient died 10 days after diagnosis of relapse.⁽²⁾

According to Shaffer and coworkers, testicular relapse in the absence of systemic relapse has been reported only in 2 adults and 12 children until 1992.⁽¹⁾ They reported a case that relapsed 2 months after hematologic remission. The patient denied chemotherapy and received only radiation to his testis. He died after 3 months with systemic relapse.⁽¹⁾ Testicular granulocytic sarcoma in a patient with acute

megakaryoblastic leukemia has also been reported.⁽⁴⁾ The patient in this case was in complete remission for 4 months before his relapse in left testis.

Relapse of AML as isolated testicular GS after initial full hematologic remission induced by chemotherapy is very rare. In the previous cases, the time between remission and testicular relapse (relapse-free time) was only few months, and testicular relapse was usually followed by bone marrow relapse. In our case, however, the relapse-free time was 6.5 years, and to our knowledge, this is the longest interval so far reported. Our case presented by bilateral testicular enlargement without any other symptom, but abdominal pain that appeared just after radiation suggests disease progression during radiotherapy. Therefore, we think chemotherapy should be started as soon as possible during or even before radiotherapy for prevention of disease progression. Detection of para-aortic lymphadenopathy tells us computed tomography should have been done before starting treatment. Although most reported had a short survival, our patient, being alive after 3.5 years without any evidence of relapse, is the evidence of long-term survival by chemoradiation therapy.

CONFLICT OF INTEREST

None declared.

REFERENCES

1. Shaffer DW, Burris HA, O'Rourke TJ. Testicular relapse in adult acute myelogenous leukemia. *Cancer*. 1992;70:1541-4.
2. Litam PP, Koller CA, McCredie KB. Relapse of adult acute myelogenous leukemia isolated in testicle. *Tex Med*. 1989;85:36-8.
3. Schiffer CA, Sanel FT, Stechmiller BK, Wiernik PH. Functional and morphologic characteristics of the leukemic cells of a patient with acute monocytic leukemia: correlation with clinical features. *Blood*. 1975;46:17-26.
4. Sastre JL, Ulibarrena C, Armesto A, et al. [Testicular granulocytic sarcoma as a form of relapse in a patient with acute megakaryoblastic leukemia]. *Sangre (Barc)*. 1998;43:248-50. Spanish

EDITORIAL COMMENT

Granulocytic sarcoma (GS) is a localized extramedullary tumor composed of immature myeloid cells. The common sites of involvement are the bone, orbit, periosteum, soft tissue, lymph nodes, and skin. It is a rare primary manifestation of acute myeloid leukemia (AML), blastic transformation of chronic myeloid leukemia, and myelodysplastic syndromes.⁽¹⁾ Granulocytic sarcoma of the testis is rare and has a poor prognosis. It develops in 2% to 8% of patients with AML.⁽²⁾ Granulocytic sarcoma may present independently of, precede, or develop concurrently with AML. Although some patients present with localized disease (such as the presented case by Ghadiany and colleagues), GS should be considered a systemic process because recurrence and progression are common. Cytogenetic study has an important prognostic role in GS complicating adult AML. Unfortunately, in the presented case, this study has not been done. The most common cytogenetic findings in GS complicating adult AML have been t(8;21)(q22;q22) and inv(16)(p13q22).⁽¹⁾ Patients with tetraploid karyotype have a very poor prognosis, compatible with the very aggressive course of the disease. That patient presented with unilateral testicular enlargement, but physical examination revealed bilateral testicular enlargement. Although it is an extremely rare entity, extramedullary myeloid cell tumors must be considered in the differential diagnosis of unilateral testicular masses in patients with myelodysplastic/myeloproliferative disease. Testicular relapse often heralds subsequent bone marrow relapse or other extramedullary relapse, as this occurred in this case.

Diagnosis of testicular GS is difficult. Biopsy, but not necessarily complete excision, is appropriate for diagnosis. Granulocytic sarcoma is easily confused with non-Hodgkin lymphoma because of the morphologic similarities of the blasts to large cell lymphoma, the presence of lymphoglandular bodies, and the rarity of Auer rods and eosinophilic myelocytes.⁽³⁾ Immunohistochemical examination can be diagnostic, as it has been done in the presented case. Immunophenotyping of bone marrow

mononuclear cells by flow cytometry reveals positive CD45, CD34, human leukocyte antigen-DR, and CD7 blast cells expressing the myeloid markers CD13, CD33, and myeloperoxidase. The treatment of GS with or without associated AML should involve intensive systemic chemotherapy with radiation.

Mohammad Reza Safarinejad
Associate Editor, *Urology Journal*

REFERENCES

1. Byrd JC, Edenfield WJ, Shields DJ, Dawson NA. Extramedullary myeloid cell tumors in acute nonlymphocytic leukemia: a clinical review. *J Clin Oncol.* 1995;13:1800-16.
2. Economopoulos T, Alexopoulos C, Anagnostou D, et al. Primary granulocytic sarcoma of the testis. *Leukemia.* 1994;8:199-200.
3. Suh YK, Shin HJ. Fine needle aspiration biopsy of granulocytic sarcoma: a clinicopathologic study of 27 cases. *Cancer.* 2000;90:364-72.

Archive of SID