

Bilateral Segmental Renal Artery Thrombosis from Blunt Abdominal Trauma: A Rare Presentation

Phitsanu Mahawong,¹ Tanop Srisuwan²

¹ Division of Urology, Department of Surgery, Faculty of Medicine, Chiang Mai University, Chiang Mai 50200, Thailand

² Division of Diagnostic Radiology, Department of Radiology, Faculty of Medicine, Chiang Mai University, Chiang Mai 50200, Thailand

Corresponding author:

Phitsanu Mahawong, M.D.
Division of Urology, Department of Surgery Faculty of Medicine, Chiang Mai University
110 Intawaroros Road, Sripoom, Muang, Chiang Mai 50200, Thailand.

Tel: +66 53 945 532
Fax: +66 53 946 139

E-mail: pmahawon@med.cmu.ac.th

Received August 2011
Accepted April 2012

Keywords: renal artery obstruction; thrombosis; wounds; nonpenetrating; abdominal injuries.

INTRODUCTION

The incidence of renal injury in a normal population is 4.8% and renovascular injuries comprise 4% of all renal injuries.⁽¹⁾ Segmental renal artery injury is not uncommon in blunt abdominal trauma and most of them can be conservatively managed.⁽²⁾ There are some reports about unilateral segmental renal artery thrombosis (SRAT) but there are no reports of bilateral SRAT.⁽³⁾ We will demonstrate the present case and discuss about treatment options.

CASE REPORT

The patient was a previously healthy 19-year old male with a history of blunt abdominal trauma from a motorcycle accident 15 minutes prior to admission. The patient could not remember the events of the accident because he had drunk a lot of alcohol. In our Trauma Center, the Glasgow Coma Scale (GCS) of the patient was 15. Initial blood pressure was 80/50 mmHg and then rose to 120/60 mmHg after fluid resuscitation with 2000 ml of normal saline solution. The heart rate was 90 beats per minute and the respiratory rate was normal. Abdomen was generally distended, and guarded. Swelling of the left wrist was detected and a pelvic compression test was positive. Tenderness at the lower thoracic spines without stepping was demonstrated. Focused abdominal ultrasonography for trauma was performed and its finding was equivocal. Fractures of the left distal radius, and the left superior pubic rami

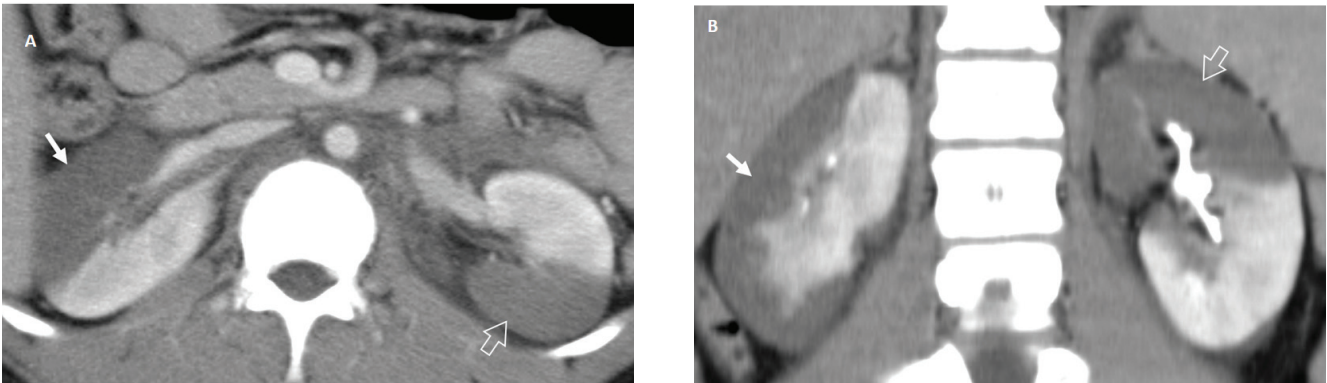


Figure 1. Segmental renal infarction of both kidneys. Enhanced CT scan in nephrographic phase in axial view (A) and excretory phase in coronal view (B) demonstrate the sharply defined area of unenhanced parenchyma of the anterior right renal (arrow) and posterior left renal parenchyma (blank arrow). Minimal retroperitoneal hematoma around the paraaortic region is noted.

were revealed. Gross hematuria was seen in the Foley catheter after urethral catheterization.

Laboratory studies showed the hemoglobin level of 8.4 gm/dL and the hematocrit level was 26.5%. The leukocyte count was 20 200/ μ L (predominantly neutrophils) and the platelet count was normal. Blood urea and creatinine levels were 19 mg/dL, 2.7 mg/dL respectively. An abdominal computed tomography (CT) scan demonstrated minimal retroperitoneal hematoma around the paraaortic region with infarction of the right anterior renal and left posterior renal parenchyma (Figure 1). These findings indicated the diagnosis of right anterior SRAT and left posterior SRAT.

Due to a renal insufficiency, an early diagnosis of bilateral SRAT, and the young age of the patient, we did not choose a conservative treatment. The patient underwent exploratory laparotomy 3 hours after diagnosis. The right anterior SRAT was found (Figure 2). Thrombectomy was done along with segmental resection and end to end anastomosis with Prolene 6-0 was performed (Figure 3). The left posterior SRAT was corrected the same way as the right one. The areas of infarction in both kidneys were slightly decreased right after revascularization. The operative time was 270 minutes and estimated blood loss was 500 mL. Clamp time of the right anterior and left posterior segmental arteries were 45 and 30 minutes, consecutively.

Renal function and urine output were closely monitored after surgery. At the 3 month follow up, blood urea and creatinine were 15 mg/dL, 1.6 mg/dL, respectively. Abdominal CT scan and renal scan were planned but the patient refused any imaging and all follow up appointments after that.

DISCUSSION

Treatment of unilateral SRAT with normal contralateral kidney is not controversial. Most patients are hemodynamically stable or may be asymptomatic. Hypertension occurs in less than 10 % of traumatic unilateral SRAT. Unilateral SRAT initially should be managed nonoperatively.⁽³⁾ On the other hand, late hypertension is found in 50% of patients with main renal artery thrombosis (MRAT) when managed conservatively.⁽⁴⁾ Excision of ischemic parenchyma in SRAT is indicated only when intractable hypertension associated with increased renin secretion can be identified.⁽⁵⁾ MRAT in a solitary kidney is rare and most of them are not caused from blunt external trauma.⁽⁶⁾ Their treatments are percutaneous revascularization or open endarterectomy.⁽⁷⁾ Traumatic bilateral MRAT is also uncommon. A high index of suspicion, early diagnosis, and prompt revascularization are essential in obtaining optimal results without hypertension or permanent impairment of renal function.^(8,9)

To the best of our knowledge, the present case is the first

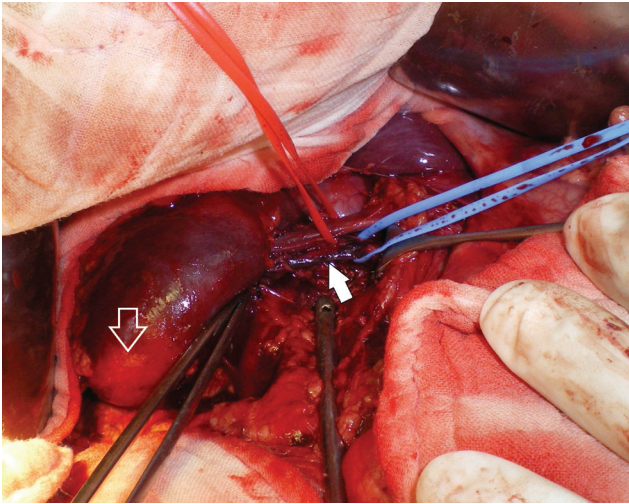


Figure 2. Intraoperative finding: the right anterior segmental renal artery thrombosis is identified (arrow). Demarcation of the right anterior renal parenchymal infarction (blank arrow).

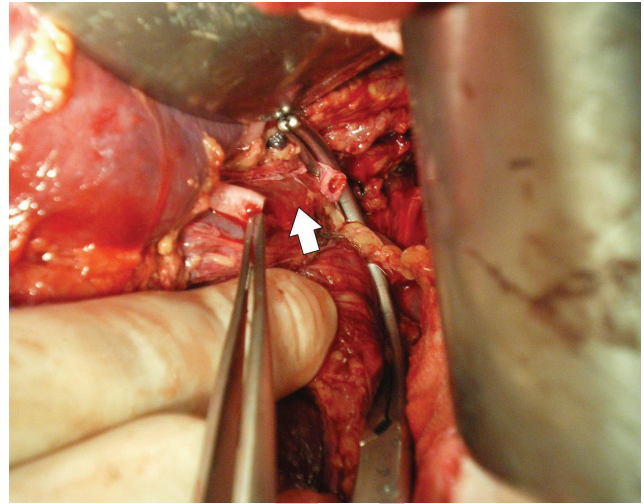


Figure 3. Both ends of the right anterior segmental renal artery before end to end anastomosis (arrow).

reported case of bilateral SRAT from blunt abdominal trauma in literature. Bilateral SRAT as the present case poses a unique consideration to treatment because they cause ischemia to the right anterior and the left posterior renal parenchyma. The rest of overall renal function may be equal to renal function of only one kidney. If the patient was unstable from other injuries, we must correct the causes of the hemodynamic instability, first. The further kidneys exploration may be warranted when the patient has normal and the renal ischemic time is less than 12 hours. Although, we tried to counteract the ischemic parenchyma by bilateral open thrombectomies and revascularizations, the serum creatinine was not completely normal at the 3 month follow up. Nowadays, we still do not know the most appropriate treatment for bilateral SRAT as in the reported case because of the rarity of this condition.

CONFLICT OF INTEREST

None declared.

REFERENCES

1. Wessells H, Suh D, Porter JR, et al. Renal injury and operative management in the United States: results of a population-based study. *J Trauma*. 2003;54:423-30
2. Elliott SP, Olweny EO, McAninch JW. Renal arterial injuries: a single center analysis of management strategies and outcomes. *J Urol*. 2007;178:2451-5.
3. Cass AS, Luxenberg M. Traumatic thrombosis of a segmental branch of the renal artery. *J Urol*. 1987;137:1115-6.
4. Cass AS. Renovascular injuries from external trauma. Diagnosis, treatment, and outcome. *Urol Clin North Am*. 1989;16:213-20.
5. Bertini JE Jr, Flechner SM, Miller P, Ben-Menachem Y, Fischer RP. The natural history of traumatic branch renal artery injury. *J Urol*. 1986;135:228-30.
6. Mbanugo C, Grey DP, Moss R, Orloff G. Thrombosis of the renal artery of a small, solitary kidney: successful return of renal function after prolonged anuria. *Tex Heart Inst J*. 1988;15:121-3.
7. Bessias N, Sfyroeras G, Moulakakis KG, Karakasis F, Ferentinou E, Andrikopoulos V. Renal artery thrombosis caused by stent fracture in a single kidney patient. *J Endovasc Ther*. 2005;12:516-20.
8. Klink BK, Sutherin S, Heyse P, McCarthy MC. Traumatic bilateral renal artery thrombosis diagnosed by computed tomography with successful revascularization: case report. *J Trauma*. 1992;32:259-62.
9. Letsou GV, Gusberg R. Isolated bilateral renal artery thrombosis: an unusual consequence of blunt abdominal trauma—case report. *J Trauma*. 1990;30:509-11.