

# Pneumovesicoscopy: An Effective Technique for Urinary Bladder Foreign Body

Pandey Praveen Kumar, Shukla Suruchi, Bera Malay Kumar, Sharma Pramod Kumar, Singh Jitendra Pratap

Department of Urology, IPGME & R,  
Kolkata-700020, India.

Corresponding author:

Pandey Praveen Kumar, MD  
Department of Urology, IPGME &  
R and S.S.K.M. Hospital, 244, A.J.C.  
Bose Road, Kolkata-700020, India.

Tel: +91 995 393 1506

E-mail: drpandeypraveen@gmail.  
com

Received October 2011  
Accepted November 2012

**Keywords:** foreign bodies; urinary bladder; emergency service; cystoscopy; therapy.

## INTRODUCTION

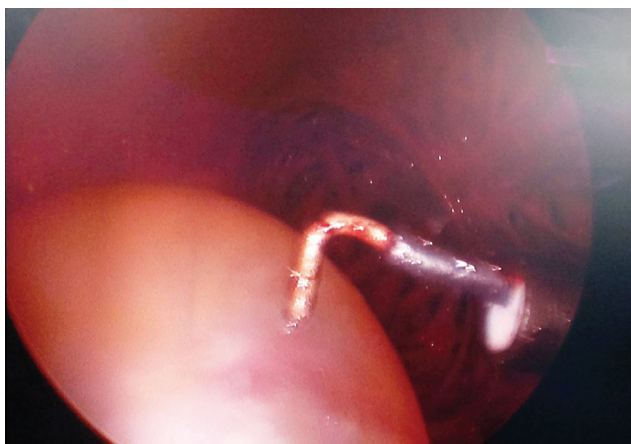
Foreign bodies in urinary bladder could be of various origins but are more commonly noted as an attempt to achieve sexual gratification, in psychiatric patients and as complication of various surgical procedures. Here we present a case of retained cut end of Foleys catheter in urinary bladder of a patient suffering from lower urinary tract symptoms.

## CASE REPORT

A 52-year old man with benign prostatic hyperplasia presented to us with retained cut end of a Foleys catheter with inflated bulb in his urinary bladder. He was catheterized for one month and the bulb could not be deflated as the catheter was due for change. In a hospital, an attempt was made to deflate the bulb. Accidentally, Foleys catheter was cut and distal end with the inflated bulb was pushed into the urinary bladder.

## TECHNIQUE

On examination urinary bladder was palpable. At first, a suprapubic ultrasound guided approach was attempted to puncture the bulb but failed. Subsequently cystoscopic examination was done. The catheter was long due for change and bulb was resistant to puncture by optical internal urethrotomy knife or Kollins knife. Finally a 10 mm laparoscopy port was introduced in the bladder using cystoscopic guidance and pneumovesicum was created under spinal anesthesia. A laparoscopic hook was used to puncture the balloon (Figure) and cut end



**Figure 1.** Laparoscopic hook being used to puncture the balloon of Foleys catheter.

of Foleys catheter was removed. The 10 mm port facilitated the removal of foreign body using non tooth forceps. A final cystoscopic examination was performed after removal of laparoscopic port. The port site was closed and the patient catheterized per urethra.

## DISCUSSION

Intravesical foreign body is not an uncommon entity in surgical practice. Usually, these foreign bodies may be self introduced, result of a penetrating injury or complication of a surgical procedure.<sup>(1)</sup> The most common objective for introduction of these foreign bodies is to achieve sexual gratification. It may be complication of an attempt to induce abortion. Surgery in anatomical surrounding areas can also lead to migration of some prosthesis or suture materials in urinary bladder.<sup>(2)</sup> The foreign bodies may include Intra uterine devices, artificial urinary sphincter, prosthetic slings, non absorbable sutures used in incontinence surgeries and clips used in laparoscopic urological or gynecological surgeries.<sup>(3)</sup> Fragments of endoscopic instruments are the most common iatrogenic intravesical foreign bodies due to urological procedures.<sup>(4)</sup>

Apart from these iatrogenic foreign bodies other objects reported are long wires, glass rods, bottles, batteries, pencils, plastic tubes, thermometers and even passage of a leech into the urinary bladder per urethra during bathing in ponds.

These patients may present with acute or chronic symptoms. But there could be complete absence of symptoms in some cases. However, such patients may also present for the first time with a vesical calculus. Diagnosis can be made with a kidney ureter bladder (KUB) radiograph or else by an ultrasound of KUB region. Finally a cystoscopic examination may be done. Different techniques have been described to retrieve retained catheter tip of an inflated Foley catheter's bulb. These include per urethral removal using urethrotome knife or hypodermic needle to puncture the bulb.<sup>(5)</sup> There have been reports of pneumovesicoscopy for failed cases.<sup>(6)</sup> A pneumovesicum is created after placing ports in urinary bladder under cystoscopic guidance which was done in this case. Foreign body may be removed in pieces or en mass using laparoscopic forceps. Finally, an open surgery may be required in failed cases. In conclusion, pneumovesicoscopy could be a viable option for retrieval of an intravesical foreign body after failure of much advocated transurethral approach.

## CONFLICT OF INTEREST

None declared.

## REFERENCES

1. Pal DK, Bag AK. Intravesical wire as foreign body in urinary bladder. *Int Braz J Urol.* 2005;31:472-4.
2. Padmanabhan P, Hutchinson RC, Reynolds WS, Kaufman M, Scarpero HM, Dmochowski RR. Approach to management of iatrogenic foreign bodies of the lower urinary tract following reconstructive pelvic surgery. *J Urol.* 2012;187:1685-90.
3. Cardozo L. Recurrent intra-vesical foreign bodies. *Br J Urol.* 1997;80:687
4. Prasad S, Smith AM, Uson A, Melicow M, Lattimer JK. Foreign bodies in urinary bladder. *Urology.* 1973;2:258-64.
5. Hemal AK, Taneja R, Sharma RK, Wadhwa SN. Unusual foreign body in urinary bladder: points of technique for their retrieval. *Eastern J Med.* 1998;3:30- 31.
6. Ko YH, Kang SG, Kang SH, et al. Removal of long, complex foreign bodies from bladder using single laparoscopic port under pneumovesicum. *J Laparoendosc Adv Surg Tech A.* 2010;20:639-42