

# Treatment of Juxtaglomerular Cell Tumor of the Kidney by Retroperitoneal Laparoscopic Partial Nephrectomy

Zhi Chen,<sup>1</sup> Zheng-Yan Tang,<sup>1</sup> Hai-Tao Liu,<sup>2</sup> Xiang Chen<sup>1</sup>

<sup>1</sup>Department of Urology, Xiangya Hospital, Central South University, Hunan Province, China.

<sup>2</sup>Department of Urology, Second Affiliated Hospital, Hunan University of Traditional Chinese Medicine, Hunan Province, China.

Corresponding author:

Xiang Chen, MD  
Department of Urology, Xiangya Hospital, Central South University, No. 87 Xiangya Road, Changsha, 410008, China

Tel: +86 0138 7480 8998  
Fax: +86 731 8432 7354

E-mail: cxiang1007@126.com

Received October 2011  
Accepted April 2012

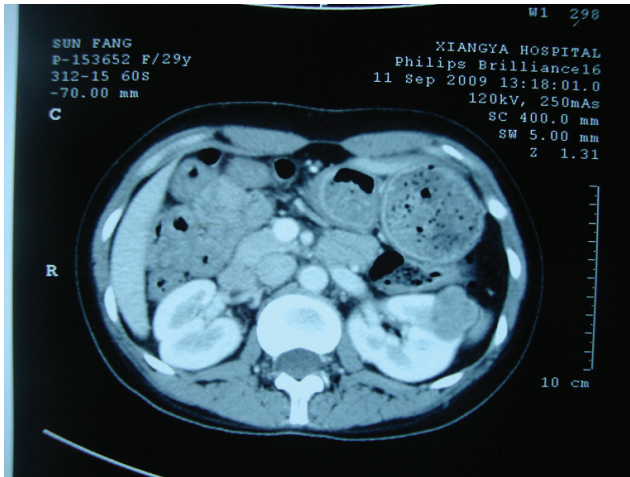
**Keywords:** kidney neoplasms; laparoscopy; juxtaglomerular apparatus; renin; laparoscopy; retroperitoneal space.

## INTRODUCTION

Juxtaglomerular cell tumor (JCT) of the kidney, first described by Robertson and colleagues in 1967,<sup>(1)</sup> is a rare cause of severe hypertension. Because the tumor is small, mainly occurs in children and young adults, and has benign nature, nephron-sparing surgery is particularly recommended.<sup>(2)</sup> Here we present for the first time a case of JCT in a 29-year old woman who underwent retroperitoneal laparoscopic partial nephrectomy.

## CASE REPORT

A 29-year old woman presented with a history of headache, polyuria, nocturia, and blurred vision. Her blood pressure was 190/120 mmHg and had hypokalemia (2.9 mmol/L). Blood urea and creatinine and 24-hour urinary vanillyl mandelic acid (VMA) levels were all normal. Ultrasonography revealed a hypoechoic 2 × 3 cm mass in the left kidney. Contrast-enhanced computed tomography (CT) of the abdomen documented a 2 × 3cm hypo enhancing, solitary, well-circumscribed mass lesion in the anterior aspect of the middle pole of the left kidney (Figure 1). Serum levels of plasma renin activity (PRA) and aldosterone (ALD) were high in supine and upright position (PRA 7.3 µg/L/h vs. 8.9 µg/L/h and ALD 258.1 pmol/L vs. 443.7 pmol/L, respectively). Renal venous sampling for renin assay was performed. The ratio of left kidney to right kidney was 1.7. Considering the small peripheral lesion, retroperitoneal laparoscopic partial nephrectomy was performed. The operative time was 145 min and the warm ischemic time was 29 min. The estimated blood loss was 80 mL. The hospital

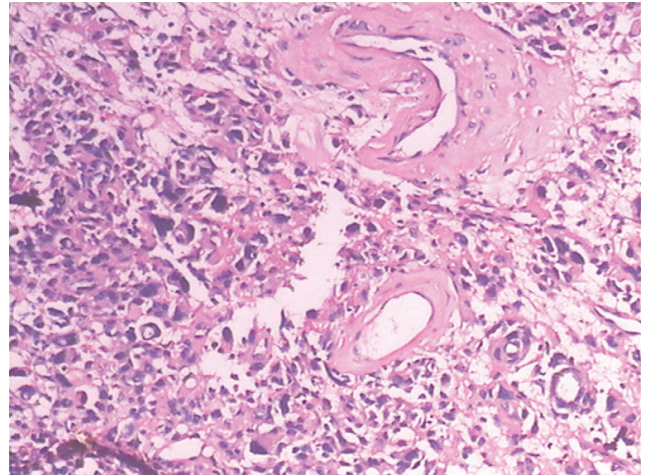


**Figure 1.** Contrast-enhanced computed tomography scan shows a 2 × 3cm hypo enhancing, solitary, well circumscribed mass lesion in the anterior aspect of the middle pole of the left kidney.

stay was 3 days. No intraoperative and postoperative complication occurred. The pre- and postoperative serum creatinine levels were 1.38 mg/dL and 1.45 mg/dL, respectively. The pathological findings confirmed the diagnosis of a JCT (Figure 2). Her blood pressure returned to normal without medical treatment postoperatively. Hypokalemia has also resolved. She was alive without evidence of recurrence 25 months after surgery.

## DISCUSSION

The definitive treatment for JCT is surgical excision.<sup>(3)</sup> To our knowledge, no case of JCT of the kidney treated by retroperitoneal laparoscopic partial nephrectomy has been reported to date. The retroperitoneal approach for JCT of kidney offers various obvious advantages. It provides a direct and rapid approach to kidney and renal hilum, allows the renal artery to be dissected directly without the retraction of the vein, there is closer proximity to the conventional open approach, provides the advantage of easier management of post-operative complication such as urine leakage or bleeding, and offers an alternative to the patients with previous transperitoneal surgery. Furthermore, our previously extensive experience with many retroperitoneal laparoscopic procedures also contributed to the choice of the retroperito-



**Figure 2.** The pathological examination shows that the tumor cells consist of clusters of polygonal cells, with a moderate amount of eosinophilic cytoplasm and centrally located nuclei. There is a prominent vessels under light microscope. (Hematoxylin-eosin × 400).

neal approach for JCT.<sup>(4)</sup>

In conclusion, this case suggested that retroperitoneal laparoscopic partial nephrectomy is a safe and feasible procedure for JCT of the kidney.

## ACKNOWLEDGMENT

Zhi Chen and Zheng-Yan Tang contributed equally to this work.

## CONFLICT OF INTEREST

None declared.

## REFERENCES

1. Robertson PW, Klidjian A, Harding LK, Walters G, Lee MR, Robb-Smith AH. Hypertension due to a renin-secreting renal tumour. *Am J Med.* 1967;43:963-76.
2. Mete UK, Niranjan J, Kusum J, Rajesh LS, Goswami AK, Sharma SK. Reninoma treated with nephron-sparing surgery. *Urology.* 2003;61:1259-59.
3. Feliciotti F, Campagnacci R, Perretta S, et al. Laparoscopic resection of a juxtaglomerular cell tumor of the right kidney. *Surg Endosc.* 2002;16:539.
4. Chen Z, Chen X, Luo YC, He Y, Li NN, Wu ZH. Retroperitoneoscopic Decortication of Symptomatic Peripelvic Renal Cysts: Chinese Experience. *Urology.* 2011;78:803-7.