

Renal Cell Carcinoma Dwelling Upon a Renal Cyst Wall and Laparoscopic Management

Yaşar Özgök,¹ Mutlu Ateş,¹ Mustafa Burak Hoşcan,² Okan İstanbulluoğlu,¹ Şeref Başal,¹ Murat Zor¹

¹ Department of Urology, Gülhane Military Medical Academy, Ankara, Turkey

² Department of Urology, Baskent University, Alanya Research and Practice Center, Alanya-Antalya, Turkey

Corresponding author:

Mustafa Burak Hoşcan, MD
Department of Urology, Baskent University, Alanya Research and Practice Center, 07400 Alanya-Antalya, Turkey.

Tel: +90 532 436 4855
Fax: +90 242 511 2350

E-mail: drburakhoscan@yahoo.com

Received November 2011
Accepted January 2012

Keywords: renal cell carcinoma; cysts; therapy; laparoscopy; kidney diseases.

INTRODUCTION

Simple renal cysts are mostly benign and asymptomatic disease and managed conservatively. Renal cell carcinomas (RCC) sometimes presents as a cystic tumor. At least 4-15 % of renal tumors encountered are cyst-associated renal cell carcinoma (CRCC).⁽¹⁾ Findings suggestive of malignancy in a renal cyst include thickened, irregular or smooth walls or septa, and enhancement after contrast injection.⁽²⁾ Some cystic RCC are known to arise from simple renal cysts. Transformation of a simple renal cyst into RCC, however, is extremely rare.^(1,3) According to our knowledge no reports have demonstrated a clinical course of RCC dwelling upon a renal cyst wall (or localized at outer side of cyst wall). We describe a laparoscopic decortication of a simple renal cyst with an overlaying RCC.

CASE REPORT

A 70-year old man was found to have a mass dwelling upon a right inferior pole 6 cm renal cyst on computed tomography (CT), in June 2008 with a past history of local-advanced prostate cancer treated with radiotherapy and hormone therapy in 2004. The cyst was categorized as Bosniak type 1 by CT when it was first diagnosed. Three years later, ultrasonography (USG) showed septations in the cyst but none of the USG was able to reveal a mass until June 2008 (Figures 1A and 1B). The cyst has been followed as a simple renal cyst. Thereafter a cystic lesion with a contrast enhancing solid focus was revealed by CT 4 years after the first diagnose. Laboratory examinations including serum chemistry and urine analyze were within

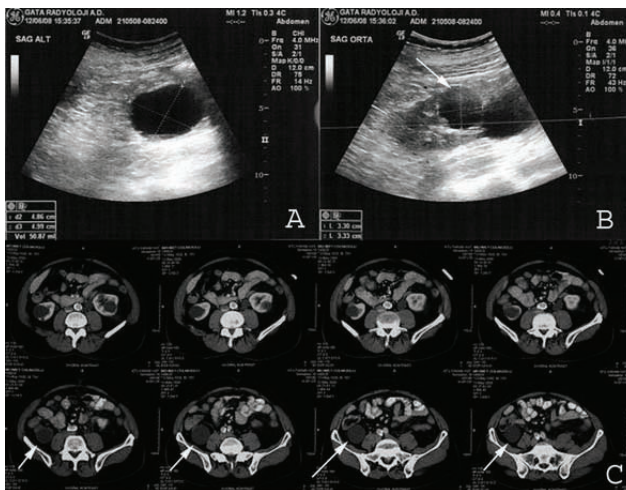


Figure 1. Preoperative ultrasound (A and B) and computed tomography (C) imaging of the cyst. (Arrows show the cystic lesion).

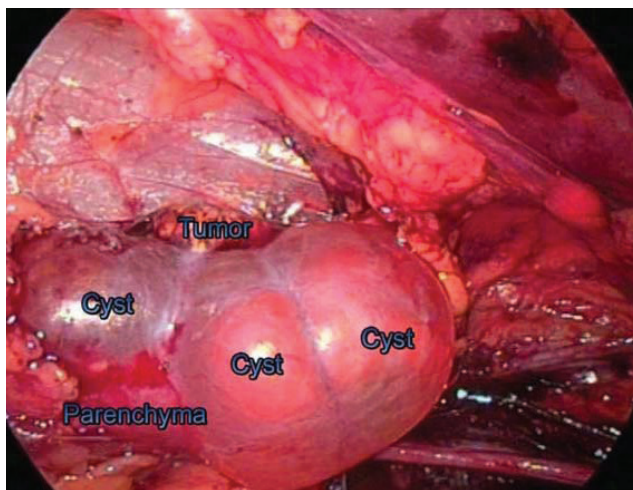


Figure 2. Tumor overlaying on the cyst wall (operative field).

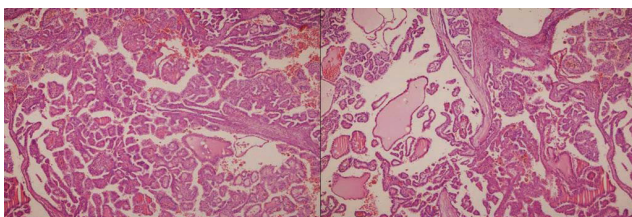


Figure 2. Histopathological image of normal cyst tissue and the tumor.

normal limits. Prostate specific antigen was normal and CT or bone scintigraphy revealed no local or distant metastasis. Right laparoscopic retroperitoneal access was performed. The cyst was at inferior pole. The tumor was overlaying on cyst wall 1 cm away from parenchyma (Figure 2). Using bipolar coater, cyst decortication together with tumor excision was performed, having security surgical margin minimally 2 cm. Pathological examination confirmed the diagnosis of RCC 2.5 cm in diameter, clear cell subtype, grade I (T1N0M0) (Figure 3). CT revealed no cystic lesion or tumoral recurrence 6 months after the operation.

DISCUSSION

RCC in cystic kidney disease generally develops on a background acquired cystic kidney disease (ACKD),^(4,5) particularly in patients with long-term renal failure and dialysis. It may be related with a toxic effect of uremia, but the pathogenesis remains undermined.⁽⁶⁾ However, transformation of a simple renal cyst into a RCC is extremely rare. According to a review of the literature of the past several decades, only few cases have been reported. Distinctive from others this case shows a natural history of a simple renal cyst to RCC dwelling upon the cyst wall. The mass was unlikely placed at outer side of cyst wall as it has generally been reported at the localization of septum or inner wall of the cyst in literature.^(1,3)

Six cm diameter right renal cystic lesion was found to be simple on initial ultrasound and subsequent CT scan was assigned a Bosniak rank of category I, during the follow-up of locally advanced prostate cancer. This right renal simple cyst was followed by USG. The revelation of the mass overlaying on the cyst was possible 4 years after the first CT. During this 4 years time, none of ultrasonic imaging was able to show any mass except thin septations in the cyst revealed at third year of follow-up. Although the presence of septations in a renal cyst itself does not imply malignancy, one must exclude the possibility of malignancy in an apparently simple cyst when the lesion progresses to septations. Our case emphasizes the importance of recognizing that RCC may occur in a simple renal cyst. Further evalu-

ation like CT or diagnostic laparoscopy is warranted when atypical findings are present.

REFERENCES

1. Hartmen DS, Davis CJ, Johns T, Goldman SM. Cystic Renal cell carcinoma. *Urology*. 1986;28:145-53.
2. Curry NS. Small renal masses (lesions smaller than 3 cm): imaging evaluation and management. *AJR*. 1995;164:355-62.
3. Ljungberg B, Holmberg G, Sjödin JG, Hietala SO, Stenling R. Renal cell carcinoma in a renal cyst: A case report and review of the literature. *J Urol*. 1990;143:797-9.
4. Kojima Y, Takahara S, Miyake O, Nonomura N, Morimoto A, Mori H. Renal cell carcinoma in dialysis patients: a single center experience. *Int J Urol*. 2006;13:1045-8.
5. Liu JS, Ishikawa I, Horiguchi T. Incidence of acquired renal cysts in biopsy specimens. *Nephron*. 2000;84:142-7.
6. Vaseemuddin M, Kraus MA. Quiz page. Acquired kidney disease (ACKD) with associated bilateral renal cell carcinoma. *Am J Kidney Dis*. 2005;46:A48, e47-9.

Archive of SID