

# Step-by-Step Illustrated Endoscopic Extra-peritoneal Radical Prostatectomy (EERP): Tips and Tricks to Trifecta Outcomes

Leonardo O. Reis,<sup>1,2</sup> Eduardo S. Starling,<sup>2</sup> Antonio C. L. Pompeo,<sup>2</sup> Rodolfo B. dos Reis,<sup>3</sup> Lucas Nogueira,<sup>4</sup> Eliney F. Faria,<sup>5</sup> Gustavo F. Carvalhal,<sup>6</sup> Marcos Tobias-Machado<sup>2</sup>

<sup>1</sup> Urologic Oncology Division, Department of Urology, University of Campinas, UNICAMP, São Paulo, Brazil and Faculty of Medicine (Urology) Center for Life Sciences Pontifical Catholic University of Campinas PUC-Campinas, Brazil.

<sup>2</sup> Urologic Oncology and Laparoscopy Section, Department of Urology, ABC School of Medicine, São Paulo, Brazil.

<sup>3</sup> Urologic Division, Department of Surgery, Ribeirão Preto Medical School, Sao Paulo University (USP), Brazil.

<sup>4</sup> Federal University of Minas Gerais - UFMG, Brazil.

<sup>5</sup> Barretos Cancer Hospital, Pio XII Foundation, Barretos, Brazil.

<sup>6</sup> Catholic University, Rio Grande do Sul, Brazil.

Corresponding author:

Leonardo Oliveira Reis, MD, MSc, PhD  
Faculty of Medical Sciences, University of Campinas, Unicamp Rua: Tessália Vieira de Camargo, 126 Cidade Universitária "Zeferino Vaz" Campinas - SP- CEP: 13083-887, Brazil.

Tel/Fax: +55 019 352 17481

E-mail: reisleo@unicamp.br; reisleo.l@gmail.com

Received November 2011  
Accepted April 2012

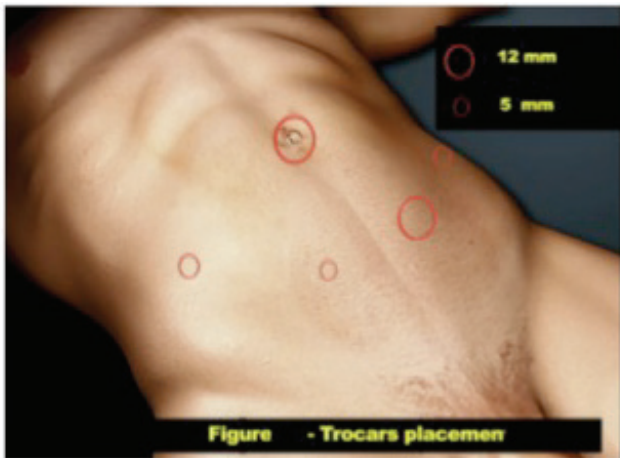
## INTRODUCTION

Laparoscopic prostatectomy has become a widely accepted and applied surgical method of localized prostate cancer treatment. The pearls of critical anatomical and technical features to optimal oncological and functional outcomes on radical prostatectomy are illustrated. Several aspects with respect to that must be recognized in the early phases of training to optimize trifecta outcomes: disease recurrence free, urinary continence and sexual functions preservation.

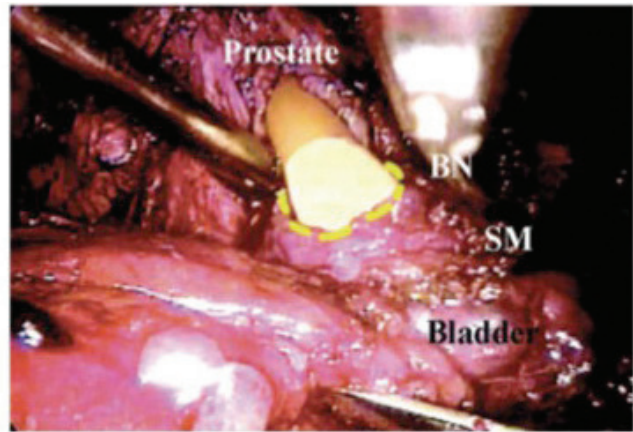
## TECHNIQUE

### *A-Surgical Steps of Retrograde Technique*

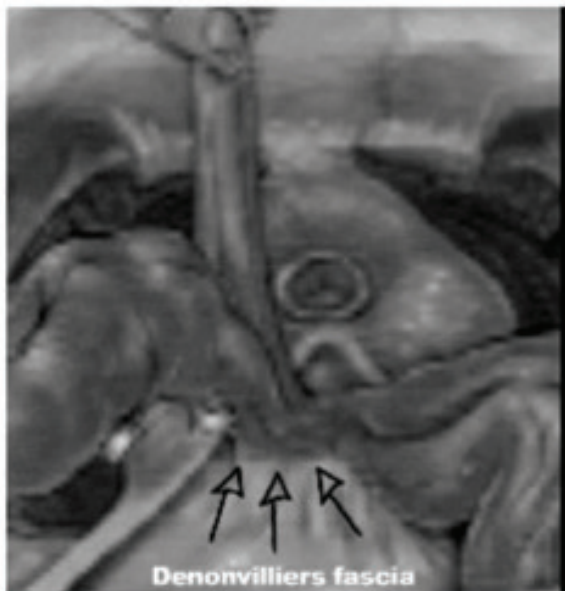1. Patient is positioned in horizontal dorsal decubitus, with Y-shaped abduction of lower limbs on the table.
2. Display of the surgical team. The surgeon operates on the left side; the camera is positioned at the upper end of the table, and the assistant stand at the patient's right side. During suture, for improved comfort, the surgeon and the camera switch places.
3. Umbilical incision measuring 1.5 cm up to the Retzius space.
4. Creation of extra-peritoneal space through digital dissection and modified balloon dilator (handicraft).
5. Hasson trocar (10 mm) through the umbilical incision for the 0-grade optics.
6. Making of pneumo-retroperitonium with CO<sub>2</sub> tension of 15 mmHg;
7. Introduction of another 4 working trocars (2 Para-rectal external measuring 10 mm, and 2 in iliac fosse measuring 5 mm) under direct view, in an arciform shape, taking care in order to avoid peritoneal lesion (Figure 1).
8. Exercises of pre-prostatic fat with monopolar cautery for proper identification of prostate, bladder and pubo-prostatic ligaments.



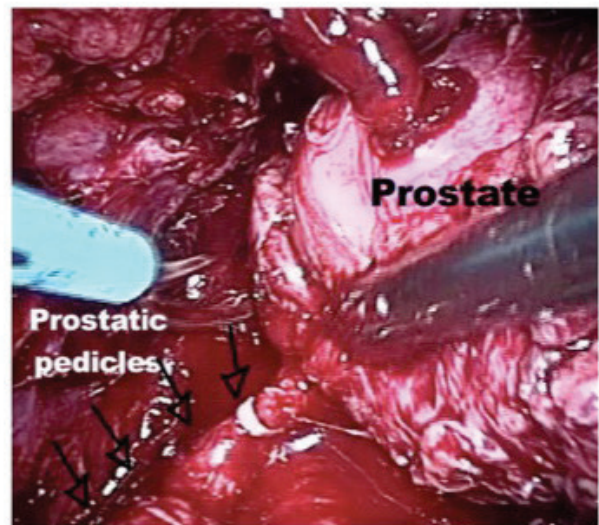
**Figure 1.** The sites for trocar placement.



**Figure 2.** The bladder neck is opening. Preservation is desired, but in case of suspicious invasion, a resection with free margins must be performed.



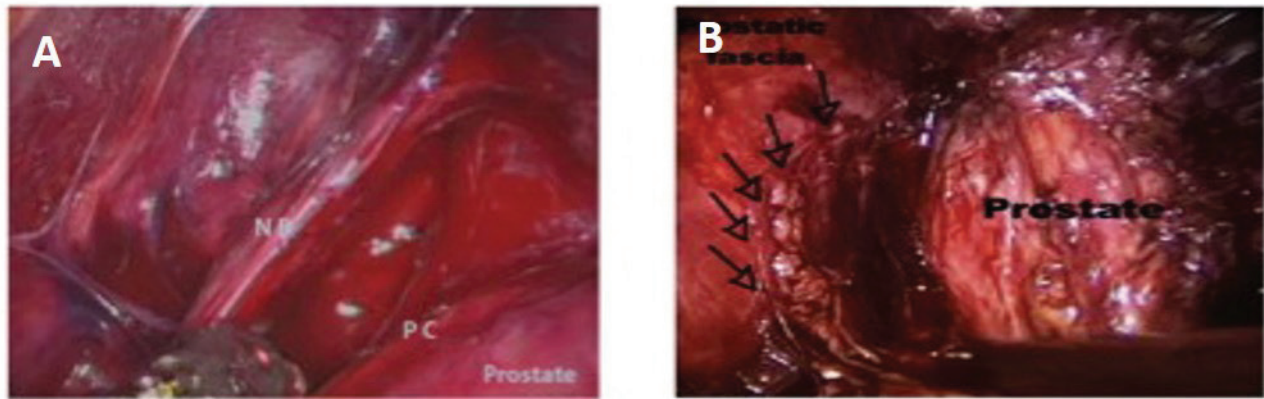
**Figure 3.** Opening posterior Denonvilliers fascia with identification of prostate. No energy dissection between prostate capsule and prostatic visceral fascia in medial to lateral direction.



**Figure 4.** The prostatic pedicles are identified and clipped with Hem-o-lok near to prostate.

9. Bilateral opening of endo-pelvic fascia with scissors, following previous contra-lateral traction of the prostate.
10. Identification and sectioning of pubo-prostatic ligaments.
11. Vascular control of dorsal vein complex of the penis with a X-stitch using 2-0 polyglactine suture with circle taper (CT)-1 needle, and control of the retrograde blood flow with harmonic or bipolar scalpel, or polymer clip (Hem-o-lok). Applying the clip makes the subsequent identification of the bladder neck easier for reconstruction, a surgical step

- that is often arduous when we choose to preserve the bladder neck
12. Apical dissection with preservation of the sphincter apparatus.
13. Sectioning of the dorsal vein complex of the penis with electrocautery or harmonic scalpel, until the urethra is viewed.
14. Opening of the urethral anterior wall with scissors. Section is performed after perfectly identifying the limits of the prostate apex and urethra, thus avoiding positive margins.



**Figure 5.** Vertical opening of anterior aspect of prostatic visceral fascia from puboprostatic ligament to bladder neck. Athermal retrograde blunt and sharp dissection of neurovascular bundle between capsule and prostatic visceral fascia. A: Apical view, B: Proximal view.

15. The catheter balloon is filled with 20 mL of distilled water. The Foley catheter is externally pulled for subsequent knot application with 0-cotton suture including drainage and balloon routes.

16. Cutting the catheter close to the previously applied knot.

17. Removing of the remaining stump of the Foley catheter, through endoscopic view in the extra peritoneal space.

18. Posterior dissection of the urethra and recto-urethral muscle following cranial traction of the catheter by the assistant.

19. Blunt retro prostatic dissection up to the most proximal point as feasible.

20. Identification and opening of the posterior layer of the Denonvilliers fascia. At this time it is possible to identify the pre-rectal fat. The neurovascular bundle lies laterally and under the fascia, which makes nervous preservation easier during ligation of the prostatic pedicle, which is performed by posterior access.

21. Sectioning of the bladder neck, with preservation of muscular fibers whenever possible. The dissection is started with harmonic or bipolar scalpel and upon reaching the urethral mucosa; it is sectioned with scissors.

22. Identification and opening of the anterior layer of Denonvilliers fascia, posterior to the prostate with visualization of vasa deferentia.

23. Identification and sectioning of vasa deferentia with

harmonic or monopolar scalpel.

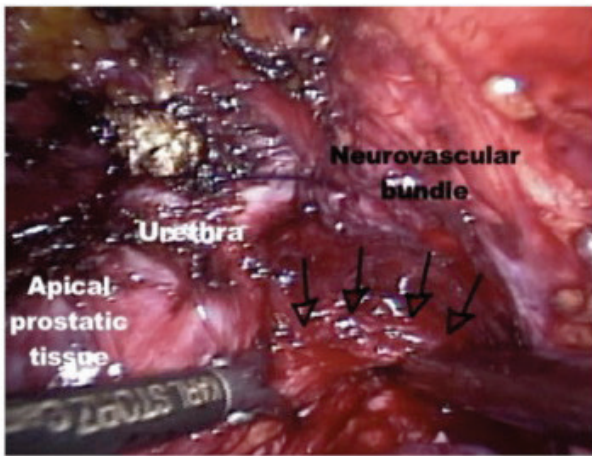
24. Superior traction of the vasa deferentia by the assistant in order to release the seminal vesicles. At this time, we preferred to use harmonic or bipolar scalpel in order to avoid dissipation of thermal energy that could damage the nervi erigentes.

25. The assistant performs the lateral and superior traction of previously mobilized (released) prostate, enabling the clear identification of the prostatic pedicles and the prostate capsular limits. The control of the prostatic pedicles is performed with harmonic or bipolar scalpel. Alternatively polymer clips (Hem-o-lok) can be used.

26. Exercise and entrapment of the specimen that is located in right iliac fossa.

27. Vesicourethral anastomosis is initiated with the patient in Trendelenburg position in order to improve the visualization of the urethra. The surgeon works with the pararectal 10-mm trocars at the upper end of the table. We perform a continuous 3-0 polyglecaprone (monocryl) suture with small half (SH) circle needle. We use two 13-cm sutures, one colorless and the other one violet, externally tied by the distal end. A modified van Velthoven suture<sup>(1)</sup> begins at 4 o'clock position in the bladder directed inwards and each of the sutures rises toward 8 o'clock position, where a single internal knot is made.

28. Drainage with Penrose through one of the 5-mm ports.



**Figure 6.** Apical dissection taking care to achieve a good urethral length preventing positive margins and lesion of neurovascular bundle.

29. Removal of the specimen by enlargement of the umbilical port and closure of the incisions.

#### *B-Surgical Steps of Antegrade Technique*

The theoretical advantage of this technique is to perform the division of dorsal venous plexus in the last step of surgery. In this way, less bleeding occurs in the initial steps of dissection. The same surgical steps are performed to access the extra-peritoneal cavity. Actually we open the endopelvic fascia only if intra-fascial dissection was not elected and

control the venous plexus as the same manner exposed on retrograde technique. We tie the knot but we do not section the plexus, and at that moment we start a dissection from the bladder neck to the prostate apex.

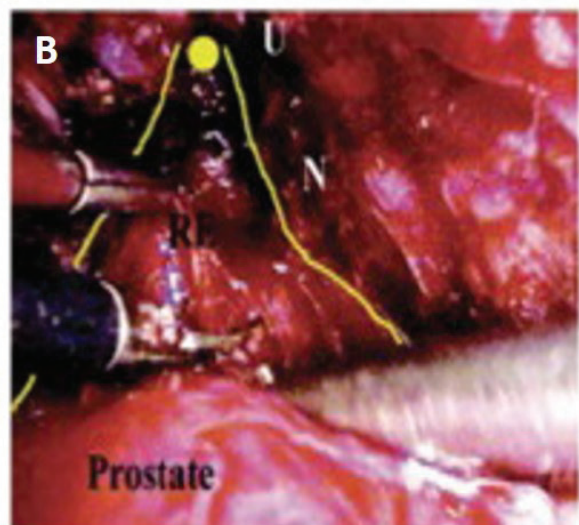
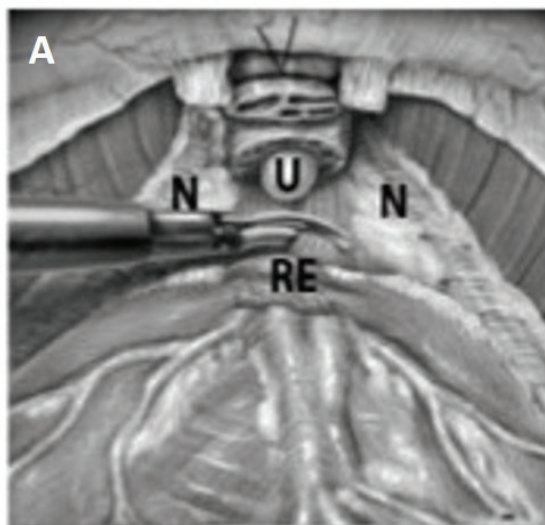
1. After Santorini's plexus knot, the back bleeding suture was placed on the anterior surface of the prostate. Traction is placed in this knot to push the prostate and the bladder through the sixth trocar. Beniquet can aid to find the transition between the bladder and prostate. At this moment we open the bladder neck with harmonic scalpel (Figure 2).

2. The Foley catheter is grasped to perform the posterior bladder neck dissection.

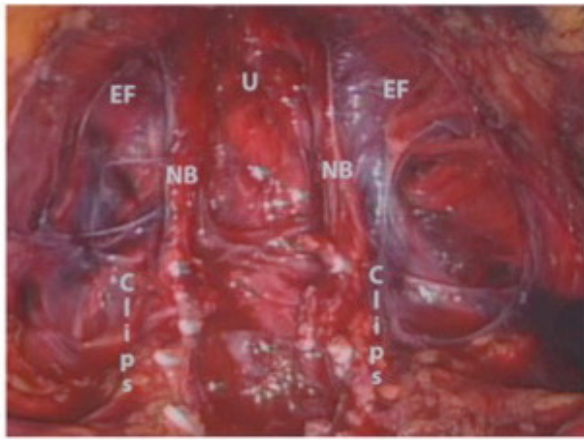
3. After opening the posterior layer of detrusor muscle, vasa deferentia are identified, dissected free and divided. Diagonal contra-lateral traction was performed to better expose the homo-lateral seminal vesicle. Here there is always a small artery and a careful dissection is encouraged. Vessels near to the vascular bundle are controlled athermically with clips. The dissection of the seminal vesicles is performed.

4. After dissection the seminal vesicle is retracted anteriorly, the Denonvilliers fascia is opened behind the prostate to identify the peri-rectal fatty and the bundles are dissected gently without any thermo source (Figure 3).

5. Hem-o-lok clips are used to control the pedicles (Figure 4). At this moment we decide about the level of preserva-



**Figure 7.** Retroprostatic dissection near to prostate to maintain posterior fibers of urinary sphincter attached to urethra. A: Schematic view, B: Endoscopic view.



**Figure 8.** Aspects of neurovascular bundles after the infra-vesical nerve sparing technique.

tion of neurovascular bundle (intrafascial, interfascial or extrafascial). The limits between the prostate and the pedicle can be perfectly seen. In selected and favorable patients in whom preservation is possible we perform the most recent refinement of the endoscopic extra-peritoneal radical prostatectomy - the intra-fascial nerve sparing.

As part of the intrafascial technique, the dissection plane is directly on the prostatic capsule, freeing the prostate laterally from its thin surrounding fascia that contains small vessels and nerves. The technique enables pubo-prostatic ligament preservation, leaving intact endopelvic fascia, peri-prostatic fascia, and neurovascular bundles.

Based on anatomic relationships between investing prostatic fascial layers and the neurovascular bundle, emphasis is placed on division of the apical prostatic urethra between the anterolateral endopelvic fascia and Denonvilliers fascia (intrafascial dissection) in avoidance of the apical nerves (Figure 5A). It maintains veil of Aphrodite and open the visceral fascia anteriorly just in the moment of pedicle ligation. Vertical incision in the fused distal portion of Denonvilliers fascia is necessary to make this dissection atraumatic regarding the adjacent para-prostatic neurovascular bundle (Figure 5B).

6- A Benquet is important to complete lateral dissection of the prostate. It can push the prostate down to secure a good separation between the apical bundle and the prostate

(Figure 6).

7- At this moment apical dissection is performed. It is extremely important step because most of the positive margin comes from the apex. An excellent visualization permit a better preservation of fibers from urinary sphincter maintaining the urethral stamp attached to pubo-prostatic ligament without jeopardize apical margin. The dorsal venous complex is divided with a best length of urethra (Figure 7A and 7B); the urethra and recto-urethralis is divided and the specimen freed from final adhesions (Figure 8).

8- Pathological specimen removed in a bag.

9- Running vesico-urethral anastomosis is done similar to previous description.

Technique standardization and the recognition of pearls of critical anatomical and technical features are fundamental to optimal oncological and functional outcomes on radical prostatectomy named trifecta: - disease recurrence free, - urinary continence and - sexual functions preservation. Furthermore, it must be recognized in the early phases of training.<sup>(2)</sup>

## CONFLICT OF INTEREST

None declared.

## REFERENCES

1. Van Velthoven RF, Ahlering TE, Peltier A, Skarecky DW, Clayman RV. Technique for laparoscopic running urethrovesical anastomosis: the single knot method. *Urology*. 2003;61:699-702.
2. Starling ES, Reis LO, Vaz Juliano R, et al. Extraperitoneal endoscopic radical prostatectomy: How steep is the learning curve? Overheads on the personal evolution technique in 5-years experience. *Actas Urol Esp*. 2010;34:598-602.