

Retroperitoneoscopic Upper Pole Nephroureterectomy in Duplex Kidney: Focus on the Role of Dilated Upper Pole Ureter

Zhi Chen,¹ Zheng-Yan Tang,¹ Ben-Yi Fan,¹ Xiang Chen,¹ Peng Zhou,² Yan-Cheng Luo,¹ Yao He,¹ Chao-Qun Xie,¹ Chen Lai,¹ Xiao-Long Fang¹

¹Department of Urology, Xiangya Hospital, Central South University, Changsha, Hunan Province, China.

²Department of General Surgery, Xiangya Hospital, Central South University

Corresponding author:

Xiang Chen, MD
Department of Urology, Xiangya Hospital, Central South University, Changsha, Hunan Province, China.

Tel: +86 138 7480 8998
Fax: +73 184 327354

Email: cxiang1007@126.com

Received May 2012
Accepted January 2013

Purpose: To describe our technique and experience with retroperitoneoscopic upper pole nephroureterectomy in duplex kidney, focusing on the role of dilated upper ureter.

Materials and Methods: From November 2004 to August 2011, retroperitoneoscopic upper pole nephroureterectomy was performed in 31 patients with a duplex kidney by a single, experienced laparoscopic surgeon. We developed our own surgical technique to suit this technically challenging procedure. Follow-up studies were performed using renal ultrasonography, intravenous urography (IVU) and/or dimercaptosuccinic acid (DMSA) renal scan in all patients at 3 months postoperatively and annually thereafter.

Results: All procedures were completed laparoscopically without conversion to open surgery and blood transfusion. The mean operative time was 106 (90-157) min. The estimated blood loss was < 50 mL in all cases. The mean postoperative hospital stay was 4.2 (3-7) days. Perioperative complications were limited to 1 case of peritoneal tear during a procedure and 1 case of transient postoperative fever. No major intraoperative and postoperative complication occurred. With the mean follow-up period of 41 months (range 3 to 80), no case was observed to have functional loss of the remaining lower moiety on postoperative IVU or DMSA renal scan.

Conclusion: Retroperitoneoscopic upper pole nephroureterectomy using our technique is safe and effective.

Keywords: laparoscopy; retroperitoneal space; postoperative complications; kidney abnormalities; treatment outcome.

INTRODUCTION

Duplex kidney is a common congenital anomalies of the urinary tract. Heminephrectomy, either by an open or a laparoscopic approach, is a well-established option for the management of nonfunctioning or symptomatic renal moieties in duplex kidneys. Several reports have demonstrated that laparoscopic heminephrectomy was a safe and technically feasible with the advantages of less morbidity, decreased postoperative pain, improved cosmetic result and significantly shorter hospital stays compared with open surgery.⁽¹⁻¹⁰⁾ However, laparoscopic heminephrectomy, especially for upper pole heminephrectomy, may be a much more complex operation and more technically challenging than total nephrectomy,^(10,11) because it is usually difficult to control upper pole vessels and excise upper pole parenchyma. That may lead to inadvertent injury to the vessels and parenchyma of lower pole moiety, thus offering a higher risk of bleeding responsible for hematoma, urine leakage responsible for urinoma and pedicle lesions responsible for lower pole deterioration.^(2-7,9,10) This explains why minimally invasive techniques have remained confined to the hands of experienced teams, with a limited number of reports including relatively few cases.^(10,11) In this study, we developed our own surgical technique to suit this technically challenging procedure. The aim of the present study is to describe our technique and experience with retroperitoneoscopic upper pole nephroureterectomy in duplex kidney, focusing on the role of dilated upper ureter.

MATERIAL AND METHODS

Patients

From November 2004 to August 2011, 31 patients with a duplex kidney (10 men and 21 women) underwent retroperitoneoscopic upper pole nephroureterectomy. The mean age is 30.4 years (range, 13-47). The all procedures were performed by a single, experienced laparoscopic surgeon (Xiang Chen). Of the 31 patients, 11 had a duplicated collecting system on the right side, 18 on the left side, and 2 on both sides. Of the procedures, 18 were on the left and 13 on the right side. The presenting symptoms included flank pain in 19 patients, recurrent urinary tract infection in 10, and hematuria in 2. No patient had undergone previous renal surgery.

Ultrasonography, intravenous urography (IVU) and/or computed tomography urography (CTU) and dimercaptosuccinic acid (DMSA) renal scan were routinely used to evaluate the patients preoperatively. Voiding cystourethrography (VCUG) was used to demonstrate vesicoureteral reflux and the presence of an ureterocele. The indications for upper pole heminephrectomy were ectopic ureter with a non-functioning upper pole moiety or ureterocele with a non-functioning upper pole moiety. Follow-up studies were performed with ultrasonography and IVU or DMSA renal scan at 3 months postoperatively and annually thereafter.

Laparoscopic Technique

All procedures were performed with the patient in the lateral decubitus position under general anesthesia. A 3- or 4-port, finger- and balloon-dissecting, retroperitoneoscopic approach was used, as described in previous series.⁽²¹⁾ The retroperitoneal fat and adjacent tissues were first dissected sufficiently with a harmonic scalpel and removed to create a larger working space. Then Gerota's fascia was incised longitudinally. The upper pole moiety and part of the lower pole moiety was dissected free from the peri-renal fat and tissue. After clear identification of the ureters of both moieties (Figure 1A), the dilated upper pole ureter was dissected free to the closest edge of the pelvis. With traction on the dilated upper pole ureter, the renal artery was identified and carefully dissected. The branch for the upper and lower pole vessels could be easily identified, because the upper pole vessels often located behind and above the dilated upper pole ureter and the lower pole vessels located beneath that. The polar vessels to the upper pole moiety were mobilized carefully and were clipped using two titanium or Hem-o-Lok clips at the proximal end and one on the kidney side, and divided (Figure 1B). If there were any concerns regarding the polar vessels to the upper pole moiety, the potential branch to upper pole moiety could be temporarily clamped with atraumatic forceps to confirm the ischemic color change of the upper pole moiety. The dilated upper pole ureter was then transected close to the renal pelvis using a harmonic scalpel. After the proximal ureteral stump was drawn towards the diaphragm by forceps, dissection proceeded in the plane between the urothelium of the upper pole moiety and the renal parenchymal surface

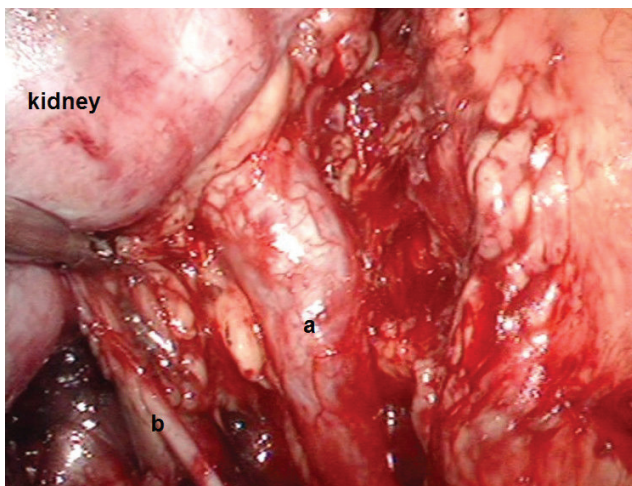


Figure 1A. The upper (a) and lower (b) ureters were clearly identified.

of the lower pole moiety to most closely expose the edge of parenchymal section (Figure 1C). Excision of the upper pole moiety was performed using a harmonic scalpel along a border between the upper and lower pole moiety, which corresponded to the level of vascular demarcation (Figure 1D). The edge of the parenchymal section was approximated with intracorporeally interrupted sutures using 2-0 Vicryl suture to achieve complete hemostasis. The remnant upper pole ureter was mobilized toward the bladder level to allow as complete an ureterectomy as possible. The distal dilated ureter was left open. Great care should be taken to avoid possible injury to the blood supply of the lower pole ureter. Finally, a drain was left in place.

RESULTS

Preoperative imaging demonstrated that all patients had a complete pelvic and ureter duplication and a dilated and nonfunctioning upper-pole moiety due to ectopic ureter. No vesicoureteral reflux or ureterocele was found in all patients using preoperative VCUG. The outcomes of our series and the similar published studies were summarized in Table. All procedures were completed laparoscopically without conversion to open surgery and blood transfusion. The mean operative time was 106 (90-157) min. The estimated blood loss

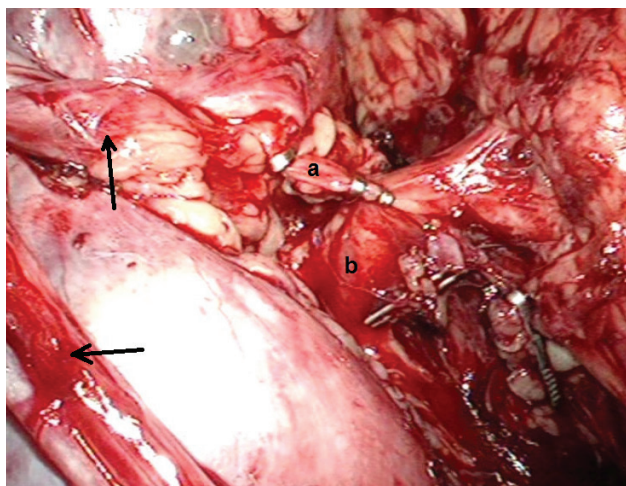


Figure 1B. The upper pole vessels (a) often located above the dilated upper pole ureter and the lower pole vessels (b) located beneath that. The upper pole vessels were mobilized carefully and were clipped using two titanium clips at the proximal end and one on the kidney side (arrow pointing to the dilated upper ureter that was drawn towards the diaphragm).

was < 50 mL in all cases. The mean postoperative hospital stay was 4.2 (3-7) days. Preoperative complications were limited to 1 case of peritoneal tear during a procedure and 1 case of transient postoperative fever. No major intraoperative and postoperative complication occurred. With the mean follow-up period of 41 months (range 3 to 80), no case was observed to have functional loss of the remaining lower moiety on postoperative IVU or DMSA renal scan.

DISCUSSION

Non-functioning or symptomatic upper pole moieties are the most common clinical indication for heminephrectomy in duplex kidneys.⁽¹⁰⁾ Although laparoscopic heminephrectomy has been demonstrated to be a technically feasible and minimally invasive procedure to treat this morbidity, to date, this procedure remains limited to few centers with advanced laparoscopic experience. Laparoscopic heminephrectomy, especially upper pole heminephrectomy, may be very technical challenging,⁽¹⁰⁾ because it offers the higher risk of bleeding, urine leakage and lower pole deterioration. Jayram and colleagues⁽⁹⁾ reported that they combined data from 4 high-volume international teaching centers to evaluate outcomes following laparoscopic heminephrectomy, and found that 7 children (4.9%) had a significantly functional loss in the re-

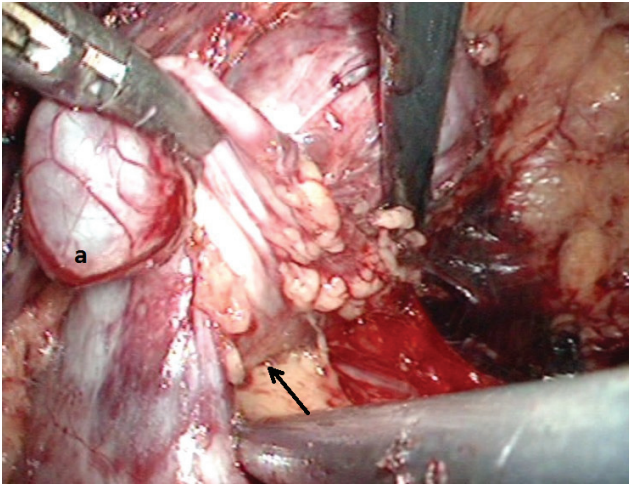


Figure 1C. After the proximal ureteral stump (a) was drawn towards the diaphragm by forceps, dissection proceeded in the plane (arrow pointing) between the urothelium of the upper pole moiety and the renal parenchymal surface of the lower pole moiety to most closely expose the edge of parenchymal section.

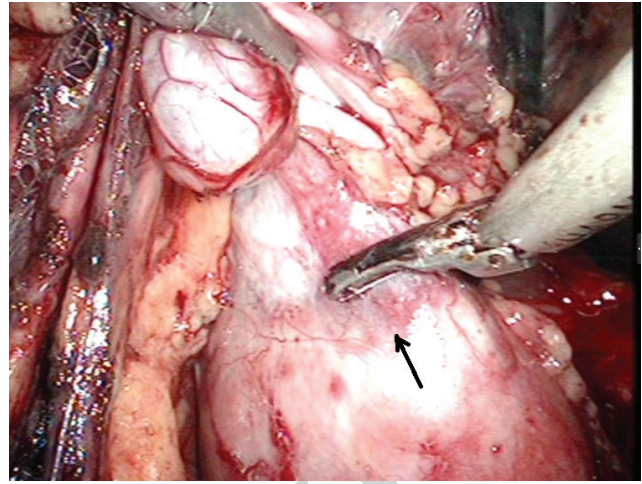


Figure 1D. Excision of the upper pole moiety was performed using a harmonic scalpel along a border (arrow pointing) between the upper and lower pole moiety, which corresponded to the level of vascular demarcation.

maintaining moiety with a median follow-up of 4.5 years, 11 patients (7.7%) required open conversion and 7 patients (4.9%) developed a postoperative urinoma. Major technical difficulties in laparoscopic upper pole heminephrectomy are related to control upper pole vessels and excise upper pole parenchyma. In the present study, we developed our own surgical technique to suit this technically challenging procedure via retroperitoneal approach, in which the role of dilated upper ureter was emphasized on.

The most technically challenging portion of retroperitoneoscopic upper pole heminephrectomy may be the renal hilar dissection, because vascular injuries may lead to severe bleeding and a functional loss of the lower pole moiety. In our experience, to obtain vascular control, the dilated upper pole ureter was drawn towards the diaphragm, which facilitated the mobilization of the polar vessels to the upper pole moiety. Simultaneously, excessive traction on the polar vessels to the lower pole moiety, which may be detrimental to postoperative renal outcome,⁽⁹⁾ should be avoided. Furthermore, because the polar vessels to the upper pole moiety often located behind and above the dilated upper pole ureter and the polar vessels to the lower pole moiety located beneath that, the identification of upper and lower pole vessels could be relatively easy using the dilated upper pole ureter as

a landmark. In addition, if there were any concerns regarding the upper pole vessels, in order to confirm the ischemic color change of the upper pole moiety, we can temporarily clamp the branch using atraumatic forceps.⁽¹²⁾

Section of upper pole parenchyma could be another technically challenging portion of retroperitoneoscopic upper pole heminephrectomy, because inappropriate section of renal parenchyma could result in postoperative urine leakage from the functioning remnant upper pole moiety or the opening of the remaining lower pole calices. In our experience, there is often a lax plane between the urothelium of upper pole moiety and the renal parenchymal surface of lower pole moiety. Whereas the dilated upper ureter was drawn towards the diaphragm by forceps, constant traction maintained adequate exposure and dissection along that plane could be easy and safe, in our experience, almost with no bleeding. Furthermore, the exactly control of upper pole vessels could contribute to successful identification of the border between upper and lower pole using the ischemic color change of the parenchyma. With traction on the dilated upper pole ureter, section of upper pole parenchyma could be also easily performed. Therefore, the risk of inadvertent injury to the lower pole moiety could be reduced as far as possible. Li and colleagues⁽¹²⁾ reported that in their procedure the upper pole renal parenchyma was di-

Table. Outcomes of patients treated with laparoscopic upper pole heminephrectomy.*

Series	Patients (no.)	TP/RP (no.)	OT (min)	EBL (mL)	Conversion to open surgery (no.)	Mean hospital stay (days)	Follow-up (months)	Complications (no.)
Janetschek et al. ¹⁴ (1997)	9	9/0	222 (180-330)	10-30	None	4.4 (3-6)	NA	None
Horowitz et al. ¹⁹ (2001)	14	14/0	100 (70-135)	< 30	None	2.6 (2-4)	NA	None
Valla et al. ²⁹ (2003)	24	0/24	180	NA	3	3.4	32 (6-60)	Urinoma (5)
Wang et al. ²⁰ (2004)	3	3/0	198 (165-244)	63 (40-100)	None	3 (1-6)	5.3 (3-9)	Urinoma (1)
Olsen et al. ³⁰ (2005)**	14	0/14	176 (120-360)	Minimal (< 10 mL)	2	1 (1-4)	8 (1-24)	UTI (1)
Abouassaly et al. ²¹ (2007)	5	5/0	189 (150-225)	120 (100-200)	None	2.8 (2-4)	42 (11-72)	Urinoma (1)
Denes et al. ¹⁵ (2007)	17	0/17	147	< 50	None	3.2 (2-6)	57.1	UTI (5), Ureteral stump empyema (3)
Breda et al. ²² (2007)	3	3/0	138 (120, 135, 160)	Negligible	None	2 (1-4)	NA	None
Miranda et al. ²³ (2007)	7	7/0	135 (120-160)	NA	None	1.7 (1-2)	18	None
Seibold et al. ²⁴ (2008)	5	5/0	190 (170-210)	Minimal (< 50)	None	5.6 (4-7)	42.4	None
Leclair et al. ⁴ (2009)	36	0/36	120 (70-215)	NA	6	3 (2-13)	14 (3-125)	Functional loss of remaining moiety (1),
Schneider et al. ²⁵ (2010)	7	7/0	130 (90-195)	NA	None	3 (2-6)	14.4 (1.2-38.5)	Diminution of renal function with pyelic dilation (1)
Li et al. ³¹ (2011)	32	0/32	83 (55-110)	18 (10-50)	None	7 (5-9)	NA	None
Mason et al. ²⁶ (2012)**	4	4/0	310 (240-400)	395 (80-1200)	None	2.2 (2-3)	13 (9-19)	None
Abedinzadeh et al. ²⁷ (2012)	14	14/0	203 (95-360)	Negligible	None	4.1 (2-7)	32	Atrophy of remaining moiety (1)
Our series	31	0/31	106 (90-157)	< 50	None	4.2 (3-7)	41 (3-80)	None

Keys: TP, transperitoneal; RP, retroperitoneal; OT, Operative time; EBL, Estimated blood loss; NA, information not available.

* Only reports of 3 or more cases and reports that had available data of laparoscopic upper pole heminephrectomy are included. ** Robot-assisted laparoscopic upper pole heminephrectomy.

vided circumferentially between the upper and lower poles using a harmonic scalpel before the urothelium of the remnant upper pole parenchyma was stripped off. However, with no adequate mobilization of urothelium of the upper pole parenchyma, resection circumferentially between the upper and lower poles could lead to inadvertent injury to the lower pole moiety.⁽¹²⁾ Although in their study they maintained a margin around the upper pole parenchyma, incomplete removal of the diseased moiety could lead to renal cyst formation. Recently, the endoloop technique have been an alternative to reduce the level of technical difficulty of the parenchymal section,⁽¹³⁾ however, this variant may also be responsible for a higher incidence of cyst formation at the resection margin.⁽¹⁰⁾ Although it is more difficult to perform by laparoscopy, in-

tracorporeally interrupted sutures using 2-0 Vicryl suture of the parenchymal section is recommended to achieve complete hemostasis, as performed in open surgery. Valla and colleagues⁽¹¹⁾ reported that in their study the cut surface was not routinely sutured in their first 19 cases, leading to postoperative residual effusion in 5 cases.⁽¹¹⁾ In contrast, with our present surgical techniques, no postoperative bleeding and urine leakage was found in our series. In our technique, the dilated upper pole ureter was transected close to the renal pelvis using a harmonic scalpel just after the vessels supplying the upper pole moiety was clipped. That has two roles. First, when clipping the vessels supplying the upper pole moiety, the dilated upper moiety could be helpful to confirm the ischemic color change of the upper pole moiety; in contrast,

when stripping off the urothelium of the upper pole moiety and dividing upper pole parenchyma, decompression of the dilated pelvis and upper moiety could increase the working space, thus facilitating the manipulation; Second, traction on the shorter proximal ureteral stump could present a good surgical exposure without the interference of a redundant ureteral stump.

Laparoscopic heminephroureterectomy can be performed either through a transperitoneal (TP)⁽¹⁴⁻²⁷⁾ or a retroperitoneal (RP)^(2,4, 9,10,12,15,28-31) approach. The later included lateral (LRP) and prone (PRP) approaches. There are several advantages and disadvantages to each approach. Castellan and colleagues⁽⁶⁾ compared TP and RP approaches in a total of 48 laparoscopic heminephrectomies and they investigated five complications, which was not depending on the surgical approach but related to patient age. Kieran and colleagues⁽³²⁾ compared the intraoperative parameters and perioperative complications of retroperitoneal and transperitoneal approaches to laparoscopic partial nephrectomy. They found that the incidence of perioperative complications was similar in the 2 groups but the operative time and length of stay were shorter and the estimated blood loss was lower in RP group. The outcomes of our series and the similar published studies were summarized in Table 1. Horowitz and colleagues⁽¹⁹⁾ described their experience with laparoscopic upper pole heminephrectomy in 13 pediatric patients through a transperitoneal approach. Mean operative time was 104 min, estimated blood loss was less than 30 mL, and mean hospital stay of 2.6 days. Similarly, and colleagues⁽³¹⁾ demonstrates the effectiveness and low morbidity of the retroperitoneal approach for laparoscopic upper pole heminephrectomy. Mean operative time was 83 min, mean estimated blood loss was 18 mL, and mean hospital stay of 7 days. Our study has also confirmed the efficacy and low morbidity of the retroperitoneoscopic approach in terms of the operative time, minimal blood loss, minimal complications, hospital stay, and recuperation (Table). We believe that the choice of surgical approach, whether TP or LRP or PRP, could be depend on the surgeon comfort and experience. The LRP approach was preferred in our centre because of our previously extensive experience with this approach.^(33, 34) The LRP approach, although more technically challenging, provides a direct and

rapid access to the kidney and renal hilum and effectively exposes the renal pedicle without having to mobilize the colon, thus reducing the possibility of intraperitoneal organ injury intraoperatively and organ adhesions postoperatively.⁽¹⁰⁾ Furthermore, LRP approach allows the vessels supplying the upper pole moiety to be treated prior to parenchymal section, thereby limiting blood loss.⁽¹¹⁾ Moreover, it could facilitate the vascular control of the upper pole moiety because the renal artery was first encountered before the vein, and dissection of the hilum vessels could be facilitated because it was not hindered by the presence of the ureters through the LRP approach, as in the case of the TP approach.⁽¹¹⁾ In addition, a completely dry field should be maintained intraoperatively, which was very important because of the limited working space through a LRP approach.

The data in the published reviews demonstrates remaining moiety loss rates of 1-9% in laparoscopic heminephroureterectomy series.^(2,5-7,9,10) Various factors (i.e. pneumoperitoneum, patient age, and injury to the remaining pole vessels) have been thought to be possibly responsible for remaining moiety loss. However, to date, only patient age has been established to have a strong correlation to renal loss.⁽²⁾ In our series, with the mean follow-up period of 41 months, no case was observed to have functional loss of the remaining lower moiety on postoperative IVU or DMSA renal scan. That could be explained in part by the fact that in our series the majority of patients were adults. Therefore, these adult patients could provide a relatively bigger retroperitoneal working space, thus facilitating the surgical difficulties. Furthermore, in our technique, we emphasized on the role of dilated upper ureter and kept a high awareness of risk of vascular damage to lower moiety, which could be another reason for no functional loss of the remaining lower moiety in our series.

In published reviews, the most conversions to open surgery occurred at the beginning of the experience for the reasons of poor visualization, bleeding, opening of upper- or lower-pole calyces, injury to unaffected ureter or peritoneal tear.^(10,35-38) In our series, no conversion to open surgery occurred. Two reasons may explain that. First, we had significantly improved surgical capabilities and accumulated extensive experience with retroperitoneoscopic kidney surgery (i.e. live donor nephrectomy, simple or radical nephrectomy) before

we started the practice of retroperitoneoscopic upper pole heminephrectomy. Second, because we highly emphasized the role of dilated upper ureter to reduce the injury to the vessels and parenchyma of lower pole moiety, surgical complications was significantly reduced. Although peritoneal tear was found in one case intraoperatively, a fourth trocar was introduced to provide additional retraction and the procedure was completed successfully.

CONCLUSIONS

Retroperitoneoscopic upper pole nephroureterectomy using our technique was safe and effective. The possibility of vascular damage to the lower pole moiety warranted a very cautious dissection of the renal pedicle and section of the renal parenchyma.

ACKNOWLEDGMENT

Zhi Chen and Zheng-Yang Tang contributed equally to this work.

CONFLICT OF INTEREST

None declared.

REFERENCES

1. Yao D, Poppas DP. A clinical series of laparoscopic nephrectomy, nephroureterectomy and heminephroureterectomy in the pediatric population. *J Urol.* 2000;163:1531-35.
2. Wallis MC, Khoury AE, Lorenzo AJ, Pippi-Salle JL, Bagli DJ, Farhat WA. Outcome analysis of retroperitoneal laparoscopic heminephrectomy in children. *J Urol.* 2006;175:2277-80.
3. Schneider A, Ripepi M, Henry-Florence C, Geiss S. Laparoscopic transperitoneal partial nephrectomy in children under 2 years old: A single-centre experience. *J Pediatr Urol.* 2010;6:166-70.
4. Leclair MD, Vidal I, Suply E, Podevin G, Heloury Y. Retroperitoneal laparoscopic heminephrectomy in duplex kidney in infants and children: a 15-year experience. *Eur Urol.* 2009;56:385-89.
5. Singh RR, Wagener S, Chandran H. Laparoscopic management and outcomes in non-functioning moieties of duplex kidneys in children. *J Pediatr Urol.* 2010;6:66-69.
6. Castellan M, Gosalbez R, Carmack AJ, Prieto JC, Perez-Brayfield M, Labbie A. Transperitoneal and retroperitoneal laparoscopic heminephrectomy--what approach for which patient? *J Urol.* 2006;176:2636-39.
7. Goyal A, Hennayake S. Prone retroperitoneoscopic approach for heminephrectomy: Specific advantages relating to access to vascular pedicle. *Journal of Pediatric Urology.* 2010;6:153-56.
8. Lee RS, Retik AB, Borer JG, Diamond DA, Peters CA. Pediatric retroperitoneal laparoscopic partial nephrectomy: comparison with an age matched cohort of open surgery. *J Urol.* 2005;174:708-11.
9. Jayram G, Roberts J, Hernandez A, et al. Outcomes and fate of the remnant moiety following laparoscopic heminephrectomy for duplex kidney: A multicenter review. *J Pediatr Urol.* 2011;7:272-75.
10. Leclair M-D, Vidal I, Suply E, Podevin G, Héloury Y. Retroperitoneal Laparoscopic Heminephrectomy in Duplex Kidney in Infants and Children: A 15-Year Experience. *Eur Urol.* 2009;56:385-91.
11. Valla J. Treatment of Ureterocele on Duplex Ureter: Upper Pole Nephrectomy by Retroperitoneoscopy in Children Based on a Series of 24 Cases. *Eur Urol.* 2003;43:426-29.
12. Li H-Z, Ma X, Zhang J, et al. Retroperitoneal Laparoscopic Upper-pole Nephroureterectomy for Duplex Kidney Anomalies in Adult Patients. *Urology.* 2011;77:1122-25.
13. Mushtaq I, Haleblan G. Laparoscopic heminephrectomy in infants and children: first 54 cases. *J Pediatr Urol.* 2007;3:100-103.
14. Janetschek G, Seibold J, Radmayr C, Bartsch G. Laparoscopic heminephroureterectomy in pediatric patients. *J Urol.* 1997;158:1928-30.
15. Denes FT, Danilovic A, Srougi M. Outcome of laparoscopic upper-pole nephrectomy in children with duplex systems. *J Endourol.* 2007;21:162-68.
16. Kurokawa Y, Kanayama HO, Anwar A, et al. Laparoscopic nephroureterectomy for dysplastic kidney in children: an initial experience. *Int J Urol.* 2002;9:613-17.
17. Gao Z, Wu J, Lin C, Men C. Transperitoneal Laparoscopic Heminephrectomy in Duplex Kidney: Our Initial Experience. *Urology.* 2011;77:231-36.
18. Seibold J, Schilling D, Nagele U, et al. Laparoscopic heminephroureterectomy for duplex kidney anomalies in the pediatric population. *Journal of Pediatric Urology.* 2008;4:345-47.
19. Horowitz M, Shah SM, Ferzli G, Syad PI, Glassberg KI. Laparoscopic partial upper pole nephrectomy in infants and children. *BJU Int.* 2001;87:514-16.
20. Wang DS, Bird VG, Cooper CS, Austin JC, Winfield HN. Laparoscopic upper pole heminephrectomy for ectopic ureter: initial experience. *Can J Urol.* 2004;11:2141-45.
21. Abouassaly R, Gill IS, Kaouk JH. Laparoscopic Upper Pole Partial Nephrectomy for Duplicated Renal Collecting Systems in Adult Patients. *Urology.* 2007;69:1202-5.
22. Breda A, Lam JS, Veale J, Lerman S, Schulam PG. Laparoscopic heminephrectomy for upper-pole moiety in children using a 3-mm laparoscope and instruments. *J Endourol.* 2007;21:883-85.

23. Miranda ML, Oliveira-Filho AG, Carvalho PT, Ungersbock E, Olimpio H, Bustorff-Silva JM. Laparoscopic upper-pole nephroureterectomy in infants. *Int Braz J Urol.* 2007;33:87-91.
24. Seibold J, Schilling D, Nagele U, et al. Laparoscopic heminephroureterectomy for duplex kidney anomalies in the pediatric population. *Journal of Pediatric Urology.* 2008;4:345-47.
25. Schneider A, Ripepi M, Henry-Florence C, Geiss S. Laparoscopic transperitoneal partial nephrectomy in children under 2 years old: A single-centre experience. *J Pediatr Urol.* 2010;6:166-70.
26. Mason MD, Peters CA, Schenkman NS. Robot-assisted upper pole nephrectomy in adult patients with duplicated renal collecting systems. *J Endourol.* 2012;26:838-42.
27. Abedinzadeh M, Nouralizadeh A, Radfar MH, Moslemi MK. Transperitoneal laparoscopic heminephrectomy in duplex kidneys: a one center experience. *Ger Med Sci.* 2012;10:Doc05.
28. Kawauchi A, Fujito A, Naito Y, et al. Retroperitoneoscopic heminephroureterectomy for children with duplex anomaly: Initial experience. *Int J Urol.* 2004;11:7-10.
29. Valla JS, Breaud J, Carfagna L, Tursini S, Steyaert H. Treatment of ureterocele on duplex ureter: upper pole nephrectomy by retroperitoneoscopy in children based on a series of 24 cases. *Eur Urol.* 2003;43:426-29.
30. Olsen LH, Jørgensen TM. Robotically assisted retroperitoneoscopic heminephrectomy in children: initial clinical results. *Journal of Pediatric Urology.* 2005;1:101-104.
31. Li HZ, Ma X, Zhang J, et al. Retroperitoneal laparoscopic upper-pole nephroureterectomy for duplex kidney anomalies in adult patients. *Urology.* 2011;77:1122-25.
32. Kieran K, Montgomery JS, Daignault S, Roberts WW, Wolf JS, Jr. Comparison of intraoperative parameters and perioperative complications of retroperitoneal and transperitoneal approaches to laparoscopic partial nephrectomy: support for a retroperitoneal approach in selected patients. *J Endourol.* 2007;21:754-59.
33. Chen Z, Chen X, Luo YC, He Y, Li NN, Wu ZH. Retroperitoneoscopic decortication of symptomatic peripelvic renal cysts: Chinese experience. *Urology.* 2011;78:803-807.
34. Chen Z, Chen X, Luo YC. Technical modifications of double-J stenting for retroperitoneal laparoscopic dismembered pyeloplasty in children under 5 years old. *PLoS One.* 2011;6:e23073.
35. Chertin B, Ben-Chaim J, Landau EH, et al. Pediatric transperitoneal laparoscopic partial nephrectomy: comparison with an age-matched group undergoing open surgery. *Pediatr Surg Int.* 2007;23:1233-36.
36. El-Ghoneimi A, Farhat W, Bolduc S, Bagli D, McLorie G, Khoury A. Retroperitoneal laparoscopic vs open partial nephroureterectomy in children. *BJU Int.* 2003;91:532-35.
37. Robinson BC, Snow BW, Cartwright PC, De Vries CR, Hamilton BD, Anderson JB. Comparison of laparoscopic versus open partial nephrectomy in a pediatric series. *J Urol.* 2003;169:638-40.
38. Borzi PA. A comparison of the lateral and posterior retroperitoneoscopic approach for complete and partial nephroureterectomy in children. *BJU Int.* 2001;87:517-20.