

Pendulous Urethral Stricture: Peculiarities and Relevance of Longitudinal Penile Fascio-Cutaneous Flap Reconstruction in Poor Resource Community

Abdulkadir A. Salako,¹ Abimbola O. Olajide,¹ Ademola A. Aremu,² Michael O. Afolayan,³ Ifeoluwa E. Adejare,⁴ Oyediran G. Oseni¹

¹Department of Surgery, Obafemi Awolowo University, Ile-Ife, Nigeria.

²Department of Surgery, Ladoko Akintola University Teaching Hospital, Osogbo, Nigeria.

³Department of Surgery, University of Lagos, Lagos, Nigeria.

⁴Department of Surgery, Federal Medical Centre, Owo, Nigeria.

Corresponding Author:

Abimbola O. Olajide, MD
Department of Surgery, Ladoko Akintola University Teaching Hospital, Osogbo, Nigeria.

Tel: +23 480 372 51893

Email: lajidea@yahoo.com

Received August 2012
Accepted March 2012

Purpose: To describe peculiarities of pendulous urethral stricture in South Western Nigeria and how prevalent social and environmental factors have made longitudinal distal penile island flap the preferred option for reconstruction of pendulous urethral stricture in such a poor resource community.

Materials and Methods: All patients presenting with stricture located in the pendulous urethra in 3 hospitals in south western Nigeria, over a 5 year period were interviewed and had urethral reconstruction using longitudinal distal penile fascio-cutaneous island flap under spinal anesthesia.

Results: Thirty four cases were treated by this method during this period. Complications were found in 4 patients (11.8%) which include urethrocutaneous fistula, penile skin necrosis and wound infection. All cases had satisfactory overall outcome.

Conclusion: Longitudinal penile fascio-cutaneous flap remains a viable option for a single stage repair of pendulous urethral stricture especially in poor resource communities.

Keywords: urethral stricture; urologic surgical procedures; treatment outcome; surgical flaps; postoperative complications.

INTRODUCTION

Male urethral is conventionally classified as anterior and posterior segments. Posterior urethra (within the pelvis) is constituted by the prostatic and membranous urethra while anterior part is further divided into the pendulous / penile (within the penile shaft) and the bulbar (in the perineum).⁽¹⁾ The length of pendulous urethra is critical for proper sexual activity because it has to tolerate increase in the length of phallus during turgidity. Length discrepancy caused by disease or reconstruction may lead to incongruity with subsequent deformity of the penile tissue during erection (chordee) with associated sexual dissatisfaction.^(2,3)

Wide arrays of techniques are available for management of urethral stricture but not all can be applied to pendulous urethral stricture. Resection and anastomosis, though preferred, is not favored because it causes chordee; substitution urethroplasty is therefore recommended.⁽⁴⁾ Several tissues have been used for urethral substitution either as a single or a multi-staged procedure, but no tissue is appropriate for all cases of urethral stricture disease.⁽⁵⁾ Several factors influence the choice of reconstruction technique for each case. These factors may include available facility, patients' choice, and preference of the attending surgeon. However, peculiar environmental factors can also play a significant role in the choice of methods for treatment of urethral stricture.⁽⁶⁾

We carried out this study to report the epidemiology of pendulous urethral stricture and to illustrate why longitudinal distal penile island flap reconstruction may still be the best option in poor resource communities like south-western Nigeria.

MATERIALS AND METHODS

A prospective study of cases of pendulous urethral stricture disease treated by longitudinal distal penile fascio-cutaneous island flap over a 5 year period (January 2006-December 2010) in 3 tertiary hospitals in South Western Nigeria. All the hospitals are referral centers for urological diseases in the various states. Approval was obtained from Research and Ethical Committees in the centers and informed consent was obtained from the patients before being enlisted

for the study.

Pre-operative clinical evaluation for the study was done at the outpatient unit and all the patients had longitudinal penile fascio-cutaneous island flap re-construction under spinal anesthesia by same group of surgeons. Information on age of patients, occupation, source of funding, etiology, investigation, intra-operative findings, intra-operative complications, post-operative complications and overall outcome of the treatment was collected on a proforma. The data generated was entered into the computer and analyzed using the statistical package for the social science (SPSS Inc, Chicago, Illinois, USA) version 16.0.

Operative Technique

We wash the external genitalia thoroughly with soap on the morning of surgery. The penile skin is marked to demarcate the hair bearing proximal skin thereby avoiding its inclusion in the flap. Following administration of spinal anesthesia, the patient is placed in dorsal position and skin prepped and draped to expose the genitalia and suprapubic region. Peri-operative intravenous ciprofloxacin and metronidazole is given immediately after administration of anesthesia. Penile shaft is put under traction and stabilized using 4-0 silk suture applied to the glans. Size 18F Foley's catheter is passed through the external meatus and advanced proximally to mark the stricture site. Incision is made on one side of the midline, on the ventral surface of the non-hair bearing distal penile skin adjacent the strictured urethral segment. This is deepened through the dartos layer and buck's fascia onto the tunica albuginea of the corpus cavernosum on this side. The edge of the skin and the subcutaneous tissue are elevated and dissected across the midline to the other corpus cavernosum to expose the diseased urethra. Exposure of the urethra lumen is done by longitudinal urethrotomy incision on the lateral surface of the urethra, on the contralateral side of the skin incision extended 1 cm into normal urethra distally and proximally. Foley's catheter is passed from the meatus and advanced proximally into the bladder to rule out concomitant stricture in the proximal urethral segment (Figure 1). Based on the measured urethral defect, another incision is made on the skin, some distance from the initial incision to map out the skin to be used for ure-

thral reconstruction. The length and width of this skin is based on the defect to be bridged on the exposed urethra. This incision is deepened to just below the dermis; both blunt and sharp dissections are carried out on this plane to separate the isolated skin flap on its vascularized pedicle made of the dartos fascia (Figure 2). The skin flap is flipped over unto the urethral defect and a watertight anastomosis is done with interrupted 4-0 or 5-0 Vicryl, over a size 16 or 18 French (Fr) Foley's catheter which serves as a stent (Figures 3 and 4). A layer of dartos fascia is closed over the repair to reinforce and protect the anastomosis (Figure 5). Thereafter, the skin is closed using 3-0 nylon suture with interrupted knots (Figure 6). Urine is left un-diverted in all the patients except those with pre-operative suprapubic diversion who were maintained on diversion after the surgery. Intravenous antibiotics are maintained till 48 hours post-operation and then converted to oral. Skin sutures are removed between 8 and 10 days and peri-catheter urethrography is done between 14 and 21 days to assess the neo-urethra following which urethral catheter is removed and patient is discharged to outpatient clinic thereafter (Figures 7 and 8). At 6 weeks post-operation, symptoms are re-assessed, urinary flow rate is obtained and post void residual urine measured by ultrasound.

The treatment is judged successful if the pre-operative

symptoms have subsided, post void residual urine less than 50 mL and the urine flow rate is above 10 mL/s.

RESULTS

One hundred and nine cases of urethral stricture diseases were managed in the three centers during the period of study out of which 34 patients (31.2%) had stricture located in the pendulous urethra. The ages of those with pendulous urethral disease ranged between 28 to 89 years with mean age of 53.6 years. None of the patients had insurance coverage for their treatment cost; all of the patients were self-sponsored with only 3 (< 1%) having hope of partial or full reimbursement from their employer. Etiology of the disease is as shown in Table with iatrogenic contributing the largest percentage. Thirteen of these (39.1%), resulted from urethral catheterization in the cause of treatment of medical and surgical conditions not related to the urinary system like cerebrovascular accident, severe head injury, meningitis and food poisoning. Others were due to post-operative complication of cystoscopy and prostatectomy for benign prostatic hyperplasia. Although 7 patients (20.6%) were initially diagnosed by urethrocystoscopy, the main diagnostic investigation was retrograde urethrography (Figure 6) which was done for all the patients. Nine patients (26.5%) had antegrade urethrogram in combination with

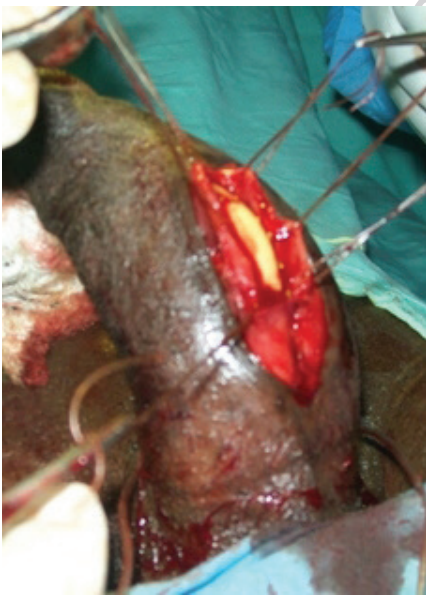

Figure 1. Urethrotomy incision exposing lumen of strictured segment with catheter in-situ.

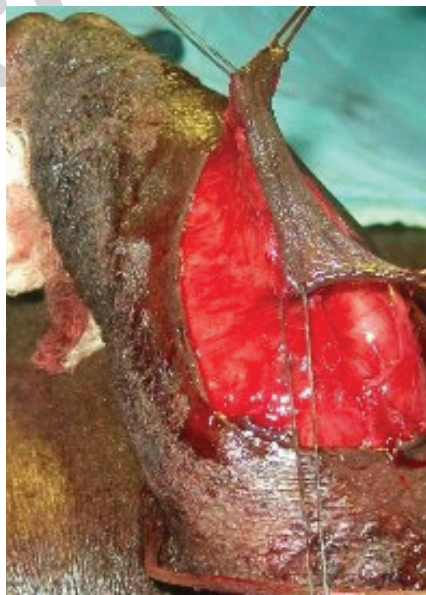

Figure 2. Longitudinal distal penile island flap on a vascularized pedicle.

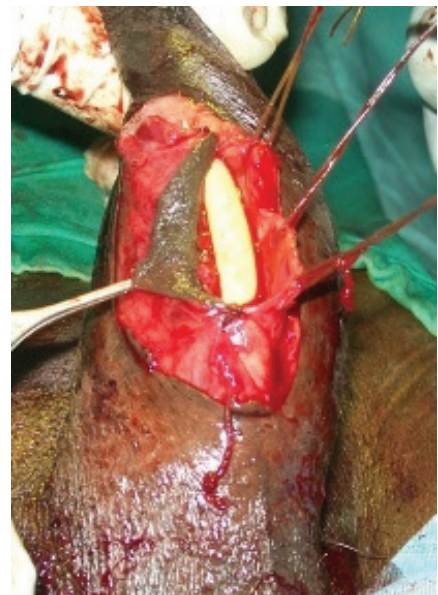


Figure 3. Anastomosis of flap to native urethra, completed on one side.

Table. Etiologies of penile urethral stricture.

Etiology	Frequency	Percentage
Iatrogenic	19	55.9
Inflammatory	11	32.4
Trauma	1	2.9
Uncertain	3	8.8

retrograde urethrogram for evaluation of the proximal urethral segment due to complete obstruction or involvement of the external meatus and fossa navicularis. All the patients had isolated pendulous urethral stricture of varied lengths except one, who had concomitant short segment stricture in the bulbar urethral segment. Thirteen patients (38.2%) had co-morbid conditions like hemiplegia from cerebrovascular accident, hypertension, diabetes and chronic obstructive airway disease.

They all had single stage urethroplasty using longitudinal distal penile island flap technique under spinal anesthesia. Intra-operative stricture length ranged from 2.5 cm to 6.5 cm with mean stricture length of 3.9 cm. The patient with concomitant bulbar urethral stricture had anastomotic repair of the bulbar urethral stricture along with substitution repair of the pendulous urethral segment. Excluding the pa-

tient with concomitant bulbar stricture, duration of surgery was observed to be directly related to the stricture length; the duration ranged between 53 and 92 minutes. Size 18 Fr Foley's catheter was used as stent in all the patients and urine diverted with suprapubic cystostomy in 23 patients (67.6%) with suprapubic cystostomy before reconstruction. Mean duration of urethral stent and suprapubic catheters were 21 days and 28 days respectively. Post-operative complications were found in 4 patients: wound infection in 2, penile skin necrosis in one and urethrocutaneous fistula in one, giving a complication rate of 11.8%. They were managed with wound dressing and antibiotics while the urethrocutaneous fistula was surgically closed 4 months after initial urethroplasty. There was no intra operative complication in any of the patients. Hospital stay ranged between 18- and 23 days with mean hospital stay of 10.8 days. Duration of follow up ranged between 12 to 36 months and all the patients had satisfactory overall outcome, none of the patients reported recurrence of his symptom(s) during the period of follow up.

DISCUSSION

Pendulous urethral stricture is not as common as strictures in other segments of the urethra. It constitutes 29.1% of all cases of urethral stricture disease seen in our centers over

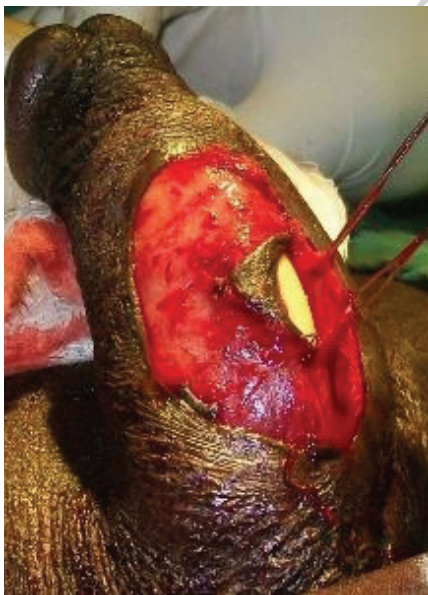

Figure 4. Ongoing anastomosis of flap to the other side of native urethra.

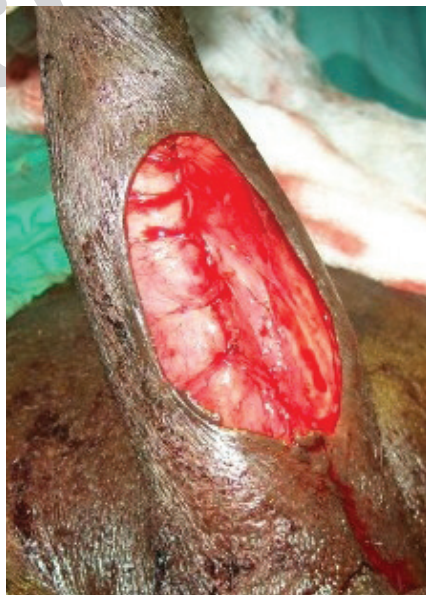

Figure 5. Reinforcement of repair with layer of dartos fascia before skin closure.

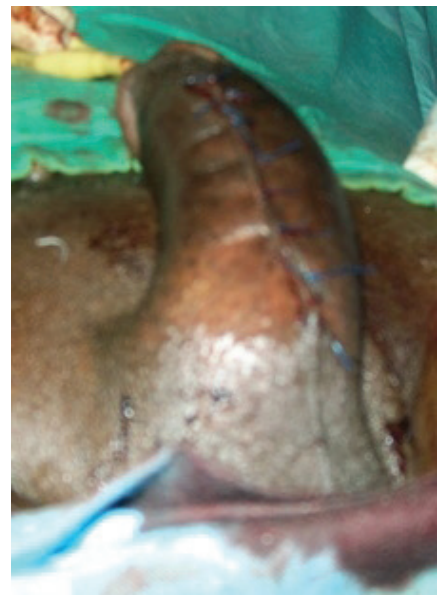

Figure 6. Penile appearance immediately after skin closure.

the 5 year period. Some other researchers have reported lower percentage of pendulous stricture in comparison with stricture in other parts of the urethra.⁽⁷⁾ Iatrogenic causes of urethral stricture usually result from procedures such as urethral catheterization and transurethral endoscopy with the former being the leading cause.^(8,9) Introduction of flexible and small caliber endoscopes coupled with diligent care for patients with indwelling catheters has reduced the incidence of iatrogenic injuries in most centers in developed world.⁽¹⁰⁾ Consideration of urethral catheterization as minor procedures may be contributory to high incidence of catheterization induced urethral stricture in our centers; it is left to the junior doctors and interns who may not be experienced in the procedure. We feel there is need to saddle more experienced doctors with this responsibility of urethral catheterization and to increase the supervision of the junior officers during the procedure.

We found urethrography adequate to confirm the diagnosis and plan repair for these patients. Information obtained on retrograde urethrogram may be limited where there is complete obstruction or when the stricture extends to involve the fossa navicularis due to obscuring of area of interest by injection device.⁽⁷⁾ In such situation we used micturating urethrography in isolation or in combination with retrograde urethrography to evaluate the stricture.

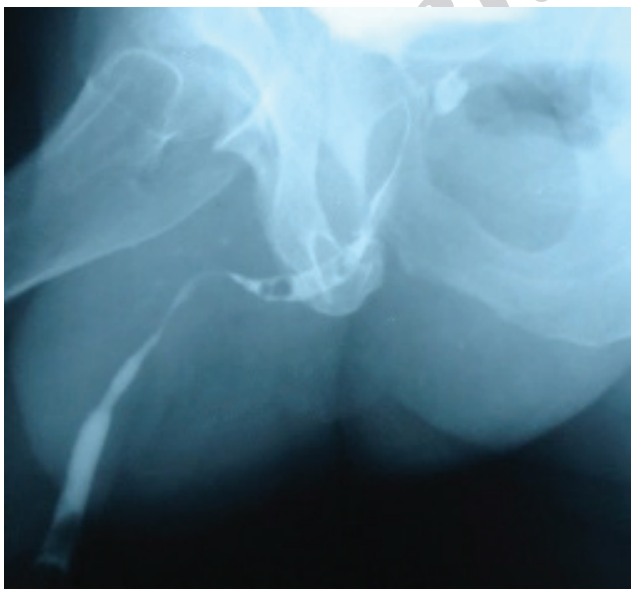

Figure 1. Pre-operative retrograde urethrogram of one of the patients.

Surgical reconstruction of pendulous urethral stricture is peculiar and challenging because of some inherent complications like tissue necrosis due to precarious vascularization, urethrocutaneous fistula and alterations in sexual functions.⁽⁵⁾ Anastomotic urethroplasty is contraindicated because it can cause chordee which will have serious consequences on the sexual functions of the penis.⁽¹¹⁾ Whatever technique is employed, the length and appearance of the penis must not be compromised and the neurovascular supply to the penis must not be affected so that the sexual function is not jeopardized.⁽¹²⁾ Although neurovascular supply of the penis is located on the dorsal and lateral part of the penis, they can be injured while raising the flap if the proper plane of dissection is not maintained. The options in pendulous urethral reconstruction are thus limited considerably to substitution techniques. Use of genital skin for urethral reconstruction is not new; it was the preferred tissue prior to the emergence of buccal mucosa.⁽⁵⁾ Although controversy exists over the use of free grafts or pedicled flaps and literature has made it hard to declare a favorite between the two: nevertheless, only few surgeons still use genital flaps.^(13,14) We propose that current interest in buccal mucosal graft should not make genital skin flap obsolete, there is need to define indications which may make either of the procedure appropriate in specific case scenarios. Unlike bulbar urethra,

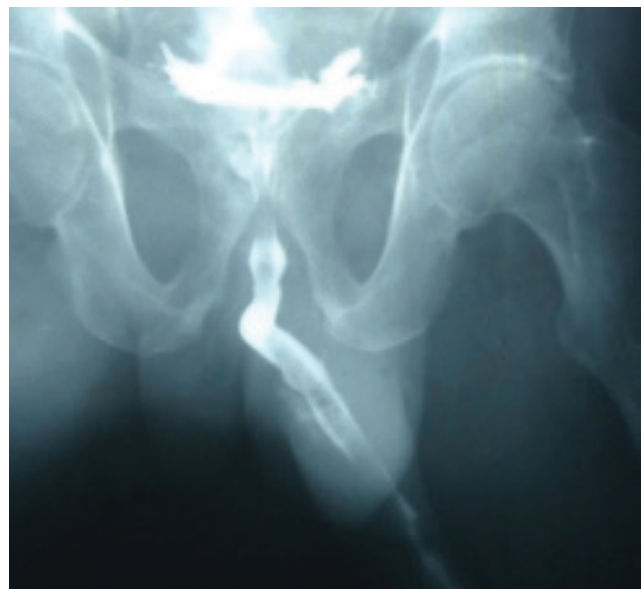


Figure 2. Post-operative peri-catheter urethrogram of same patient.

corpus spongiosum and dartos fascia of the penile urethra segment are thin and may not ensure sufficient graft support for free graft but vascularized genital flap is known to thrive in conditions with inadequate vascular supply.^(14,15) Genital skin flap reconstruction is contra indicated in patients with pendulous urethral stricture resulting from previous failed hypospadias repair or balanitis xerotica obliterans (lichen sclerosis) because genital skin is involved in these conditions.^(15,16) All the patients in this series had grossly normal penile skin considered suitable for reconstruction.

Use of regional anesthesia (subarachnoid or epidural block) for this procedure is one of the major benefits it has over buccal mucosa urethroplasty which is usually done under general anesthesia. Regional anesthesia alleviates the risks associated with general anesthesia and some patients opt for regional block when given the two options. Regional block is also preferred for patients with co-morbid conditions where there are definite risks associated with general anesthesia. This fact becomes more important in societies like ours where most hospitals have inadequate anesthetic support (equipment and personnel).^(17,18) Likewise, the cost of spinal anesthesia is approximately half of that for general anesthesia. Thus, in poor resource communities where most patients belong to the low socio-economic group, a cheaper but equally effective treatment method should be considered and embraced rather than a procedure that may add to the financial burden of these patients.⁽⁶⁾ This is buttressed by the embryonic state of the health insurance schemes which cover a very small segment of the population and only basic treatment.⁽¹⁹⁾ Engagement of 2 teams of surgeons operating simultaneously (one in the buccal cavity and the other in the perineum), is better during buccal mucosal repair otherwise, the procedure will be 'duly' prolonged.⁽¹⁴⁾ In poor resource communities, only 'big' centers can boast of more than one urologist with some centers having none. Buccal mucosal repair in such places means additional burden in a society with dearth of specialists.⁽¹⁷⁾

Complications were found in 4 patients (11.8%). Regular wound dressing and use of antibiotics based on culture sensitivity brought about complete resolution of wound infection and good re-epithelialization of the penile skin.

Occurrence of post-operative wound infection may not be surprising because urinary tract infection is common in patients with urethral stricture due to stasis of urine and previous attempts at relieve of symptoms.^(17,20) However, ability of flaps to survive in such condition is exemplified by resolution of infection without adverse effect on the flap and overall outcome. Donor site complication (penile skin necrosis) is one of the reasons advanced for superiority of buccal mucosa graft over genital skin flaps because the donor site is concealed.⁽²¹⁾ However, penile skin is 'highly forgiving' with little or no scarification after healing as depicted in this study. Comparative studies of buccal mucosal graft and penile skin flap show no significant difference in their outcome and therefore concluded that both tissues have comparable substitution profile in urethral reconstruction.^(14,22,23,24) If both methods have similar outcomes, type of anesthesia and cost of repair should argue for the use of longitudinal skin flaps in poor resource communities.

One major limitation to this study is the short duration of follow up with most patients lost between 1 and 3 years. This precludes evaluation of long term complications in the patients. We hope to carry out a comparative study of both methods in our community.

CONCLUSION

Longitudinal distal penile fascio-cutaneous island flap is still relevant for reconstruction of pendulous urethral stricture in poor resource communities. With emergence and re-emergence of newer methods, available facility and cost of reconstruction coupled with the socio-economic status of a community should be taken into consideration in selection of appropriate method for specific cases.

ACKNOWLEDGEMENT

We appreciate all the theatre nurses and anesthetists / anesthesiologists in our hospitals who supported us in carrying out this study.

CONFLICT OF INTEREST

None declared.

REFERENCES

1. Jordan GH, Rourke KF. The use of flaps in urethral reconstructive surgery. In: *Reconstructive Urethral Surgery*. Schreiter F and Jordan GH, (Eds.) 130-136, Springer; 2005. p. 130-36.
2. Raber M, Naspro R, Scapaticci E et al. Dorsal Onlay Graft Urethroplasty using Penile Skin or Buccal Mucosa for Repair of Bulbar Urethral Stricture: Results of a prospective single centre study. *Eur Urol*. 2005;48:1013-17.
3. Quartey JK. One Stage Transverse Distal Penile/ Preputial Island Flap Urethroplasty for Bulbar Stricture. *Br J Urol*. 1996;78:929.
4. Mundy AR. Management of Urethral Stricture. *Postgrad Med J*. 2006;82: 489-493.
5. Ogbonna BC. Managing many patients with urethral stricture: Cost benefit analysis of treatment option. *Br J Urol*. 1998;81:741-44
6. Fenton AS, Morey AF, Aviles R, Garcia C. Anterior urethral strictures: aetiology and characteristics. *Urology*. 2005;65:1055-58.
7. Tonkin JB, Jordan GH. Management of distal anterior urethral strictures. *Nat Rev Urol*. 2009;6:533-38.
8. Boujnah H, Abid I, Trabelsi N, Zmerli S. Iatrogenic urethral stenosis. Apropos of 100 cases. *J Chir (Paris)*. 1989;126:163-8.
9. Lentz HC Jr, Mebust WK, Foret JD, Melchior J. Urethral strictures following transurethral prostatectomy: review of 2,223 resections. *J Urol*. 1977;117:194-96.
10. Andrich DE, Greenwell TJ, Mundy AR. The problems of Penile Urethroplasty with particular reference to 2-stage reconstructions. *J Urol*. 2003;170:87-9.
11. Barbagli G, Palminteri E, Lazzeri M, Guazzoni G. Anterior urethral strictures. *BJU Int*. 2003;92:497-505.
12. Barbagli G, Palminteri E, De Stefani S, Lazzeri M. Penile urethroplasty. Techniques and outcomes using buccal mucosa grafts. *Contemp Urol*. 2006;18:25-33.
13. Dubey D, Vijjan V, Kapoor R et al. Dorsal Onlay Buccal Mucosa versus Penile Skin Flap Urethroplasty for Anterior Urethral Strictures: Results from a Randomized Prospective Trial. *J Urol*. 2007;178:2466-69.
14. Barbagli G, De Angelis M, Palminteri E, Lazzeri M. Failed hypospadias repair presenting in adults. *Eur Urol*. 2006;49:887-94.
15. Depasquale I, Park AJ, Bracka A. The treatment of balanitis xerotica obliterans. *BJU Int*. 2000;86:459-65.
16. Mungadi IA, Ntia IO. Management of "watering can" perineum. *East Afr Med J*. 2007;84:283-86.
17. Quattara K, Koungoulba MB, Cisse C. Current status of urethral stricture in Africa/Apropos of 72 cases. *Ann Urol*. 1990;24:278-92.
18. Obianuju Nnamuchi. The Nigerian Social Health Insurance System and the Challenges of Access to Health Care: An Antidote or a White Elephant? *Med and Law*. 2009;28:125-66.
19. Olajide AO, Salako AA, Aremu AA, Eziyi AK, Olajide FO, Banjo OO. Complications of Transverse Distal Penile Island Flap Urethroplasty of Complex Anterior Urethral Stricture. *Urol J*. 2010;7:178-82.
20. Barbagli G, Palminteri E, De Stefani S, Lazzeri M. Harvesting buccal mucosal grafts. Keys to success. *Contemp Urol*. 2006;18:17-24.
21. Alsikafi NF, Eisenberg M, McAninch JW. Long-term outcomes of penile skin graft versus buccal mucosal graft for substitution urethroplasty of the anterior urethra. *J Urol*. 2005;173:87.
22. Gozzi C, Pelzer AE, Bartsch G, Rehder P. Genital free skin grafts as dorsal onlay for urethral reconstruction. *J Urol*. 2006;175:38.
23. Claasen F, Wentzel S. The Treatment of Complex Urethral Stricture Using Ventral Onlay Buccal Mucosa Graft or Ventral Onlay Penile Skin Island Flap Urethroplasty: A Prospective Case Series. *Afr J Urol*. 2011;17:79-84.