

Transumbilical Laparoendoscopic Single-Site Decortication of Peripelvic Renal Cyst: A Case Report

Yao He, Zhi Chen, Xiao-Long Fang, Yan-Cheng Luo, Peng-Yang Dai, Miao-Long Lu, Xiang Chen

Department of Urology,
Xiangya Hospital, Central South
University, Changsha 410008,
China.

Corresponding Author:

Xiang Chen, MD
Department of Urology, Xiangya
Hospital, Central South University,
No. 87 Xiangya Road Changsha
410008, China.

Tel: +86 013874808998
E-mail: cxiang1007@126.com

Received March 2013
Accepted February 2014

Keywords: kidney; cyst; laparoscopy; methods; umbilicus; kidney diseases; cystic.

INTRODUCTION

Recently, laparoendoscopic single-site surgery (LESS) has been introduced and represents the latest evolution in minimally invasive therapeutic techniques.⁽¹⁾ Several studies have demonstrated that it is a safe and effective therapy for many urological diseases.⁽²⁻⁴⁾ However, LESS decortication for peripelvic cyst is still an infrequently described technique. In this report, we describe a case of peripelvic cyst that was successfully managed by transumbilical LESS decortication.

CASE REPORT

A 31-year-old female presented with recurrent left flank pain. Abdominal ultrasonography detected a left renal cyst. A computed tomography (CT) scan, with delayed views, identified a left peripelvic cyst measuring 7.5×7.0×6.8 cm, which was not communicating with the collecting system (Figure 1A). Retrograde pyelography (RP) also demonstrated the cyst was not in communication with the collecting system. She was managed by transumbilical LESS decortication. Informed consent was obtained before the surgery.

Surgical Technique

After induction of general anesthesia, a 5 French (F) open-ended ureteral catheter was placed by cystoscope for instillation of methylene blue. Subsequently, the patient was placed in a 45° lateral decubitus position. A TriPort Access System was introduced through a 2 cm semi-

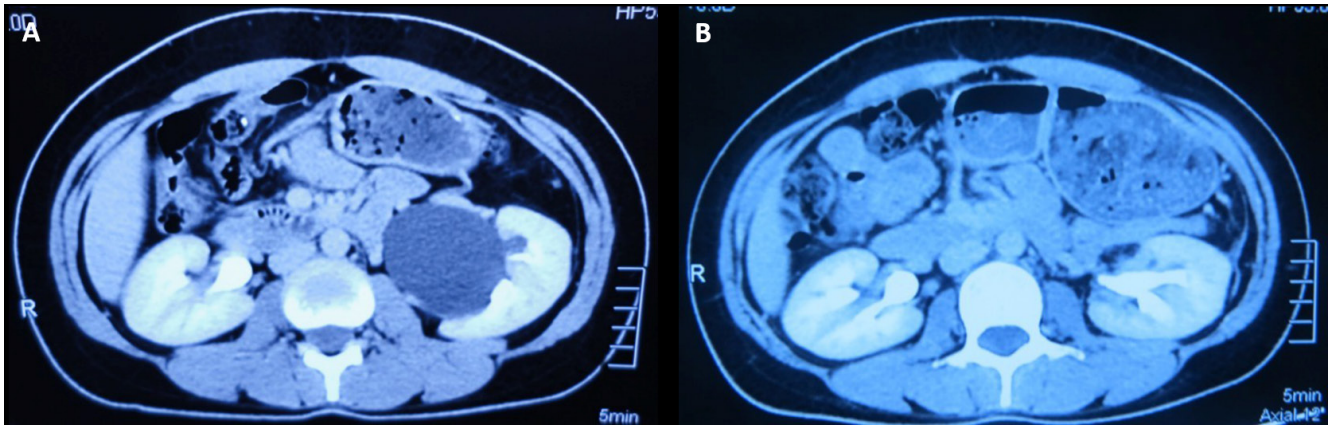


Figure 1. Preoperative and postoperative computed tomography scans; (A) preoperative computed tomography scan demonstrates a left peripelvic renal cyst, (B) postoperative computed tomography scan at the 3-month follow-up demonstrated no cyst recurrence.

circular periumbilical incision (Figure 2A). Harmonic scalpel was used for incising the line of Toldt and the descending colon was mobilized and reflected medially to expose the kidney. After carefully clearing away the perinephric fat to expose the renal pelvis, the renal vessels were isolated and the peripelvic cyst was exposed. The cyst was incised, and fluid was carefully aspirated for cytologic examination. Most of the cyst wall was excised and sent for histopathological examination (Figure 2B). Fulguration was not performed to reduce the chance of fistula formation with the collecting system and major renal vessels. A drain was not placed.

The operative time was 122 min and the estimated blood loss was 20 mL. No intraoperative or postoperative complications occurred. The postoperative analgesia was not needed. The patient resumed oral food intake on day 2 and was discharged on day 3, postoperatively. All cytology and

cyst wall pathologic findings were negative for malignancy. At 3-month follow-up, a CT scan demonstrated no cyst recurrence (Figure 1B). The patient was very satisfied because she remained symptom free and the umbilical scar was barely visible (Figure 2C).

DISCUSSION

Currently, laparoscopic decortication has substituted for open technique and is admitted as a standard treatment of symptomatic peripelvic cysts. A number of reports have also been published, documenting successful results of laparoscopic decortications using either a transperitoneal or retroperitoneal route.⁽⁵⁻⁹⁾ Nevertheless, with increasing experience in the laparoscopic environment, surgeons are still working on ways to further improve cosmetic outcomes and minimize surgical morbidity. This trend has led to the development of new techniques such as mini-laparoscopic

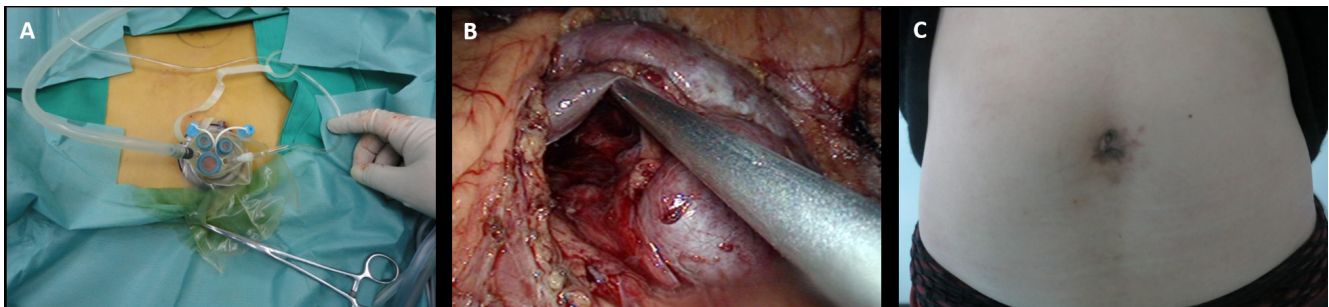


Figure 2. (A) TriPort Access System was introduced through a 2 cm semicircular periumbilical incision, (B) neither additional cysts nor any areas suspicious for carcinoma were detected in the interior of the cavity, (C) the umbilical scar is barely visible at postoperative day 30.

surgery and LESS. However despite widespread reports of LESS for simple renal cyst decortication, LESS decortication for peripelvic cyst is still an infrequently described technique. Compared with LESS decortication of simple renal cyst, LESS peripelvic cyst decortication faces more technical challenges due to its complexity and multilobulated feature of cyst and the intimate association to the renal hilar structures. Thus, the surgeon should not only be familiar with the procedure of LESS but also have experience in LESS urinary tract reconstruction in response to the inadvertent collecting system injury.

We had completed over 200 cases of LESS procedures including over 50 cases of LESS urinary tract reconstruction such as dismembered pyeloplasty, ureterolithotomy and ureteroureterostomy before beginning LESS peripelvic cyst decortication. Moreover, using a combination of the high-quality CT imaging and retrograde pyelography preoperatively is essential to determine the possible number and configuration of cysts and to rule out collecting system communications. It is also necessary to inject methylene blue through an open-ended retrograde ureteral catheter intraoperatively that can help surgeons distinguish the collecting system from cysts, and make an early diagnosis and timely treatment of unsuspected collecting system injury.

CONCLUSION

In conclusion, the transumbilical LESS decortication is technically feasible, and can be considered as potential alternative for conventional laparoscopic surgery.

ACKNOWLEDGMENTS

Yao He and Zhi Chen contributed equally to this work.

CONFLICT OF INTEREST

None declared.

REFERENCES

1. Kaouk JH, Autorino R, Kim FJ, et al. Laparoendoscopic single-site surgery in urology: worldwide multi-institutional analysis of 1076 cases. *Eur Urol.* 2011;60:998-1005.
2. Cindolo L, Gidaro S, Tamburro FR, Schips L. Laparo-endoscopic single-site left transperitoneal adrenalectomy. *Eur Urol.* 2010;57:911-4.
3. Fadahunsi AT, Sanford T, Linehan WM, Pinto PA, Bratslavsky G. Feasibility and outcomes of partial nephrectomy for resection of at least 20 tumors in a single renal unit. *J Urol.* 2011;185:49-53.
4. Dasgupta P. Laparoendoscopic single-site pyeloplasty: a comparison with the standard laparoscopic technique. *BJU Int.* 2011;107:816.
5. Yoder BM, Wolf JS Jr. Long-term outcome of laparoscopic decortication of peripheral and peripelvic renal and adrenal cysts. *J Urol.* 2004;171:583-7.
6. Doumas K, Skrepetis K, Lykourinas M. Laparoscopic ablation of symptomatic peripelvic renal cysts. *J Endourol.* 2004;18:45-8.
7. Rassweiler J, Frede T, Henkel TO, Stock C, Alken P. Nephrectomy: A comparative study between the transperitoneal and retroperitoneal laparoscopic versus the open approach. *Eur Urol.* 1998;33:489-96.
8. Camargo AH, Cooperberg MR, Ershoff BD, Rubenstein JN, Meng MV, Stoller ML. Laparoscopic management of peripelvic renal cysts: University of California, San Francisco, experience and review of literature. *Urology.* 2005;65:882-7.
9. Micali S, Pini G, Sighinolfi MC, De Stefani S, Annino F, Bianchi G. Laparoscopic simultaneous treatment of peripelvic renal cysts and stones: case series. *J Endourol.* 2009;23:1851-6.