

Hand-Assisted, Conventional and Laparoscopic Single-Site Surgery for Partial Nephrectomy without Ischemia Using a Microwave Tissue Coagulator

Tetsuo Nozaki, Yoshihiro Asao, Tomonori Katoh, Kenji Yasuda, Hideki Fuse

Department of Urology, Graduate School of Medicine and Pharmaceutical Sciences for Research, University of Toyama, 2630 Sugitani, Toyama 930-0194, Japan.

Correspondence Author:

Tetsuo Nozaki, MD
Department of Urology, Graduate School of Medicine and Pharmaceutical Sciences for Research, University of Toyama, 2630 Sugitani, Toyama 930-0194, Japan.

Tel: +81 76434 2281
Fax: +81 76434 5039
E-mail: nozaki0921@yahoo.co.jp

Received May 2013
Accepted January 2014

Purpose: We report our experience of minimally invasive partial nephrectomy without ischemia using a microwave tissue coagulator (MTC) for hand-assisted laparoscopic partial nephrectomy (HALPN), conventional laparoscopic partial nephrectomy (CLPN), and laparoscopic single-site surgery for partial nephrectomy (LESSPN). We retrospectively compared the results of these techniques to better define the individual role and the benefits.

Materials and Methods: From July 2005 to September 2012, 28 patients with small and exophytic renal tumors underwent HALPN ($n = 12$), CLPN ($n = 10$) and LESSPN ($n = 6$). In these procedures, the surgeon used an MTC for circumferential coagulation around the tumor. After coagulation, the tumor was resected without renal pedicle clamping.

Results: The mean operative time was 259, 194 and 174 min for the HALPN, CLPN and LESSPN groups respectively. Two patients (one in HALPN group and one in LESSPN group) converted to laparotomy due to an inability to maintain hemostasis; however, there were no conversions to ischemic partial nephrectomy or radical nephrectomy. No differences between HALPN, CLPN and LESSPN were noted in terms of estimated blood loss, measured analgesic requirements, outcomes, or complications.

Conclusion: We believe that these techniques are feasible and that they minimize the risk of unexpected collateral thermal damage by appropriate MTC needle puncture. When deciding to use HALPN, CLPN or LESSPN, our findings suggest that the choice of surgical approach should depend on the patient's individual circumstance.

Keywords: carcinoma, renal cell; surgery; laparoscopy; microwaves; nephrectomy; organ sparing treatments; surgical procedures; minimally invasive; methods.

INTRODUCTION

Laparoscopic partial nephrectomy (LPN) is becoming a popular treatment option for small renal tumors because it offers better cosmesis and reduces postoperative pain.^(1,2) As LPN gains widespread acceptance, there is a great need for a novel surgical technique to be reliable and provides bloodless resection of the renal parenchyma without damaging the residual renal tissue.⁽³⁾ In Japan, microwave tissue coagulators (MTCs) are widely used for LPN.^(4,5) In LPN, the MTC is applied peripherally in the healthy parenchyma surrounding the tumor, with circumferential punctures that produce coagulation of a conical-shaped portion of tissue. Subsequently, a wedge resection can be achieved in the bloodless field without renal pedicle clamping.

The aim of this study was to compare the various techniques of LPN such as hand-assisted laparoscopic surgery for PN (HALPN), conventional LPN (CLPN) and laparoendoscopic single-site surgery (LESS) for PN (LESSPN) as well as their outcome in terms of operative time, postoperative pain and surgical site infection.

MATERIALS AND METHODS

A retrospective study was carried out including patients operated on at Toyama University Hospital from July 2005 to September 2012. Of the 28 patients included in the study, 12 were in the HALPN group, 10 were in the CLPN group and 6 were in the LESSPN group. We began our study using HALPN and then we gradually shifted to CLPN and LESSPN; indeed, from 2005-2008, 2007-2012 and 2011-2012, we performed HALPN, CLPN and LESSPN, in that order. Choice of a particular surgical approach was based on the surgeon's clinical judgment, taking into consideration patient and clinical factors. During this study, a single surgeon performed all preoperative counseling and surgery. The demographic characteristics are summarized in Table 1. All renal tumors were categorized according to the nephrometry score determined from preoperative imaging as low, moderate and high complexity.⁽⁶⁾ Each group was comparable with regard to age, body mass index, and nephrometry scoring. In the LESS group, all patients underwent surgery after obtaining Institutional Review Board approval from the ethical committee and informed patient

consent. Both transperitoneal and retroperitoneal approaches were taken at the surgeon's discretion. All lesions were suspected of renal cell carcinoma (RCC), as were peripherally located and exophytic renal tumors with at least 5 mm of normal renal tissue between the tumor margin and the collecting system. Outcome was assessed in the form of operative time, blood loss, in-hospital frequency of analgesia administration and overall complication rates. All complications were carefully graded using the modified Clavien system.⁽⁷⁾ Renal function was determined by serum creatinine (mg/dL) measurement and postoperative serum creatinine was measured at 7 postoperative days.

Statistical Analysis

Non-parametric statistical analyses (Mann-Whitney *U* test for two-way, and Kruskal-Wallis test for three-way analyses) were used for statistical analyses.

HALPN Surgical Technique

The HALPN technique used has been described in detail elsewhere.⁽⁸⁾ Briefly, HALPN was carried out as follows. Under general anesthesia, each patient was placed in a 70-degree lateral decubitus position. After an approximately 7 cm skin incision was made around the umbilicus, a hand-assisted device, GelPort (Applied Medical, Rancho Santa Margarita, CA) and two or three additional ports are placed. The kidney was mobilized within Gerota's fascia with the aid of the surgeon's hand. The Gerota's fascia was incised to expose the tumor and surrounding normal renal capsule. The renal pedicle was not dissected. Intra-abdominal ultrasound scanning was used to confirm the tumor shape, size and the depth of the tumor base. The incision line, which was 1 cm from the tumor margin, was marked circumferentially on the renal capsule using electrocautery scissors. Next, the surgeon grasped the surgical handpiece of the MTC (Microtaze OT-110M, Aswell Co., Osaka, Japan), which was originally designed for open surgical procedure, and introduced it through the GelPort with the coaxial flexible cable. The MTC causes the thermal coagulation of tissues using microwave energy (2,459 MHz). This energy is transmitted from a generator through a coaxial cable to a probe, which consists of a handpiece and a needle-like electrode. The rapid oscillation of water particles caused by microwaves results in a high temperature and induces cone-shaped tissue coagulation around the needle that is 7 to 10

Table 1. Demographic characteristics of study group.

Variables	HALPN	CLPN	LESSPN	P
Age (years)	67.2 ± 10.2	53.3 ± 15.2	56.3 ± 18.3	.121
BMI (kg/m ²)	23.9 ± 3.1	25.5 ± 3.5	23.1 ± 0.6	.581
Tumor size (cm)	1.9 ± 0.42	2.8 ± 1.5	1.8 ± 0.8	.097
Imperative case (no.)	2.0	0.0	1.0	.484
Nephrometry sum	5.08 ± 1.31	5.00 ± 1.09	5.16 ± 0.98	.584
Low, 4-6 score (%)	10 (83.3)	9 (90)	6 (100)	---
Medium, 7-9 score (%)	2 (17.7)	1 (10)	0 (0.0)	---
High, 10-12 score (%)	0 (0.0)	9 (0.0)	0 (0.0)	---

Keys: BMI, body mass index; HALPN, hand-assisted laparoscopic partial nephrectomy; CLPN, conventional laparoscopic partial nephrectomy; LESSPN, laparoendoscopic single-site surgery for partial nephrectomy.

mm in width without carbonization. The needle applicator consists of a 10-, 15-, or 20 mm long electrode. The length of antenna needle inserted changes depending on the depth of coagulation. The surgical handpiece of MTC could easily be inserted through the GelPort, but attention was needed to avoid injuring other organs. Needle puncture was performed every 7 to 10 mm along the demarcation line. The direction and angle of the needle puncture could be easily and precisely changed in a timely manner depending on the site of coagulation. Microwave coagulation was carried out at 75 W for 45 sec, followed by 15 sec of dissociation. After coagulation, the tumor rose from the kidney and the base of the tumor was resected using a combination of laparoscopic scissors and blunt finger dissection. The excised tumor was removed through the GelPort, and biopsies from the tumor bed were sent for frozen-section study to confirm complete tumor removal. Indigo carmine (indigotindisulfonate sodium) was intravenously injected to investigate the presence of urine leakage. After ensuring that there was no further bleeding from the tumor bed, a drainage tube was placed around the tumor bed.

CLPN Surgical Technique

At the beginning of the operation, four to five trocars were inserted transperitoneally or retroperitoneally. After tumor exposure and intra-abdominal ultrasound examination, a laparoscopic MTC probe (Microtaze OT-110M, Aswell Co., Osaka, Japan) that bends at its distal near-object end was introduced through the 5 mm port. Using the bendable laparoscopic MTC probe, microwave coagulation was applied peripherally to the healthy parenchyma surrounding

the tumor, with circumferential punctures producing coagulation of a conical-shaped portion of tissue (Figure). Subsequently, the base of the tumor was resected using a combination of conventional 5 mm laparoscopic scissors and blunt dissection with a laparoscopic aspirator without renal pedicle clamping. The specimen was placed in the laparoscopic bag and retrieved through the abdominal incision. Subsequently, the procedure was performed the same as in HALPN.

LESSPN Surgical Technique

The LESSPN technique used has been described in detail elsewhere.⁽⁹⁾ Briefly, LESSPN was carried out as follows. Through the retroperitoneal approach, a 3 cm transverse skin incision was made just below the tip of the 12th rib, and the extraperitoneal space was carefully dissected with the index finger. The retroperitoneoscopic working space was dilated using a Preperitoneal Dissector Balloon (PDB1000; Covidien, Mansfield, MA, USA) under the direct vision of a laparoscope. Through the transperitoneal LESSPN approach, to enhance the cosmetic result, we developed a unique intraumbilical technique whereby the umbilicus was completely extroflexed and a skin incision of approximately 3 cm in length was made longitudinally. After subcutaneous tissue dissection and fascial incision, the peritoneum was incised. Next, a LapProtector™ (Hakko Medical Industry, Tokyo, Japan) was set up through the small incision. The LapProtector™ offers wound protection and 360° of atraumatic wound retraction, which was maximized in order to pass surgical instruments into the abdominal cavity. Then, an EZ access™ (Hakko Medical Industry, Tokyo,

Table 2. Perioperative parameters, outcomes and complications.

Variables	HALPN (n = 12)	CLPN (n = 10)	LESSPN (n = 6)	P
Mean operative time (min)	259 ± 75.2	194 ± 53.5	174 ± 13.8	.064
Mean blood loss (mL)	298 ± 69	48 ± 6	892 ± 40.0	.128
Complications* (no.)				
Wound dehiscence	1.0	0.0	0.0	
Urine leakage**	0.0	0.0	1.0	
Frequency of analgesic use (no.)	1.16 ± 1.06	1.5 ± 1.37	1.16 ± 0.57	.831
Delay in resuming normal activity (days)	1.3 ± 0.4	1.1 ± 0.4	1.0	.264
Delay in resuming normal diet (days)	2.1 ± 0.5	2.3 ± 0.8	1.5 ± 0.6	.055
Postoperative/preoperative serum creatinine (%)	106.0 ± 10.5	114.3 ± 13.8	112.4 ± 19.2	.451

Keys: HALPN, hand-assisted laparoscopic partial nephrectomy; CLPN, conventional laparoscopic partial nephrectomy; LESSPN, laparoendoscopic single-site surgery for partial nephrectomy.

* Complications classified using the modified Clavien System.

** Urine leakage requiring ureteral stent.

Japan), a silicone cap designed to cover the outer ring of the LapProtector™, was set up in order to maintain the pneumoperitoneum. The EZ access™ allows the insertion of multiple trocars (three to four) freely into the abdominal cavity through its large surface area (5 cm diameter). The trocars could be positioned anywhere within the silicone cap; they were separated as far as possible from each other on the silicone cap, which more readily facilitated the spacing of instruments. The silicone cap is flexible and self-sealing; it acts as a pseudoabdominal platform for the trocars. If the surgeon wanted to change the trocar position and/or trocar size, the pore on the silicone cap was resealed afterwards. At the beginning of the operation, three 5 mm trocars were inserted into the silicone cap before it was mounted onto the LapProtector™. The abdominal cavity was explored using a flexible 5 mm 0° Olympus high-definition laparoscope (Tokyo, Japan). Except for a reusable bendable laparoscopic MTC probe, all other instruments were conventional straight laparoscopic instruments, including a bipolar grasper, laparoscopic scissors, and a suction device. After exposure of the tumor, the 5 mm trocar was replaced with a 12 mm trocar to enable intra-abdominal laparoscopic ultrasound scanning. After ultrasound examination, the 12 mm trocar was replaced with the 5 mm trocar. There was no leakage of the pneumoperitoneum during multiple trocar exchanges using the EZ access™. Using the bendable laparoscopic MTC probe, the direction and angle of needle puncture could be easily and precisely changed in a timely

manner depending on the site of coagulation, even with the LESS procedure. After coagulation, the base of the tumor was resected using a combination of conventional 5 mm laparoscopic scissors and blunt dissection using a laparoscopic aspirator under normal renal perfusion. The excised specimen can be removed by simply removing the silicone cap from the proximal ring.

RESULTS

The perioperative and postoperative variables are detailed in Table 2. No significant differences were noted in the operative time, estimated blood loss and complication rates. There were two conversions to laparotomy (one in the HALPN group and one in the LESSPN group) as a result of an inability to maintain hemostasis; however, there were no conversions to ischemic partial nephrectomy or radical nephrectomy. With the exception of these two patients, complete hemostasis was achieved; therefore, the application of bolster, sealant or parenchymal stitches/collecting system closure was not necessary. The in-hospital frequency of analgesia administration was comparable between groups. All patients resumed oral intake and were ambulatory within 2 days. No postoperative complications such as delayed hemorrhage were observed in follow-up computed tomography (CT) imaging. However, one patient (16.7%) in the LESSPN group developed urinoma formation, which was resolved with percutaneous drainage and ureteral stent placement. Wound infection and dehiscence

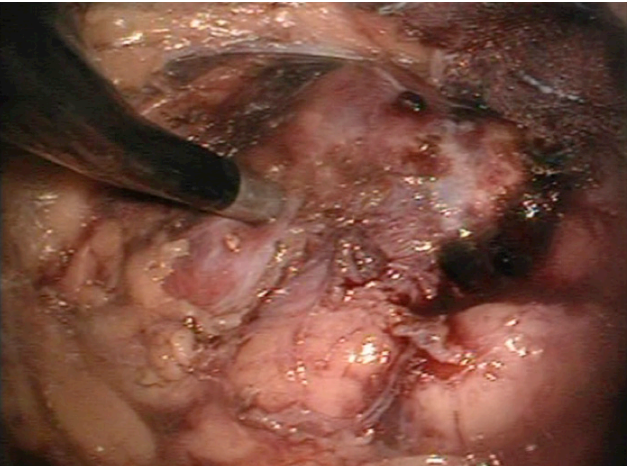


Figure. The microwave tissue coagulator is applied peripherally in the healthy parenchyma surrounding the tumor.

occurred in one patient (8.3%) in the HALPN group in the perioperative period, which was resolved with conservative treatment. The mean postoperative/preoperative creatinine (mg/dL) was 1.06, 1.14, and 1.12 for the HALPN, CLPN and LESSPN groups ($P = .451$), respectively.

In LESSPN, the EZ access, with its relatively large diameter (5 cm), facilitated the triangulation and spacing of instruments, despite actually operating through a smaller 3 cm skin incision. Even in LESS surgery, internal and external instrument collision did not prevent the completion of the procedures. The abdominal view after the unique intraumbilical technique revealed an invisible umbilical scar. During the follow-up period, we observed one recurrence in the HALPN group despite a 100% negative margin rate. This patient had previously undergone contralateral nephrectomy for RCC. Two suspicious renal tumors were discovered in the remaining lower and middle pole kidney in follow-up imaging studies. Both tumors were resected simultaneously, and intraoperative frozen section analysis and final pathologic examination revealed negative margins. However, local recurrence and pulmonary metastases developed 8 months after HALPN. With the exception of this case, no local recurrence or distant metastases occurred during our midterm follow-up periods (mean 42.6 months post procedure).

DISCUSSION

Although the MTC is a useful instrument that enables sur-

geons to perform LPN without renal pedicle clamping, one possible drawback of the MTC may be collateral thermal damage to surrounding structures, such as arteries, veins and the collecting system as a result of inadequate coagulation. This technique is better suited for polar tumors or small exophytic tumors located on the lateral convexity of the kidney. The indication for this procedure must be limited to small (< 4 cm) exophytic renal tumors with adequate intervening renal parenchyma as far as the renal collecting system (< 5 mm). Therefore, this technique cannot be applied to central or hilar tumors. While limiting the indication, as a result of inappropriate needle puncture, unexpected postoperative complications, such as postoperative urinoma formation, pelvicaliceal stenosis, renal infarction or renal arteriovenous fistula, were reported.^(5,10) Considering that these complications have rarely been documented in open partial nephrectomy (OPN) using the MTC, this should be recognized as a potential risk associated with the laparoscopic approach. The MTC probe, which was designed for purely laparoscopic surgery, is rigid and its movement is restricted by the fixed port site.⁽¹¹⁾ To insert the needle in the appropriate direction, it is mandatory to fully mobilize the antenna needle in the intraperitoneal space as in standard open surgery without stress. To allow the safe and widespread use of this apparatus in LPN, further innovative methods for precise needle puncture are needed. In an attempt to provide more precise and accurate coagulation, we propose the application of an “open” MTC for HALPN.⁽⁸⁾ Hand-assisted laparoscopic surgery (HALS) is a unique surgical approach that has several unique advantages (e.g., surgeons can insert a hand into the abdomen to achieve tactile sensation, three-dimensional orientation, hemorrhage control and improved organ retraction and removal, analogous to laparotomy.^(12,13) In HALPN using the MTC, needle puncture in the appropriate direction was quite easy and could be precisely changed in a timely manner. Moreover, digital dissection allows better access and quick isolation of the tumor. As such, this technique does not require advanced laparoscopic skill. In our series, HALPN was an effective procedure, and all measurable perioperative outcomes are equivalent, with no obvious disadvantage for HALPN. Although not significant, the longer operative time observed for HALPN group potentially reflects under-

lying bias due to the fact that HALPN patients were more likely to be undergoing surgery during the early experience of using the MTC. However, in one patient, wound infection and dehiscence occurred. The primary disadvantage of HALPN compared to CLPN and LESSPN is the larger incision. A large series summarizing the specific complications of HALS has been reported.⁽¹⁴⁻¹⁶⁾ These reports suggested that postoperative HALS incision site complications, including wound infections and hernias, occur more often than with standard laparoscopy. An incisional hernia is often associated with significant morbidity and usually requires an additional procedure for its repair, which is associated with recurrence. Various risk factors for the development of postoperative complications at the HALS incision site have been proposed, including patient factors (smoking, diabetes, renal failure and obesity), wound factors (re-incision, midline incisions and wound infection), external factors (radiation and chemotherapy) and operative variables (prolonged operative time and lack of antibiotics). The surgeon should take these into account when considering HALPN, and should bear these postoperative complications in mind during the surgery.

To increase the cosmetic result of the surgery and to minimize patient discomfort, several authors successfully utilized LESSPN.⁽¹⁷⁻¹⁹⁾ In this study, we attempted LESSPN without ischemia using the MTC. It is of note that the incidence of benign disease is high (approximately 30%) in small asymptomatic renal tumors.^(20,21) The cosmetic outcome is a significant issue and a lower morbidity approach should be strongly recommended. CLPN is routinely performed using more than four ports of entry into the abdomen. The use of multiple puncture sites, however, may decrease patient cosmetic satisfaction and could increase trocar-associated complications, such as trocar-site bleeding, herniation of viscera and wound infection. In this setting, LESSPN could play a principal role in increasing patient satisfaction because LESS avoids the psychological trauma associated with multiple scars. Despite recent technological advances in LESS instrumentation and optics, there are concerns associated with technical difficulties, including internal or external instrument collisions or difficulties in driving the instruments. In order to allow the safe use of this apparatus in LESSPN, further innovative methods for

precise needle puncture are needed. In our LESSPN group, we used the EZ access port and bendable MTC probe for PN without ischemia. Using these new types of devices for LESSPN, the surgeon did not encounter internal or external instrument collisions or difficulties in driving the instruments, problems that were typical of LESS procedures. The analysis of our first six LESSPNs is encouraging and compares favorably with other LESSPN without ischemia series. Kaouk and colleagues published their experience with five cases of LESSPN without ischemia using a harmonic scalpel.⁽¹⁷⁾ The mean operating time was 160 min, with a mean estimated blood loss of 420 mL. They converted to standard laparoscopy in one patient to control parenchymal bleeding. Cindolo and colleagues published their experience with six cases of LESSPN without ischemia using a laparoscopic vessel sealing instrument (LigaSure Advance, Covidien, Mansfield, MA).⁽¹⁸⁾ The average tumor size was 2.1 cm (range 1.0-3.5 cm) and mean operating time was 148 min (range 115-180 min), with a mean estimated blood loss of 201 mL. They added one additional 5 mm port in two cases to suture the renal parenchyma and for liver or tissue retraction. They converted to standard laparoscopy (adding two 5 mm ports) in one case to control parenchymal bleeding. Our procedure provides optimal hemostasis, making LESSPN easier and possible without renal pedicle clamping or hemostatic sutures. This technique should only be attempted in select patients who have favorable tumor anatomic features and should be performed by an experienced laparoscopic team. The only recognized benefit of LESS compared with conventional laparoscopy is improved cosmesis. The other potential patient benefits such as a decrease in postoperative pain and recovery time are equivalent, with no obvious advantage for LESSPN. However, in our LESSPN group, one patient (a 22-year old female) with Von Hippel-Lindau disease was included. The retroperitoneal LESS approach was chosen to minimize the intra-abdominal adhesion and limit abdominal wall trauma. We postulate that the younger patient subset, which was more likely to undergo surgery for benign indications and more likely to undergo repeat surgery for recurrence disease, received the greatest benefit from LESS surgery.

This study has several limitations. First, the study is retrospective and is susceptible to all limitations and biases

inherent in a retrospective design. Second, we used the frequency of analgesia administration as a surrogate for measuring postoperative pain. The optimal means of assessing postoperative pain would involve using a visual analog scale as well as measuring analgesic requirements. Third, the study includes a relatively small number of patients and a relatively short follow-up period. Further studies are necessary to investigate the actual benefits of these procedures in performing minimally invasive nephron sparing surgery.

CONCLUSION

In conclusion, HALPN, CLPN and LESSPN without ischemia by using MTC were feasible and safe. Our preliminary findings can be used to better counsel patients when deciding between a HALPN versus CLPN or LESSPN approach. The surgical outcomes were not significantly different and the choice of surgical approach therefore depends on the patient's individual circumstance.

CONFLICT OF INTEREST

None declared.

REFERENCES

- Campbell SC, Novick AC, Belldegrun A, et al. Guideline for management of the clinical T1 renal mass. *J Urol*. 2009;182:1271-9.
- Breau RH, Crispin PL, Jenkins SM, Blute ML, Leibovich BC. Treatment of patients with small renal masses: A survey of the American Urological Association. *J Urol*. 2011;185:407-13.
- Breda A, Finelli A, Janetschek G, Porpiglia F, Montorsi F. Complications of laparoscopic surgery for renal masses: prevention, management, and comparison with the open experience. *Eur Urol*. 2009;55:836-50.
- Furuya Y, Tsuchida T, Takihana Y, Araki I, Tanabe N, Takeda M. Retroperitoneoscopic nephron-sparing surgery of renal tumor using a microwave tissue coagulator without renal ischemia: comparison with open procedure. *J Endourol*. 2003;17:53-8.
- Terai A, Ito N, Yoshimura K, et al. Laparoscopic partial nephrectomy using microwave tissue coagulator for small renal tumors: usefulness and complications. *Eur Urol*. 2004;45:744-8.
- Kutikov A, Uzzo RG. The R.E.N.A.L. nephrometry score: a comprehensive standardized system for quantitating renal tumor size, location and depth. *J Urol*. 2009;182:844-53.
- Dindo D, Demartines N, Clavien PA. Classification of surgical complications: a new proposal with evaluation in a cohort of 6336 patients and results of a survey. *Ann Surg*. 2004;240:205-13.
- Nozaki T, Morii A, Yasuda K, Watanabe A, Komiya A, Fuse H. Hand-assisted laparoscopic partial nephrectomy by using an "open" device of microwave tissue coagulator. *J Laparoendosc Adv Surg Tech A*. 2010;20:461-4.
- Nozaki T, Watanabe A, Fuse H. Laparoendoscopic single-site surgery for partial nephrectomy without ischemia using a microwave tissue coagulator. *Surg Innov*. 2013;20:439-43.
- Harabayashi T, Shinohara N, Kakizaki H, Ameda K, Nonomura K, Koyanagi T. Ureteral stricture developing after partial nephrectomy with a microwave tissue coagulator: case report. *J Endourol*. 2003;17:919-21.
- Tanaka M, Kai N, Naito S. Retroperitoneal laparoscopic wedge resection for small renal tumor using microwave tissue coagulator. *J Endourol*. 2002;14:569-72.
- DeVoe WB, Kercher KW, Hope WW, Lincourt AE, Norton HJ, Teiglend CM. Hand-assisted laparoscopic partial nephrectomy after 60 cases: comparison with open partial nephrectomy. *Surg Endosc*. 2009;23:1075-80.
- Bylund JR, Clark CJ, Crispin PL, Lagrange CA, Strup SE. Hand-assisted laparoscopic partial nephrectomy without formal collecting system closure: perioperative outcomes in 104 consecutive patients. *J Endourol*. 2011;25:1853-7.
- Pareek G, Hedican SP, Gee JR, Bruskevitz RC, Nakada SY. Meta-analysis of the complications of laparoscopic renal surgery: comparison of procedures and techniques. *J Urol*. 2006;175:1208-13.
- Matin SF, Abreu S, Ramani A, et al. Evaluation of age and comorbidity as risk factors after laparoscopic urological surgery. *J Urol*. 2003;170:1115-20.
- Montgomery JS, Johnston WK 3rd, Wolf JS Jr. Wound complications after hand assisted laparoscopic surgery. *J Urol*. 2005;174:2226-30.
- Kaouk JH, Goel RK. Single-port laparoscopic and robotic partial nephrectomy. *Eur Urol*. 2009;55:1163-9.
- Cindolo L, Berardinelli F, Gidaro S, Schips L. Laparoendoscopic single-site partial nephrectomy without ischemia. *J Endourol*. 2010;24:1997-2002.
- Han WK, Kim DS, Jeon HG, et al. Robot-assisted laparoendoscopic single-site surgery: partial nephrectomy for renal malignancy. *Urology*. 2011;77:612-6.
- Nguyen MM, Gill IS, Ellison LM. The evolving presentation of renal carcinoma in the United States: trends from the surveillance, epidemiology, and end results program. *J Urol*. 2006;176:2397-400.
- Russo P. Should elective partial nephrectomy be performed for renal cell carcinoma >4 cm in size? *Nat Clin Pract Urol*. 2008;5:482-3.