

Aggressive Vaginal Angiomyxoma Mimicking a Bladder Mass

Bulent Erol,¹ Eyyup Sabri Pelit,¹ Sibel Bektaş,² Aliriza Şimşek³

¹ Department of Urology,
Istanbul Medeniyet University,
Faculty of Medicine, Istanbul,
Turkey.

² Department of Pathology,
Bulent Ecevit University, Faculty
of Medicine, Kozlu, Zonguldak,
Turkey.

³ Department of Urology,
Bulent Ecevit University, Faculty
of Medicine, Kozlu, Zonguldak,
Turkey.

Corresponding Author:

Eyyup Sabri Pelit, MD
Dr. Erkin Cad. Istanbul Medeniyet Üni-
versitesi, Göztepe Eğitim ve Araştırma
Hastanesi, Kadıköy, Istanbul, Turkey.

Tel: +90 506 388 3186
E-mail: dreyyupsabri@hotmail.com

Received May 2013
Accepted January 2014

Keywords: myxoma; vaginal neoplasms; diseases; diagnosis; diagnostic error; urinary bladder neoplasms; differential.

INTRODUCTION

Aggressive angiomyxoma is a rare, slow-growing myxoid neoplasm that occurs almost exclusively in the genital, perineal and pelvic regions of adult women. Because of its rarity and pelvic occurrence, it is often initially misdiagnosed as a gynecological malignancy or mixed with other malignancies.

CASE REPORT

A 48-year-old female patient presented with a history of abdominal swelling and hypertension. She had also difficulty in urination and defecation. On examination, a palpable large abdominal mass extending to the umbilicus was observed. Ultrasonography revealed intravesical mass and right grade IV and left grade II hydronephrosis. The computed tomography (CT) scan showed a large pelvic mass and bilateral hydronephrosis. (Figure 1). The proximal vaginal wall involvement could not be ruled out on CT scan. In CT scan images, a huge intravesical mass was seen but it did not have the classical appearance of bladder tumor. Under general anesthesia, a cystoscopy was performed initially to confirm intravesical mass. Cystoscopic examination was very difficult due to the huge size of the mass elevating the base of

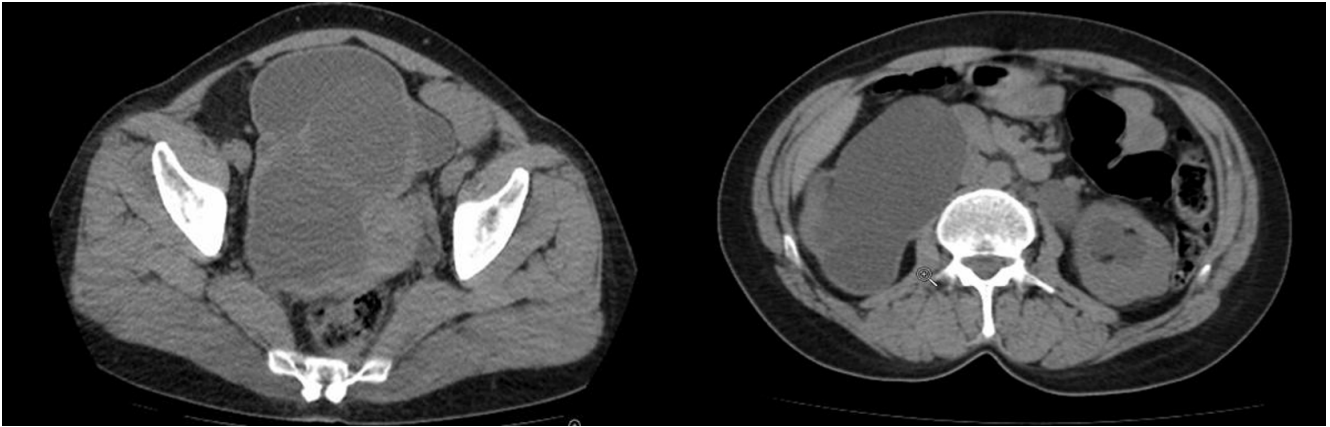


Figure 1. Large pelvic mass and bilateral hydronephrosis.

the bladder and there was no papillary bladder tumor. Double J ureteral stent was inserted to the left side. Right ureteral orifice was not seen due to compression of huge mass. Subsequently open exploration was planned. During the exploration, mass was thought to stem from posterior wall of bladder. The anterior bladder wall was incised, transversely. The mass was located between the posterior wall of the vagina and base of the bladder and originated from the posterior vaginal wall. Transvesical enucleation of mass was made and complete extirpation could be performed after incision of posterior wall of the bladder. Right ureteral orifice was excised simultaneously due to invasion of the orifice. Right ureteroneocystostomy was performed using the Paquin technique (Figure 2). The postoperative period was uneventful. Bilateral hydronephrosis was resolved and according to control CT scan no mass has been recurred on

6-month and 2-year postoperatively (Figure 3).

DISCUSSION

Aggressive angiomyxoma, synonymously referred to as deep angiomyxoma by the World Health Organization (WHO), was first described in 1983 as “aggressive angiomyxoma of the female pelvis and perineum”.⁽¹⁾ This neoplasm usually involves the deep soft tissues of the vulvovaginal region, pelvis and perineum of women in the reproductive age.^(2,3) The reason of high prevalence in reproductive age group is thought to be estrogen-dependent nature of the tumor and estrogen and progesterone receptor positivity.^(4,5) Our patient is not in reproductive age group. Aggressive angiomyxoma is often a large lesion that fills much of the pelvis, displacing rather than directly invading the pelvic structures.⁽⁶⁾ It is a locally invasive neoplasm

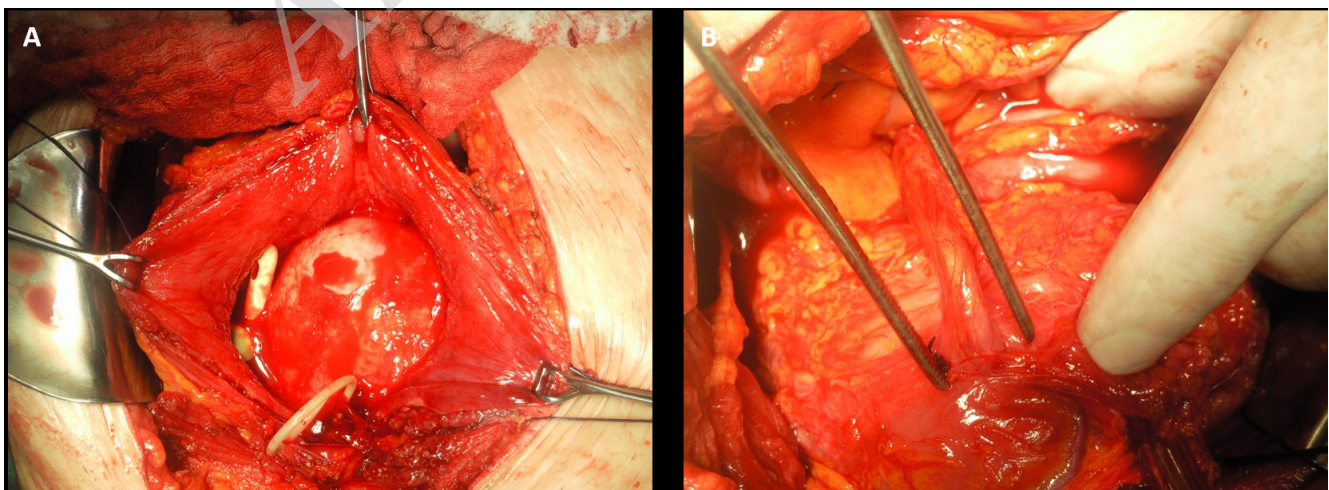


Figure 2. Mass elevating the base of bladder and intact mucosa (A) with right ureteroneocystostomy (B).

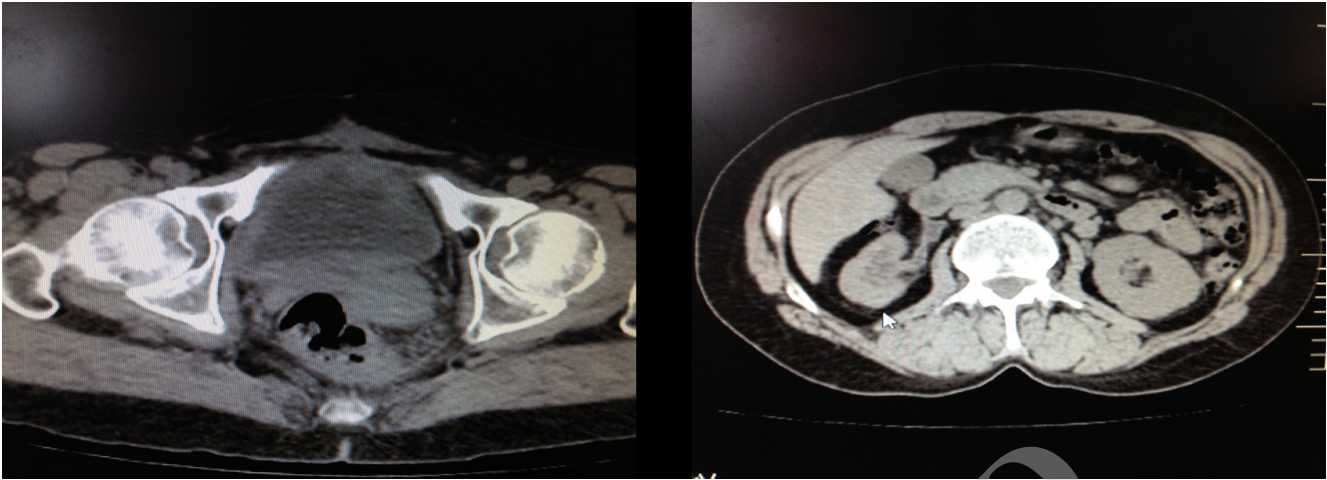


Figure 3. Postoperative computed tomography scan showing no mass and hydronephrosis.

with a distinct risk of local recurrence, especially in lesions that extend to the other pelvic organs.⁽⁷⁾ In this case, pelvic mass was invade to bladder and ureteral orifice. Thus our patient was presented with a difficulty in urination and defecation and bilateral hydronephrosis.

Local excision with tumor free margin is the standard treatment of the angiomyxoma. The excision of these tumors is difficult as they have the same consistency as that of normal connective tissue and therefore have a propensity for local recurrence (36-72%).⁽⁸⁾ Hormonal treatment with gonadotropin releasing hormone (LHRH) agonists, such as goserelin acetate, might be of value in the management of aggressive angiomyxoma, especially in recurrent or residual cases that are not amenable to surgical resection.⁽⁹⁾ In this case, excision of pedunculated lesion was complete and the postoperative period was uneventful. Thus there is no need for further treatment with LHRH agonist.

For this lesion long-term follow-up is required due to high risk recurrence and minimal risk of metastasis.⁽¹⁰⁾ In 1996, Fetsch and colleagues reported a series of 29 women with pelvic angiomyxoma. In their series, there was no metastasis but recurrence has been frequently observed. Eight patients developed recurrent tumor, from 10 months to 7 years after the initial resection and there were no tumor related deaths.⁽³⁾ In the literature 71% of recurrences have occurred within the first 3 years. There was no correlation between the size of the tumors and the chance of recurrence.⁽⁸⁾ In

our case, CT imaging is the preferred method for detecting recurrences. The first follow-up imaging was performed via ultrasonography 3 months after the operation and thereafter follow-up CT scan was performed on first and second year postoperative period. There was no recurrence and metastasis during the 2-year follow-up.

CONCLUSION

In conclusion, angiomyxoma is rare, benign and locally aggressive tumor which compresses the adjacent structure with mass affect. With the preoperative imaging methods, it is difficult to predict whether it is a bladder tumor or not. It can mimic a bladder mass in imaging modalities. Thus, it should be noted that this type of pelvic masses may be gynecological origin other than urological origin.

REFERENCES

1. Steeper TA, Rosai J. Aggressive angiomyxoma of the female pelvis and perineum. Report of nine cases of a distinctive type of gynecologic soft-tissue neoplasm. *Am J Surg Pathol.* 1983;7:463-75.
2. Bégin LR, Clement PB, Kirk ME, Jothy S, McCaughey WT, Ferenczy A. Aggressive angiomyxoma of pelvic soft parts: a clinicopathologic study of nine cases. *Hum Pathol.* 1985;16:621-8.
3. Fetsch JF, Laskin WB, Lefkowitz M, Kindblom LG, Meis-Kindblom JM. Aggressive angiomyxoma: a clinicopathologic study of 29 female patients. *Cancer.* 1996;78:79-90.
4. Ribaldone R, Piantanida P, Surico D, Boldorini R, Colombo N, Surico N. Aggressive angiomyxoma of the vulva. *Gynecol Oncol.* 2004;95:724-8.

5. McCluggage WG, Patterson A, Maxwell P. Aggressive angiomyxoma of pelvic parts exhibits oestrogen and progesterone receptor positivity. *J Clin Pathol.* 2000;53:603-5.
6. McCluggage WG. Recent developments in vulvovaginal pathology. *Histopathology.* 2009;54:156-73.
7. Magtibay PM, Salmon Z, Keeney GL, Podratz KC. Aggressive angiomyxoma of the female pelvis and perineum: a case series. *Int J Gynecol Cancer.* 2006;16:396-401.
8. Chan YM, Hon E, Ngai SW, Ng TY, Wong LC. Aggressive angiomyxoma in females: is radical resection the only option? *Acta Obstet Gynecol Scand.* 2000;79:216-20.
9. McCluggage WG, Jamieson T, Dobbs SP, Grey A. Aggressive angiomyxoma of the vulva: Dramatic response to gonadotropin-releasing hormone agonist therapy. *Gynecol Oncol.* 2006;100:623-5.
10. Mathieson A, Chandrakanth S, Yousef G, Wadden P. Aggressive angiomyxoma of the pelvis: a case report. *Can J Surg.* 2007;50:228-9.

Archive of SID