

# Evaluation of Safety and Efficacy of Open Mini-Access Ureterolithotomy in the Era of Minimally Invasive Surgery

Sholay Kangjam Meitei, Bijit Lodh, Somarendra Khumukcham, Sandeep Gupta, Kaku Akoijam Singh, Rajendra Singh Sinam

Department of Urology,  
Regional Institute of Medical  
Sciences (RIMS), Imphal,  
Manipur, India.

Corresponding Author:

Bijit Lodh, MD  
Department of Urology,  
Regional Institute of Medical  
Sciences, Lamphelpat, Imphal,  
Manipur, India, PIN-795004.

Tel: +91 89 7450 4215  
E-mail: drblodh@yahoo.co.in

Received May 2013  
Accepted April 2014

**Purpose:** To evaluate the effectiveness and safety evaluation of mini-access ureterolithotomy in the management of ureteric calculus.

**Materials and Methods:** This was a cross-sectional study conducted at Department of Urology, Regional Institute of Medical Sciences, Imphal. A total number of one hundred and forty three patients with radiologically confirmed ureteral calculus (size > 1 cm) were enrolled in this study.

**Results:** The mean age of male and female patients was  $44.97 \pm 11.24$  and  $43.89 \pm 14.49$  years, respectively. In the majority of cases stone was in the upper ureter irrespective of the side. The stone size ranged from 10 to 30 mm in diameter. The most common indication for open mini-access ureterolithotomy in the present study was impacted large stone (45%). The mean operation duration was  $25.39 \pm 5.11$  min, with an incision length of  $4.78 \pm 0.25$  mm; the estimated blood loss was  $50.55 \pm 8$  mL and none of the patient's required post-operative blood transfusion. The overall complication rate was 5.6%.

**Conclusion:** Open mini-access ureterolithotomy is a safe procedure with fewer complications and cosmetically acceptable results. Although in this minimally invasive era, the specific indications for open stone surgery are a few, but when the situation mandates, an open mini-access ureterolithotomy might be considered the best option.

**Keywords:** ureteral calculi; surgery; treatment outcome; pain; postoperative; length of stay.

## INTRODUCTION

For centuries, "cutting for stone" was synonymous with urology, and just over a decade ago, it still made up at least one-fourth of the surgical activity in the field. Open stone surgery (OSS) was the standard of care for treating urinary stones until the early 1980s. Presently, in the developed countries, it has been replaced by minimally invasive techniques like extracorporeal shock wave lithotripsy (SWL), ureterorenoscopic lithotripsy and percutaneous nephrolithotomy.<sup>(1)</sup> However, OSS still plays a significant role for management of stone disease refractory to these armamentarium of modern era.<sup>(2,3)</sup> It is likely to achieve highest stone clearance at single sitting and may be the only option for treating urinary stones in many parts of the developing world. Mini-access ureterolithotomy (MAU), is a refined percutaneous open surgical procedure that is associated with better Cosmesis and a more cost-effective outcomes. Here, our study was aimed to determine the efficacy and safety of MAU in the management of ureteric calculus in our institution.

## MATERIALS AND METHODS

### *Study Design*

This was a cross sectional study conducted at our urology department from September 2010 to February 2012. Ethical approval was obtained from the Research and Ethics Committee of the Institute.

### *Inclusion and Exclusion Criteria*

A total number of 143 patients admitted in our urology ward, with radiologically confirmed ureteral calculus (size > 1 cm) and fit to undergo surgery were included in this study. Informed written consent was taken from the participants. Exclusion criteria were: patients with stone size ≤ 1cm, multiple ureteral or associated renal calculi, patients with renal insufficiency and pregnancy and body mass index (BMI) more than 25 kg/m<sup>2</sup>.

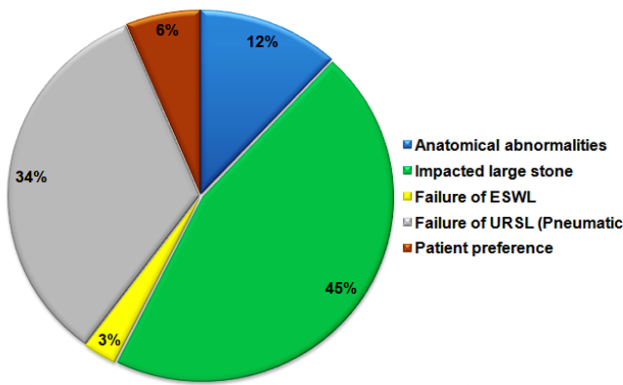
### *Data Collection and Surgical Procedure*

An eligibility criterion was based on history and physical examination, ultrasound, kidney-ureter-bladder (KUB) X-ray and intravenous urography (IVU). Details of various parameters including operative indication, age and sex of patients, size and location of stone were recorded. The operation is performed with the patient under general/spinal

anesthesia after proper positioning and determining the surgical approach based on the stone location on preoperative plain films. A subcostal flank incision, modified Gibson incision and a midline suprapubic incision is made in approaching the upper, middle and lower ureteric stones, respectively. A 5 cm skin incision (Figure 1) is made with a muscle cutting approach for the upper ureter and muscle-splitting approach for the mid and lower ureter. During an approach for the upper ureteric stone, after mobilizing the peritoneum anteriorly the ureter is usually found either on the psoas muscle or embedded to the peritoneum. The stone is located by palpating the ureter between thumb and index finger, and then it is clamped with two Allis tissue forceps proximal and distal to the stone to prevent migration (Figure 2). Keeping stay sutures on either side of the proposed ureterotomy incision, it is opened longitudinally onto the stone and then the stone is retrieved (Figure 3). Proximal and distal patency of the ureter is checked by inserting feeding tube no. 6 through the ureterotomy wound. Following insertion of 6 French (F) double J stent, ureterotomy is closed with 3-0 chromic catgut (Figure 4). After placement of 22F abdominal drain tube into the retroperitoneal space, muscle and aponeurotic layers are closed with No.1 polydioxanone or polyglactin suture and skin with 2-0 silk suture or skin stapler (Figure 5 and 6). Patients are discharged on the 3rd-5th post-operative day after removing the drain tube. The skin sutures or staples are removed on the 7th post-operative day in the ward review. To see the stone clearance patients are reviewed with KUB X-ray after 3 weeks and double J stent are removed cystoscopically. All data were analyzed using the statistical package for the social science (SPSS Inc, Chicago, Illinois, USA) version 16.0.

## RESULTS

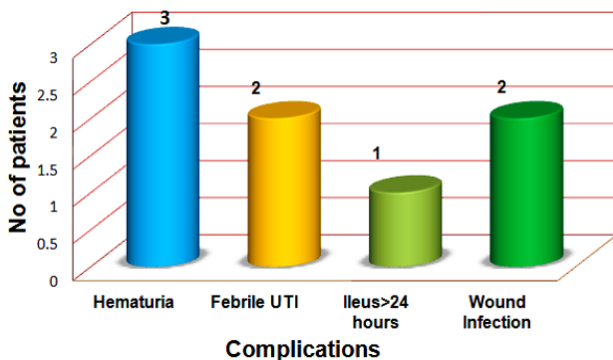
Pre-operative characteristics of the patients are shown in Table 1. The mean age of male and female patients was 44.97 ± 11.24 and 43.89 ± 14.49 years, respectively. The number of female patients (79) was more in comparison to male. Mean BMI of the patients was 20.79 ± 2.73 kg/m<sup>2</sup> (range 16-25 kg/m<sup>2</sup>). In the present study the stone was mostly located in the upper ureter (72.72%) followed by middle and lower ureter in 15.39% and 11.89%, respectively. The stone size ranged from > 10 to < 30 mm, of which size 15 to < 20



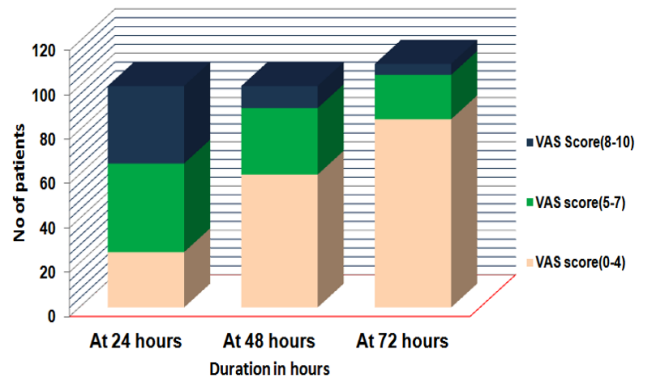
**Chart 1.** The indications of open mini-access ureterolithotomy.  
**Keys:** ESWL, extracorporeal shockwave lithotripsy; URSL, ureterorenoscopic lithotripsy.

mm (36.36%) was the most common occurrence followed by 20 to < 25 mm (27.27%). The mean size of the stone in the present study was  $18.35 \pm 4.54$  (10.50-28.00).

Chart 1 represents the indications of open mini-access ureterolithotomy. The most common indication for open mini-access ureterolithotomy in the present study was impacted large stone (45%) and the second most common indication was failure of ureterorenoscopic lithotripsy (URSL). Only 12% of patients had anatomical abnormalities which favored open mini-access ureterolithotomy as the preferred modality of treatment. Table 2 shows operative features of open mini-access ureterolithotomy. The mean operative duration was  $25.39 \pm 5.11$  min, with an incision length of  $4.78 \pm 0.25$  mm; the estimated blood loss was  $50.55 \pm 8$  mL with none of the patient's required post-operative blood transfu-



**Chart 3.** The post-operative complications.



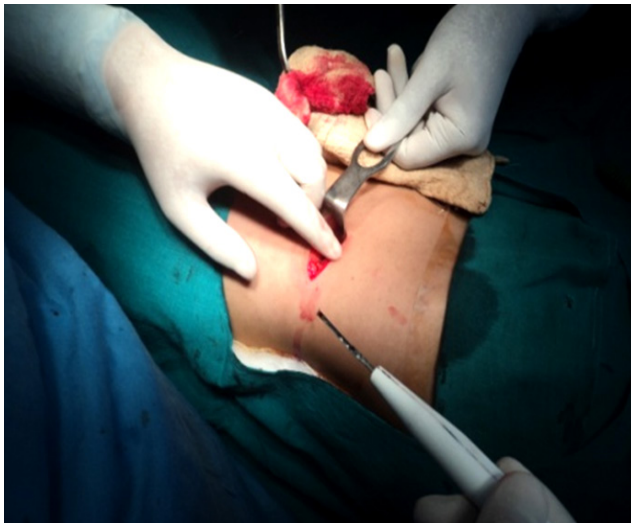
**Chart 2.** Evaluation of pain score in the post-operative period using visual analogue scale.  
**Keys:** VAS, visual analogue scale.

sion.

The pain score in the post-operative period of 24 hours 48 hours and 72 hours are shown in Chart 3 using the visual analogue scale (VAS). Although severe post-operative pain (VAS score 8-10) has been noted in 35% of cases at 24 hours, it was reduced to 10% and 5% of patients at 48 hours and 72 hours respectively. The post-operative complications were few and minor in all cases as shown in Chart 3. The overall complication rate was 5.6%. Hematuria and fever resolved with conservative management. The mild ileus resolved with nil oral for another day and laxative suppository. Wound infections were mild with minimal subcutaneous collections which resolved with drainage and dressing. The success rate and complications of mini-access ureterolithotomy among the various indicated subgroups are shown in Table 3. The success rate was 100% in most all the cases except in patients with prior failed URSL where a success rate of 98% was noticed. Complication rate was more in patients with impacted large calculus and patients with prior URSL, and it was 7.93% and 6.12% respectively. However, the overall complication rate in the present study was 5.60%.

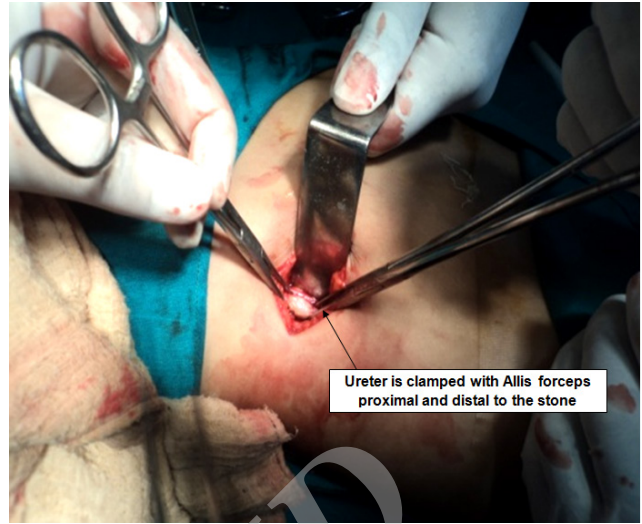## DISCUSSION

The last three decades have brought revolutionary changes in the management of urolithiasis. Due to recent advances in Endourology, there is hardly any role of open stone surgery. According to European Association of Urology (EAU) guidelines, open ureterolithotomy might be con-



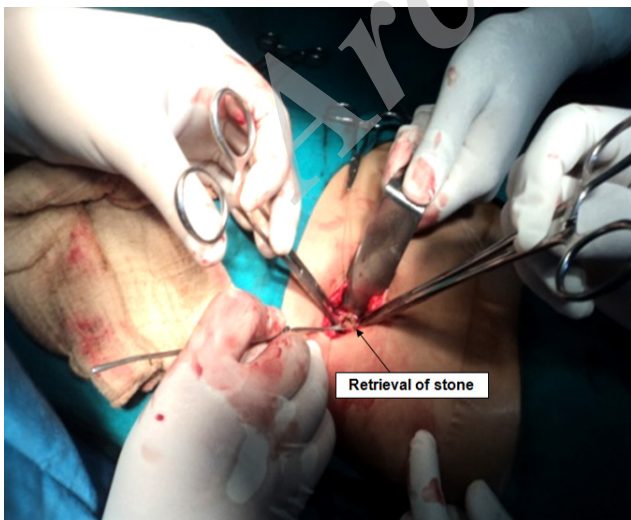**Figure 1.** Showing skin incision for minimally access ureterolithotomy.

sidered for treating an impacted large calculus, multiple ureteral stones or in the event of any coexistence disease requiring surgery.<sup>(4)</sup> Despite of a high stone-free rate of 97%, open ureterolithotomy has not been recommended as a first-line of treatment secondary to prolonged hospitalization and greater procedure related morbidity.<sup>(5)</sup> However, MAU is a modified and technically more precise in comparison to conventional ureterolithotomy. It requires a small skin incision ( $\leq 5$  cm) and the muscles are cut minimal for

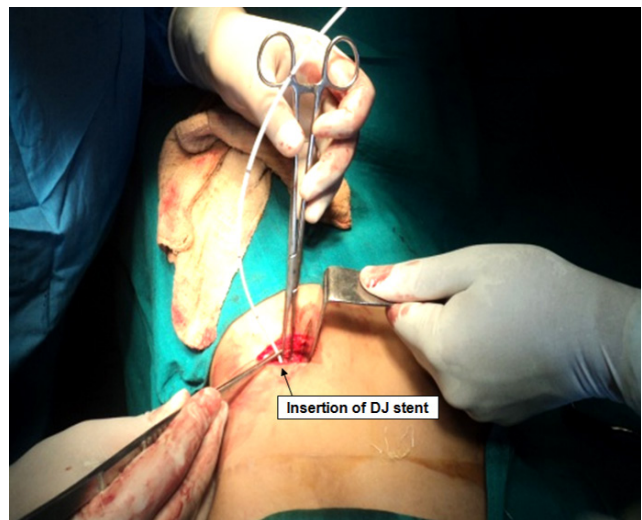


**Figure 2.** Showing clamping of the proximal and distal stone bearing segment of the ureter with Allis forceps.

upper ureterolithotomy or split along the fibers in case of mid and lower ureterolithotomy. In this present study, the most common indications for MAU were impacted large stone and failure of URSL which is in accordance with the findings of Ather and colleagues.<sup>(6)</sup> SWL is a non-invasive method can be performed on an outpatient basis without regional or general anesthesia, but the stone free rate depends on the study, the type of the lithotripter used, the size of the stone and location with respect to the ureter. For proximal

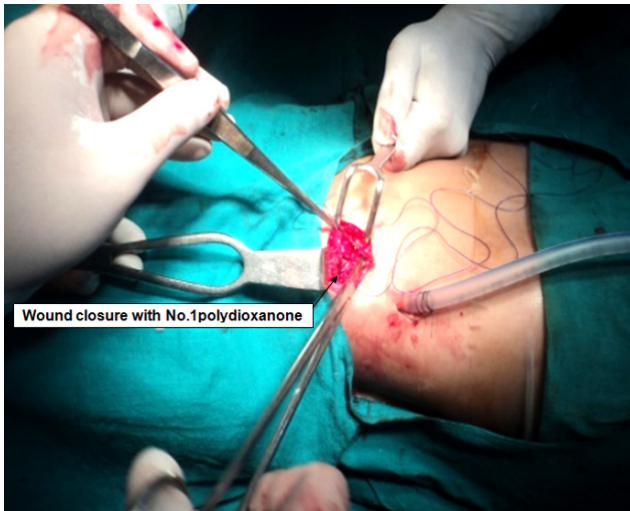


**Figure 3.** Showing longitudinal opening of the ureter onto the stone.



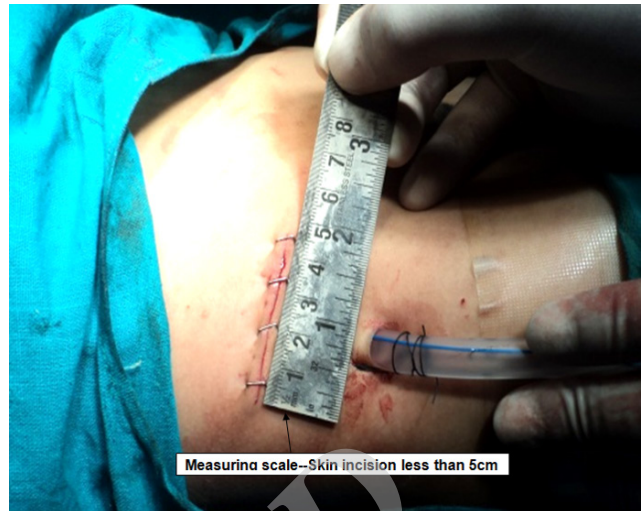**Figure 4.** Showing placement of double J stent with closure of ureterotomy incision.





**Figure 5.** Showing closure of muscle and aponeurotic layer with 1-0 polydioxanone.

ureteric stone, SWL is associated with a mean stone free rate of 77.4% with a re-treatment rate of 10%, whereas the figure is 80.3% and 8.2% for mid ureteric and 77.9% and 9.4% for distal ureteric stones.<sup>(1)</sup> The effectiveness of SWL is increasingly limited because certain stones are resistant to fragment, leading to high re-treatment rate with an overall increase in cost and lost from work. URSL has become a formidable method for treating ureteric stones. The literature review revealed a stone free rate of 90-100% for the distal and up to 74% for proximal ureteric calculus using a semi rigid or flexible ureteroscopy.<sup>(7)</sup> However, certain conditions, including ureteric stricture, inflamed and or obliterated ureterovesical junction, extensive urothelial carcinoma in situ and intravesical prostatic protrusion may limit the ureterorenoscopic access into the ureter.<sup>(8)</sup> Moreover, use of flexible ureteroscopy is limited by the high purchase and maintenance cost to the surgeon and associated operating cost to the patient. Wickham in 1979 first described the laparoscopic ureterolithotomy. Gaur and colleagues have described the largest series of retroperitoneal lap ureterolithotomy more than 100 cases over 10 years using a balloon dissector.<sup>(9)</sup> Although these results are admirable, the present study showed that MAU is a quicker and cost-effective technique requiring only ordinary equipment. Major disadvantages of laparoscopy ureterolithotomy included prolonged operating time, expensive instruments and more



**Figure 6.** Showing stapled skin incision measuring < 5 cm.

operative skilled. Hossein and colleagues<sup>(10)</sup> observed a mean operation time of 82.15 min (73-180 min) for the laparoscopic management of the large upper ureteric calculus. The mean operative time of MAU in this study was  $25.39 \pm 5.11$  min that is in accordance with findings of Sharma and colleagues.<sup>(11)</sup> Laparoscopic ureterolithotomy is usually favorable over conventional open ureterolithotomy based on the data from small non-randomized studies.<sup>(12)</sup> However, the above finding has little bearing on the mini-access ureterolithotomy, which ranks superior with respect to outcome and morbidity compared to conventional approaches. The cosmetic results are definitely outweighed with a  $\leq 5$  cm incision and a small puncture site for the drain. In our study BMI of patients was less than  $< 25$  kg/m<sup>2</sup>. Therefore, certainly we will recommend not to perform open mini access ureterolithotomy in patients with BMI  $> 25$  kg/m<sup>2</sup>. Percutaneous open mini-access ureteric approach have also been described earlier, but those techniques require specialized instruments, endourological intervention, and mostly preferred for mid-ureteric calculus.<sup>(13,14,15)</sup> is also recommended.<sup>(12,13)</sup> The present technique is comparatively simple and easy to acquire without extra expenses. The majority of the patients had low pain scores and required a few days of postoperative analgesia. This is largely because of the minimal tissue dissection. In the present study, all patients were discharged stone-free and were free of complications apart

from those eight patients with minor complications which responded to conservative management that is comparable with the observation of Sharma and colleagues.<sup>(11)</sup>

## CONCLUSION

Open mini-access ureterolithotomy is a safe procedure, which causes minor post-operative complications with early return to work. It is highly effective in the management of ureteric calculus as the calculus can be removed successfully in a single sitting with cosmetically acceptable scar. In this minimally invasive era, the specific indications for open stone surgery are a few. But, when the situation mandates, an open mini-access ureterolithotomy might be considered the best option. In future, randomized comparative study can be carried out between laparoscopy and MAU in the management of large ureteric calculus.

## CONFLICT OF INTEREST

None declared.

## REFERENCES

1. Tiselius HG, Ackermann D, Alken P, Buck C, Conort P, Gallucci M. Working Party on Lithiasis. EAU Guidelines on Urolithiasis. *Eur Urol.* 2001;40:362-71.
2. Matlaga BR, Assimos DG. Changing indications of open stone surgery. *Urol.* 2002;59:490-3.
3. Sy FY, Wong MY, Foo KT. Current indications for open stone surgery in Singapore. *Ann Acad Med Singapore.* 1999;28:241-4.
4. Preminger GM, Tiselius HG, Assimos DG, et al. 2007 guideline for the management of ureteral calculi. *J Urol.* 2007;178:2418-34.
5. Segura JW, Preminger GM, Assimos DG, et al. Ureteral Stones Clinical Guidelines Panel summary report on the management of ureteral calculi. The American Urological Association. *J Urol.* 1997;158:1915-21.
6. Ather MH, Paryani J, Memon A, Sulaiman MN. A 10-year experience of managing ureteric calculi: changing trends towards endourological intervention – is there a role for open surgery? *BJU Int.* 2001;88:173-7.
7. Osti AH, Hofmockel G, Frohmüller H. Ureteroscopic treatment of ureteral stones: only an auxiliary measure of extracorporeal shock wave lithotripsy or a primary therapeutic option? *Urol Int.* 1997;59:177-81.
8. Tligui M, El Khadime MR, Tchala K, et al. Emergency extracorporeal shock wave lithotripsy (SWL) for obstructing ureteral stones. *Eur Urol.* 2003;43:552-5.
9. Gaur DD, Trivedi S, Prabhudesai MR, Madhusudhana HR, Gopichand M. Laparoscopic ureterolithotomy: technical considerations and long-term follow-up. *BJU Int.* 2002;89:339-43.
10. Hossein K, Mohammad MM, Behzad L, Asghar A, Babak J. Ultrasonography-guided PNL in comparison with laparoscopic ureterolithotomy in the management of large proximal ureteral stone. *Braz J Urol.* 2013;39:22-8.
11. Sharma DM, Maharaj D, Naraynsingh V. Open mini-access ureterolithotomy: the treatment of choice for the refractory ureteric stone? *BJU Int.* 2003;92:614-6.
12. Goel A, Hemal AK. Upper and mid-ureteric stones: a prospective unrandomized comparison of retroperitoneoscopic and open ureterolithotomy. *BJU Int.* 2001;88:679-82.
13. Toth CS, Varga A, Flasko T, Tallai B, Salah MA, Kocsis I. Percutaneous ureterolithotomy: direct method for removal of impacted ureteral stones. *J Endourol.* 2001;15:285-90.
14. Frang D, Jako GJ, Repassy DL. Minimal access ureterolithotomy. *Int Urol Nephrol.* 1996;28:305-8.
15. Repassy D, Frang D, Jako GJ. Minimal and direct access ureterolithotomy. *Acta Chir Hung.* 1995;35:361-8.