

Uretero-Caval Fistula after Radical Cystectomy with Bricker Ileal Conduit: A Case Report

Cristian Vincenzo Pultrone,¹ Riccardo Schiavina,¹ Eugenio Brunocilla,¹ Caterina Gaudiano,² Matteo Renzulli,² Valerio Vagnoni,¹ Fiorenza Busato,² Marco Borghesi,¹ Giuseppe Martorana¹

¹ Department of Urology,
Azienda Ospedaliero-Universitaria, Policlinico S. Orsola-Malpighi, Bologna, Italy.

² Department of Radiology,
Azienda Ospedaliero-Universitaria, Policlinico S. Orsola-Malpighi, Bologna, Italy.

Corresponding Author:

Marco Borghesi, MD.
Palagi 9 street, 40138 Bologna, Italy.

Tel: +39 051 636 2733
Fax: +39 051 636 2743
E-mail: mark.borghesi@gmail.com

Received July 2013
Accepted January 2014

Keywords: urinary fistula; vena cava; inferior; ureter; urinary diversion; cystectomy; methods; postoperative complications.

INTRODUCTION

Radical cystectomy represents the gold standard treatment for muscle-invasive bladder cancer and ileal conduit (IC), first described by Bricker in 1950, continues to be one of the most common forms of urinary diversion. Nevertheless, the rate of early (infections, fistulas and bleeding) and late (parastomal hernia, ureteral/ileal stenosis, urolithiasis and deterioration of kidney function) reaches up to 66%.⁽¹⁾ In the literature, the uretero-arterial fistulas, as well as the aorto/iliac-ureteral fistula, are reported as complications of pelvic surgery or radiotherapy,⁽²⁾ and ureteral or endovascular stenting.^(3,4) Ishibashi and colleagues⁽⁵⁾ described a case of aorto-ileal-conduit fistula but, to our knowledge, this is the first case of fistula between ureter and inferior vena cava (IVC).

CASE REPORT

We report the case of a 68-year-old woman who has underwent cystectomy and pelvic lymphadenectomy with Bricker IC for a muscle-invasive-high grade urothelial bladder cancer. Computed tomography-urography (CTU) performed for the onset of fever forty days after surgery, revealed a thrombus in the lumen of the IVC at the level of right ureteral anastomosis (Figure 1A) with a urinary fistula between the ureter and IVC (Figure 1B; arrow indicates the

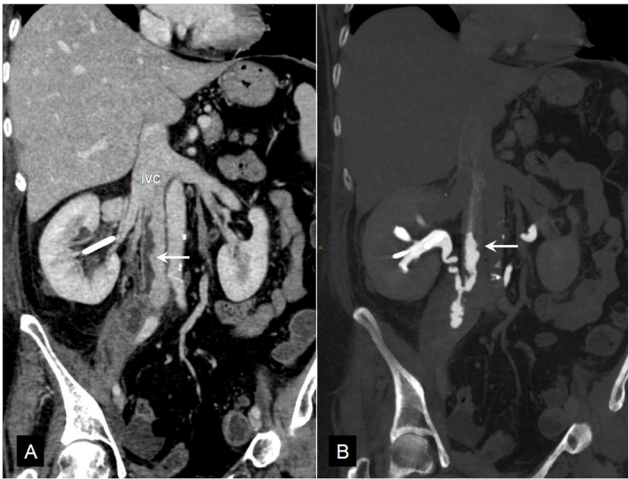

Figure 1. Inferior vena cava with thrombus in the lumen at the level of right ureteral anastomosis, arrow highlights the urinary fistula between the ureter and inferior vena cava.

passage of iodinated urine in the lumen of the IVC through the fistula). The examination excluded abdominal fluid collections; pulmonary microembolism was also present. Due to the high surgical risk, we decided to perform a conservative treatment to allow the complete exclusion of the urinary system and the treatment of IVC thrombosis and pulmonary

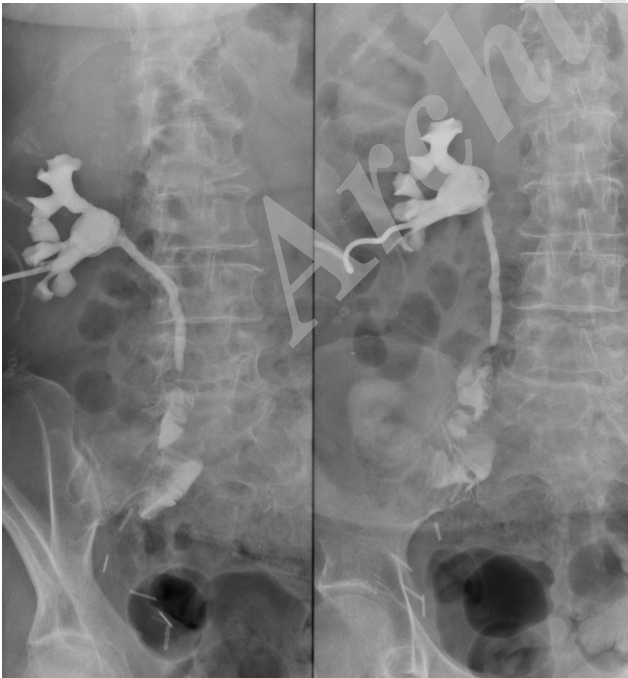


Figure 3. Antegrade pyelography without ureteral stent, complete resolution of the fistula.

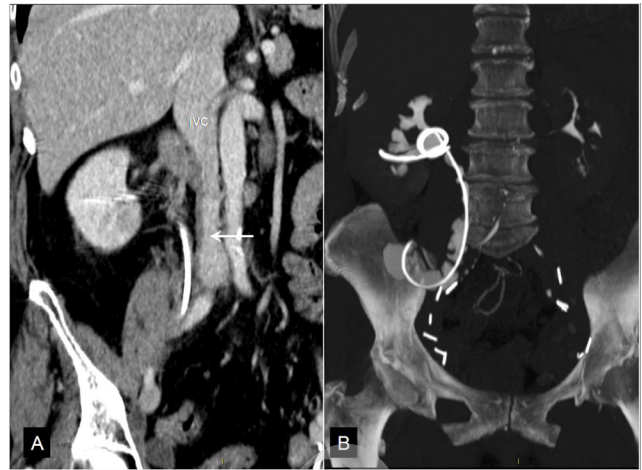

Figure 2. Computed tomography-urography performed prior to the ureteral stent removal, note the complete healing of the inferior vena cava wall.

microembolism. Therefore, nephrostomy and antegrade ureteral stent were positioned in addition to the anticoagulant/antimicrobial therapy. After one month, the CTU performed prior to the ureteral stent removal demonstrated the complete healing of the IVC wall (Figure 2A, arrow) and the absence of the passage of iodinated urine in the lumen of the vein (Figure 2B). The antegrade pyelography, carried out without ureteral stent, confirmed the complete resolution of the fistula with regular flow of the iodinated urine in the IC (Figure 3).

DISCUSSION

Notably, our case stands out because the patient did not show the typical sign of a urinary-vascular fistula, i.e. hematuria, but only nonspecific clinical sign such as fever; this presentation made the clinical diagnosis more challenging. It has been shown that pelvic lymph node dissection (PLND) has a staging and, maybe, therapeutic role in the treatment of muscle-invasive bladder cancer,^(6,7) in this case, we performed an extended PLND up to the IVC, which was probably damaged in its wall during the dissection. Endoluminal thrombosis, as a result of an ulcer in the wall of the vein, prevented the bleeding in the ureter (avoiding the hematuria) and limited the spreading of the urine through the fistula.

CONFLICT OF INTEREST

None declared.

REFERENCES

1. Madersbacher S, Schmidt J, Eberle JM, et al. Long-term outcome of ileal conduit diversion. *J Urol*. 2003;169:985-90.
2. Santarpia L, Creta M, Bracale UM, et al. Ureteroiliac artery fistula in a young woman with short bowel syndrome for radiation enteritis. *Case Rep Med*. 2010;2010:287034.
3. Dangle PP, Bahnon R, Patel A. Ureteral stent-related aortoureteric fistula: case report and literature review. *Can Urol Assoc J*. 2009;3:84-6.
4. Aarvold A, Wales L, Papadakos N, Munneke G, Loftus I, Thompson M. Arterio-ureteric fistula following iliac angioplasty. *Cardiovasc Intervent Radiol*. 2008;31:821-3.
5. Ishibashi H, Ohta T, Sugimoto I, et al. Successful treatment of an aorto-ileal-conduit fistula with an endovascular stent graft: report of a case. *Surg Today*. 2007;37:305-7.
6. Palmieri F, Brunocilla E, Bertaccini A, et al. Prognostic value of lymphovascular invasion in bladder cancer in patients treated with radical cystectomy. *Anticancer Res*. 2010;30:2973-6.
7. Brunocilla E, Perneti R, Martorana G. The role of pelvic lymph node dissection during radical cystectomy for bladder cancer. *Anticancer Res*. 2011;31:271-5.

Archive of SID