

# Long-Term Follow-Up on the Effects of Sigmoid-Rectal Pouch for Urinary Diversion

Bin Sun, Jing-Min Yan, Jian-Ye Li, He-Qing Guo, Quan Hong, Zhi-Yong Yao, Gao-Biao Zhou, Guang-Xin Pan, Xian-Chu Li

Department of Urology, the  
General Air Force Hospital  
of People's Liberation Army,  
Beijing 100142, China.

*Corresponding Author:*

Heqing Guo, MD  
Department of Urology, the General  
Air Force Hospital of People's Liberation  
Army,  
No. 30 Fucheng Road Haidian District,  
Beijing 100142, China.

Tel: +86 1561 116 1132  
Fax: +86 1068 482 380  
E-mail: heqingguocn@126.com

Received October 2013  
Accepted April 2014

**Purpose:** The aim of this study was to investigate the long-term clinical effects of sigmoid-rectal pouch for urinary diversion.

**Materials and Methods:** A total of 45 patients, including 40 males and 5 females, underwent sigmoid-rectal pouch procedure. The patients aged from 38 to 70 years with a mean age of 59 years. The postoperative follow-up ranged from 6 months to 19 years with an average of 6 years. Postoperative continence and voiding were analyzed, urinary reservoir pressure was measured and the complications of upper urinary tract were determined. The index of quality of life (QoL) in the International Prostate Symptom Score (IPSS) was used to evaluate the degree of satisfaction to urinate.

**Results:** Forty patients had slight incontinence in the early postoperative stage and could control urination well 30 days postoperatively. The volume of pouch was 270-600 mL with an average of 375 mL. The basic pressure during filling period was 6-20 cmH<sub>2</sub>O with an average 15 cmH<sub>2</sub>O, the maximum filling pressure was 15-30 cmH<sub>2</sub>O with an average 26 cmH<sub>2</sub>O. The compliance of sigmoid-rectal pouch was fine with an average of 30 (range 18-40) mL/cmH<sub>2</sub>O. There were no severe complications such as hyperchloremic acidosis or retrograde pyelonephritis. Six patients had slight hydronephrosis. The index of QoL were 0-2 in 20 patients, 3 in five patients and 4 in two patients.

**Conclusion:** The sigmoid-rectal pouch operation was simple and acceptable by surgeons and patients. It may be an ideal urinary diversion for patients with muscle-invasive bladder cancer, especially for patients on whom urethrectomy should be done.

**Keywords:** reconstructive surgical procedures; urinary diversion; methods; urinary reservoirs; surgery; continent; carcinoma; transitional cell; urinary bladder neoplasms.

## INTRODUCTION

The incidence of bladder cancer ranks 11<sup>th</sup> among all malignant tumors in the world and ranks 7<sup>th</sup> in men, out of place in the top 10 in women.<sup>(1)</sup> In Urinary tract malignant tumors, the incidence of bladder cancer ranks second, while transitional cell carcinoma accounts for 90%.<sup>(2)</sup> Although most bladder cancers are non-muscle invasive, about 30% still manifest or develop into invasive cancers, requiring radical cystectomy, pelvic lymphadenectomy and urinary diversion (UD), which can improve the survival rates and reduce the chance of local recurrence and distant metastasis in patients. There are many methods of UD and mainly be categorized into noncontinent diversion, continent diversion. Among those methods, orthotopic neobladder and Bricker operation are most widely performed on the patients. The former could make patients to urinate near to physiological. Moreover, the recurrence of cancer in residual urethra is also a concern. Bricker operation is simple and more endurable, but patients have to carry urine collection bag due to abdominal colostomy. Continence preserved with anus is another choice. In early operations, ureters were connected to sigmoid flexure or rectum directly and this kind of operations tends to lead to retrograde infection, hyperchloremic acidosis and hydronephrosis. In 1993, Fisch reported urinary diversion in which sigmoid colon and rectum were folded to form a pouch and ureterosigmoidostomy was performed to control defecation and urination by anus (Mainz pouch II). Relative to early operations, this improved operation reduces the complications and can get reasonable compliance of urinary reservoir. The continence and life quality of patients greatly improved. For summarizing the long-term clinical effects of sigmoid-rectal pouch for urinary diversion, we analyzed the clinical data of 45 patients who were performed sigmoid-rectal pouch for UD.

## MATERIALS AND METHODS

### *Clinical Data*

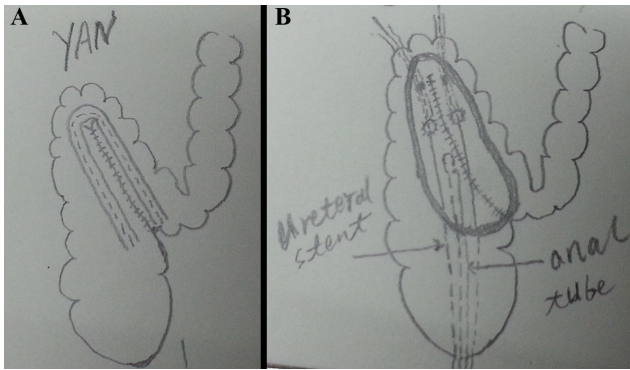
Forty-five patients were included in our study treated by radical cystectomy for invasive bladder cancer with the urinary diversion of sigmoid-rectal pouch between June 1993 to June 2012 at the Air Force General Hospital. Data of the patients are summarized in Table 1. All the cases were muscle invasive bladder cancer, which were mainly multiple bladder

tumors or/and invaded bladder trigon and posterior urethra. In preoperative preparation, the sense of perianal skin was checked; digital rectal examination was conducted; barium enema was carried out to diagnose problems with rectum and sigmoid colon; at the same time, 500 mL of saline was utilized for retention enema for 1 hour to confirm that anal sphincter functioned well. This study was conducted in accordance with the declaration of Helsinki and with approval from the Ethics Committee of the General Hospital of Air Force. Written informed consent was obtained from all participants.

**Indications and Contraindications of Sigmoid-Rectal Pouch**  
The indications are bladder malignancy, bladder exstrophy/epispadias, trauma and sinus urogenitalis. The contraindications are colon cancer and polyps, and deteriorated anal sphincter function. In this study, all the patients had bladder cancers.

### *Surgical Procedure*

After resection of bladder, prostate and urinary tract, anal canal was cannulated into anus, through which 200 mL diluted iodophor was installed into rectum and sustained for 10 min. The boundary spot between sigmoidal colon and rectum was taken as midpoint, where to fold and suture seromuscular layer adjacent to sigmoidal colon and rectum. Intestinal canal was split over 20-24 cm along antimesenteric border in an inverted "V" shape. The wall of adjacent sigmoid colon and rectum was all sutured with catgut continuously till the nadir. The left and right ureters were dissociated and pulled out of the incision, and then derived to the paries medialis and posterior of sigma neobladder. Ureters were pulled out of two selected entrances on the neighboring intestinal wall. From these two entrances a 2-3 cm submucosal tunnel was built downwardly. A small circular incision was built on the mucosa of lower tunnel. The ureter could go through the tunnel and the mucosa of ureteral end was connected with the intestinal mucosa. An 8 French (F) supportive silicone catheter was implanted in the ureters till the pelvis, fixed and marked, and driven out of the anus. The ends from left or right ureter were marked correspondingly to observe the urine output from left and right kidney (Figure). The paries anterior of neobladder was sutured to construct the urinary reservoir, which was placed in the abdominal cavity and was fastened to the longitudinal ligaments of sacral promontory.<sup>(3)</sup> After



**Figure .** A: Reconfiguration of 20 to 24 cm of rectosigmoid into U shape to construct Mainz II pouch. B: Submucosal tunnel technique for bilateral normal caliber ureter, bilateral ureteral stents and anal tube are drawn out extracorporeally through the anus.

the surgery the patient should perform ambrosia and intravenous injection with high nutrient for 5-7 days, and sustaining gastro-intestinal decompression 3-5 days. The anal tube was removed 5-7 days postoperatively and the two ureter supportive catheters were removed or self-released 10-14 days postoperatively.

#### **Follow-up**

Postoperatively, patients were evaluated at 3-month intervals for the first year, with 6-month intervals for the years 2 and 3, and annually thereafter. Urodynamic tests of urinary reservoir and ultrasound of upper urinary tract were performed at six month, one, five, ten and fifteen years, postoperatively. Intravenous urography (IVU) examination was conducted on the patients with hydronephrosis. Hydronephrosis, as well as vesicoureteral reflux and urinary tract infections were recorded.

Interviews and frequency-volume charts were used to determine voiding behavior, daytime and nighttime continence. We defined daytime continence as completely dry without use of a pad and nighttime continence as completely dry with 2 or fewer voids per night. A satisfactory continence result was defined if no more than 1 pad was required during the day or night. All other cases were defined as incontinent.

The European Organization for Research and Treatment of Cancer Quality of Life Questionnaire (EORTC QLQ-C30) survey was utilized to estimate the general health state of the patients. In this survey, two subjective answers from the patients were referred as the most characteristic of their health state and life quality

**Table 1.** Clinical and demographic characteristics of participants.

Variables	Values
Sex, no. (%)	
Male	40 (88.9)
Female	5 (11.1)
Age (years), mean (range)	59 (38-70)
Histopathology, no. (%)	
Transitional cell carcinoma	40 (88.9)
Adenocarcinoma	3 (6.7)
Squamous carcinoma	2 (4.4)
Radical urethrectomy, no. (%)	
Male	32 (80)
Female	0.0 (0.0)

## **RESULTS**

### **Follow-up**

All operations were performed successfully and there was no serious complication. The postoperative follow-up ranged from 6 months to 19 years with an average of 6 years. Fourteen patients died from tumor recurrence and metastasis, and 4 patients died from cardiovascular and cerebrovascular diseases. The patients survived more than 15 years in 2 cases, 10-15 years in 4 cases, 5-10 years in 10 cases and 6 months to 5 years in 11 cases.

### **Continence and Voiding**

After removal of anal tube, 45 patients had different degrees of daytime and nighttime incontinence in the early days. They passed urine and stools 6 to 10 times (mean 8 times) in the daytime, while 4 to 8 times (mean 5 times) at night. Three months after the surgery, all the patients well controlled defecation and urination; they passed urine and stools 4 to 6 times (mean 5 times) in the daytime and 1 to 4 times (mean 2 times) at night. From 6 months on, all the patients satisfied with urinary control. Good urinary control in the daytime was observed in 27 cases from six months to 15 years in follow-up. Three patients required urinal pad. Urinating and stools separately were achieved in 80% cases. Urinary incontinence occurred in six patients when they had diarrhea and cough. Table 2 demonstrates patient voiding patterns during follow-up.

### **Urodynamic Testing**

Maximum storage capacity was 270-600 mL with an average

**Table 2.** Daytime and nighttime voiding patterns of 45 patients with sigmoid-rectal pouch.

Voiding	< 3-month (mean)	3-6 month (mean)	≥ 6 month (mean)
Daytime			
Times	6-10 (8)	4-6 (5)	4-6 (5)
Pad use (piece)	2.0	1.0	0.0
Continence (%)	0.0	95.6	93.3
Nighttime			
Times	4-8 (5)	1-4 (2)	1-4 (2)
Pad use (piece)	2.0	1.0	0.1
Continence (%)	0.0	88.9	91.1

of 375 mL (more than 500 mL was considered as reverse flow in sigmoid colon); the average filling pressure in neobladder was 26 cmH<sub>2</sub>O. The compliance of sigmoid-rectal pouch was fine with an average of 30 (range 18-40) mL/cmH<sub>2</sub>O. The maximum pressure in neobladder at urination [15-30 cmH<sub>2</sub>O (average, 26 cmH<sub>2</sub>O)] was equal to abdominal pressure at micturition.

#### Upper Urinary Tract

There was one case of high fever complicated with unilateral hydronephrosis in the early days, which was cured by pyelotomy. In long-term follow-up, five patients had waist pain with fever and were relieved by anti-inflammatory therapy. Unilateral hydronephrosis was indicated by ultrasound and IVU in six cases. Early metabolic acidosis was observed in two patients who were recovered three months later. In the long-term follow-up, there was no metabolic acidosis, retrograde infection of the kidney or renal failure.

#### QoL Evaluation

The index of QoL and general health state of the patients were evaluated by EORTC QLQ C-30 survey at 1 year post-operatively (Table 3).

#### Secondary Tumors

There was no colorectal cancer in the 45 sigmoid-rectal pouch patients during follow up but one 64-year old patient was diagnosed as benign polyps of colon at the 2nd year postoperatively. The polyps were resected via a wire loop using colonoscopy.

## DISCUSSION

The options of surgical procedures for UD are according to specific conditions of patients, such as age, complications, life expectancy and the history of pelvic operation, as well as

the requirements of patients and the experience of surgeons. The ultimate goal of treatment is protecting renal function and improving QoL in patients.<sup>(4)</sup> Moreover, UD has not only achieved simple urine shunt and the protection of upper urinary tract, but also has reconstructed the lower urinary tract, which provides a safe, controllable method to storage and discharge urine, improves the patient's QoL. Currently, the most common procedure is orthotopic neobladder. However, only non-continent UD, such as Bricker operation, can be applied to most patients who simultaneously underwent total urethrectomy. The patients have to carry urine collection bag lifelong due to abdominal colostomy in Bricker operation, and the incidence of stoma complication is up to 24%.<sup>(5)</sup> Neobladder, allowing micturition through urethra, is most mimicking physiological state, but not suitable for the patients who have urethrostenosis or undergo urethrectomy. In addition, the surgery is complex, and the incidence of early and late operation complications is up to 12-37%.<sup>(6)</sup> Mainz pouch II is confluence of urine and feces improved by Fisch, which allows patients to control urination by anus. This operation could approve urinary continence, improve the quality of patients' life and the incidence of complications is acceptable. Because of the resection of all posterior urethra, the recurrence of cancer is the same as Bricker operation theoretically. From 1993, we performed this operation on 45 selective bladder cancer patients and the inclusion criteria mainly included cancers in trigone of bladder, bladder-neck and men's posterior urethra and patients expected without good compliance. For investigating the long-term effect of Mainz pouch II, we follow-up visited all patients.

Mainz pouch II controls urination by anus. Therefore, the function of anal sphincter was assessed in the patients before

**Table 3.** QLQ C-30 survey: life quality, health status and number of patients.

QLQ C-30 scale	1	2	3	4	5	6	7
	<b>Very bad</b>						<b>Excellent</b>
No. of patients							
Health status	1	2	14	15	11	1	1
Life quality	2	2	13	15	11	1	1

**Key:** EORTC QLQ-C30, European Organization for Research and Treatment of Cancer Quality of Life Questionnaire.

surgery.<sup>(2,6)</sup> All the patients in our study underwent digital rectal examination and urodynamic examination to exclude patients with dysfunction of anal sphincter. After ordinary enema and defecation, 500 mL saline with diodone was used for retention enema and imaging. We observed the shape and pathological changes of rectum and sigmoid colon, estimated rectal bladder capacity and calculated urination time controlled by anus. The pressure of anal sphincter was measured with urodynamic device after enema. Although all the patients had different degrees of urinary incontinence in early time, especially at night, they could well control urination 6 months after the surgery. The longer the postoperative time lasted, the better the effect of urinary control was achieved, which was speculated to correlated with that long retention of anal tube damaged the function of anal sphincter,<sup>(6)</sup> and colonic mucosal did not adapt to the stimulation of urine, as well as anastomotic edema in the early days after surgery. The stimulation from urine reduced over time, and the function of anal sphincter gradually increased. Six patients lived more than ten years and had no incontinence in the day time; mild urinary incontinence occurred only when they had diarrhea and cough. Moreover, most patients passed clear urine and stools separately, which was consistent with previous reports.<sup>(7-9)</sup>

The common complications of various neobladder are urinary incontinence induced by inadequate urinary control and dysuria resulted from excessive urinary control, which turns better 6 to 12 months after surgery when the capacity and compliance of neobladder apparently improve. Bedwetting rate is especially high at night, which shows a huge difference in reports (0-67%). However, bedwetting rate of most orthotopic bladder at night is 20-30%.<sup>(10)</sup> Possible influencing factors are, detrusor-sphincter dyssynergia; the lack of feedback between neobladder and brain arousal system when

the new bladder is filling at night; the deficiency of urethra sensory controlling branch, belonging to the basin plexus of pudendal nerve, could lead to the protective reflection deficiency of external sphincter when the near-end urethra is stimulated by urine; reduced muscle tension of pelvic floor at night; nocturia (due to osmotic diuresis of neobladder at night); the neobladder filling increases the occurrence of peristaltic wave.<sup>(11,12)</sup> Mainz pouch II allows patients to control urination by anus; uriesthesia is from awareness of defecation; urinary control depends on the function of anal sphincter. All the patients in our study controlled urination well, which was probably associated with evaluation of the function of anal sphincter before surgery and the training of contraction of anal sphincter after operation. There was no dysuria or residual urine in all cases. Dysuria is one of the common complications of neobladder. It is reported that 4-25% of patients need intermittent clean self-catheterization to void, which results from several reasons, including urethral angle; the opening of new bladder is not in the lowest position; allantoic wall blocks urethra opening; the patients are unable to urinate by using abdominal pressure or relaxing pelvic floor and etc.<sup>(13)</sup> The incidence of intermittent clean self-catheterization in female patients is 21-61%<sup>(14,15)</sup> due to chronic urine retention and urethral angle. Moreover, constipation is avoided because urine flushes rectum. Female patients do not change their habit of crouch a micturition.

Secondary colorectal cancer is always a concern in sigmoid-rectal pouch patients. The total ileo colon tumor risk in ureterosigmoidostomy (2.58%) was significantly higher than in other continent forms of UD.<sup>(16)</sup> Because the sample is small in the present study, we could not draw any conclusion on colorectal cancer rate in the 45 sigmoid-rectal pouch patients. The ideal urinary reservoir should have large capacity, low pressure and good compliance. The capacity of sigmoid-rec-

tal pouch is equal to capacity of folded urinary reservoir plus rectum, and colon that has reverse flow can also be used as urinary reservoir with full bladder. However, the patients are not recommended to hold urine because it might increase the chance of retrograde acute pyelonephritis, and subsequent increase the risk of renal function deterioration.<sup>(17)</sup> Micturition depends on abdominal strain instead of strong contraction of urinary reservoir. In addition, the awareness of defecation from rectal can replace bladder sensation, which is missing for orthotopic neobladder. Some patients pass clear urine at most time.

Urinary reservoir is established by folding sigmoid-colon rectum, which is separated from the cavity of sigmoid colon and rectum after fixation upwards and backwards, and mimic colonic diverticula. The urine continuously flushes downwards, stools form in sigmoid colon and are passed after arriving rectum, which rarely retrogrades to urinary reservoir. In addition, low pressure and good compliance of neobladder comply with resistance to reverse flow of sigmoid colon, which reduces the chance of retrograde infection. In long-term follow-up, five patients had flank pain with fever caused by retrograde infection and were treated by antibiotics. Due to the confluence of urine and excrement, urine and stool routine tests are not available. Therefore, the diagnosis of retrograde infection stands on the symptoms, such as fever with flank pain, and sometimes nephrostomy drainage is performed as early as possible if the efficacy is not satisfying. Hydronephrosis is one of the complications of UD. Various anti-reflux techniques always might result in anastomotic stenosis between ureter and urinary reservoir. It is controversial with respect to ureterocystic anti reflux replantation, which includes submucosal tunneling, ureteral papilla implantation and etc. Some people believe neobladder without high pressure and urinary catheterization rarely has reflex and infection, and anti-reflux techniques are not necessary to be performed. All the patients had submucosal tunneling, in which the tunnel was wide enough at anastomosis. Emphasis on anti-reflux increases the chance of obstruction. There were six cases of mild unilateral hydronephrosis during the follow up interval of 3 to 6 months. The temporary hydronephrosis might be correlated to the edema of anastomotic stoma mucosa. No special therapy was applied and the hydronephrosis disappeared gradually. Recently, Jin and colleagues<sup>(18)</sup> has

demonstrated that ureteral obstruction is the first and independent risk factor of renal function damage in the patients who survive more than 10 years after ileal conduit UD and ileal orthotopic bladder.

In ileal, colonic neobladder and all kinds of intestinal bladder substitution, the incidences of pure metabolic acidosis are 5.5%, 13.3% and 11.1%, and the incidence with concomitant hyperchloremia are 5.5%, 8.9% and 7.9%, respectively. Oral sodium bicarbonate is usually administered for acidosis.<sup>(19)</sup> Mainz pouch II involves less and lower intestinal canal, thus the complications occur less, which is one of the advantages. There were two cases of metabolic acidosis and hypokalemia who discontinued the 1.5 g postoperative bicarbonate daily protocol, and were corrected with oral intake of bicarbonate and potassium tablets. The incidence of metabolic acidosis and hypokalemia was lower than previous report which described high incidence of acidosis and even lethal acidosis.<sup>(7,20)</sup> This was considered to correlate with long segment of intestine and inadequate compensatory renal function.

The surgery is simple and easy for surgeons to perform and for patients to accept. The procedure involves folding and suture of seromuscular layer adjacent to sigmoid colon and rectum, as well as simple submucosal tunneling for anastomosis. There is no need to intercept large segment of intestine canal and perform complex anti reflex techniques. The index of QoL were high in patients.<sup>(21-23)</sup> Except some male patients were not used to crouch a micturition, most patients satisfied QoL in our research.

The ideal UD should meet the following conditions: neobladder can independently control urination, enough capacity, low pressure, resistant to retrograde infection, without metabolic disorders, simple procedures, easy to learn and low incidence of surgical complications.<sup>(24)</sup> Most pristine urochesia diversions were abandoned because of lack of aforementioned characteristics, but some improved operations can also reach satisfied effect and improve the patients' QoL. According to our follow-up, Mainz pouch II basically meets the above requirements. It may be an ideal UD technique for patients who need total urethrectomy due to tumor in urinary tract, have normal function of anal sphincter, and are unable to pass urine through urethra because of urethrostenosis.

One of the most important objective of UD is to improve patients' QoL. Orthotopic neobladder is the main method

selected by many medical centers because it could make patients to recover physiological urination as possible. Its long-term complications includes, urinary incontinence (20-30%), ureter-intestines anastomotic stenosis (3-18%), retention of urine (4-12%), metabolic disease and etc.<sup>(25,26)</sup> Some urologists think the reasonable urinary reservoir and QoL improving of Mainz pouch II may be superior to orthotopic neobladder, so patients should be told the advantages and disadvantages of both operations and return the options to patients themselves if the pathogenic conditions permit.

## CONFLICT OF INTEREST

None declared.

## REFERENCES

- Jemal A, Bray F, Center MM, Ferlay J, Ward E, Forman D. Global cancer statistics 2008. *CA Cancer J Clin.* 2011;61:69-70.
- Fleshner NE, Herr HW, Stewart AK, Murphy GP, Mettlin C, Menck HR. The National Cancer Data Base report on bladder carcinoma. *Cancer.* 1996;78:1505-13.
- Lampel A, Fisch M, Stein R, et al. Continent diversion with the Mainz pouch. *World J Urol.* 1996;14:85-91.
- Elmar WG, Alexander R, Wiking M. Complications and quality of life following urinary diversion after cystectomy. *EAU Update Series.* 2005;156-68.
- Madersbacher S, Schmidt J, Ebele JM, et al. Long-term outcome of ileal conduit diversion. *J Urol.* 2003;169:985-90.
- Szűcs M, Keszthelyi A, Szendrői A, et al. Investigation of anal sphincter function following Mainz pouch type II urinary diversion after radical cystectomy. *Int Urol Nephrol.* 2012;44:1013-20.
- Zhvania G, Mshvildadze Sh, Managadze G, Khvadagiani G. Results of radical cystectomy with Mainz pouch II diversion (single institution experience). *Georgian Med News.* 2012;211:7-13.
- Alemu MH: Mainz II pouch: continent urinary diversion, for bladder extrophy epispadia complex and irreparable VVF: a 5 year comprehensive retrospective analysis. *Ethiop Med J.* 2010;48:57-62.
- Sherwani Afak Y, Wazir BS, Hamid A, Wani MS, Aziz R. Comparative study of various forms of urinary diversion after radical cystectomy in muscle invasive carcinoma urinary bladder. *Int J Health Sci.* 2009;3:3-11.
- Hautmann RE, Abol-Enein H, Hafez K, et al. Urinary diversion. *Urology.* 2007;69 (1 Suppl):17-49.
- Ghoneim MA, Shaaban AA, Mahran MR, Kock NG. Further experience with the urethral Kock pouch. *J Urol.* 1992;147:361-5.
- El Bahnasawy MS, Osman Y, Gomha MA, Shaaban AA, Ashamallah A, Ghoneim MA. Nocturnal enuresis in men with an orthotopic ileal reservoir: urodynamic evaluation. *J Urol.* 2000;164:10-3.
- Steers WD. Voiding dysfunction in the orthotopic neobladder. *World J Urol.* 2000;18:330-7.
- Anderson CB, Cookson MS, Chang SS, Clark PE, Smith JA Jr, Kaufman MR. Voiding function in women with orthotopic neobladder urinary diversion. *J Urol.* 2012;188:200-4.
- Finley DS, Lee U, McDonough D, Raz S, deKernion J. Urinary retention after orthotopic neobladder substitution in females. *J Urol.* 2011;186:1364-9.
- Hautmann RE, Abol-Enein H, Davidsson T, et al. ICUD-EAU International Consultation on Bladder Cancer 2012: Urinary diversion. *Eur Urol.* 2013; 63:67-80
- Osawa T, Shinohara N, Maruyama S, et al. Long-term renal function outcomes in bladder cancer after radical cystectomy. *Urol J.* 2013;10:784-9.
- Jin XD, Roethlisberger S, Burkhard FC, Birkhaeuser F, Thoeny HC, Studer UE. Long-term renal function after urinary diversion by ileal conduit or orthotopic ileal bladder substitution. *Eur Urol.* 2012;61:491-7.
- Varol C, Studer UE. Managing patients after an ileal orthotopic bladder substitution. *J Br Urol.* 2004;93:266-70.
- Ignjatovic I, Basic D. Modified Mainz pouch II (Sigma Rectum pouch) urinary diversion: 12 years experience. *Acta Chir Iugosl.* 2007;54:73-5.
- Dzamic Z, Hadzi Djokic J, Acimovic M, et al. Modified Mainz pouch II urinary diversion and quality of life. *Acta Chir Iugosl.* 2007;54:57-62.
- Romics I, Riesz P, Keszthelyi A, Pánovics J. Experiences with radical cystectomy combined with urinary diversion by ureteral sigma pouch (Mainz-pouch II) in bladder cancer patients. *Orv Hetil.* 2006;147:1691-6.
- Patrick JB, Peter A, Herbert H, et al. Health-related quality-of-life following modified ureterosigmoidostomy (Mainz pouch II) as continent urinary diversion. *Eur Urol.* 2004;46:591-7.
- Ardelt PU, Woodhouse CR, Riedmiller H, Gerharz EW. The efferent segment in continent cutaneous urinary diversion: a comprehensive review of the literature. *BJU Int.* 2012;109:288-97.
- Stein JP, Dunn MD, Quek ML, Miranda G, Skinner DG. The orthotopic T pouch ileal neobladder: experience with 209 patients. *J Urol.* 2004;172:584-7.
- Abol-Enein H, Ghoneim MA. Functional results of orthotopic ileal neobladder with serous-lined extramural ureteral reimplantation: experience with 450 patients. *J Urol.* 2001;165:1427-32.