

Laparoendoscopic Single-Site Adrenalectomy sans Transumbilical Approach: Initial Experience in Japan

Shogo Inoue, Kenichiro Ikeda, Mitsuru Kajiwara, Jun Teishima, Akio Matsubara

Department of Urology,
Hiroshima University
Graduate School of Bio-
medical Sciences, Hiro-
shima, Japan.

Corresponding Author:
Shogo Inoue, MD
Department of Urology,
Hiroshima University
Graduate School of Bio-
medical Sciences, 1-2-3
Kasumi, Minami-ku, Hi-
roshima, 7348551, Japan.

Tel: +81 82 257 5242
Fax: +81 82 257 5244
E-mail: inosyogo@hiro-
shima-u.ac.jp

Received July 2013
Accepted February 2014

Purpose: The use of laparoendoscopic single-site (LESS) surgery has been increasing. The LESS procedure has been done for various urological diseases and studies have shown that it results in less pain, shorter hospital stays and excellent cosmetic outcomes.

Materials and Methods: We describe our initial experience with LESS adrenalectomy without the use of the transumbilical approach. The participants were 16 consecutive patients who underwent LESS adrenalectomy using a SILS port™ (Covidien, Mansfield, MA, USA) at Hiroshima University Hospital. Various parameters including the insufflation time, estimated blood loss, resumption of oral intake and complications were analyzed.

Results: The adrenalectomy was completed successfully with no major intraoperative complications in 15 of the patients. One LESS adrenalectomy was converted to a conventional laparoscopic adrenalectomy by placement of two additional 12 mm trocars; this patient was therefore excluded from the study. The mean (range) patient age was 53.8 (35-69) years, body mass index (BMI) was 23.5 (20.7-27.2) kg/m², tumor size was 19.8 (9-45) mm, insufflation time was 188.0 (95-340) min and estimated blood loss was 36.3 (10-80) mL. In all cases articulating instruments were used for satisfactory dissection and triangulation. One bowel injury (serosal) occurred and was repaired in the open laparotomy before SILS port™ insertion. All patients at the follow-up visit were satisfied and pleased with their scars.

Conclusion: We found LESS adrenalectomy to be apparently safe, effective and minimally invasive for adrenal diseases. In our opinion, LESS adrenalectomy without using the transumbilical approach is feasible and easy to introduce.

Keywords: adrenalectomy; laparoscopy; methods; standards; postoperative complications; quality improvement.

INTRODUCTION

Since the early 1990s, laparoscopic adrenalectomy has become a standard procedure for the majority of patients with a surgical adrenal tumor.⁽¹⁾ The conventional laparoscopic adrenalectomy uses three or four ports, most commonly one 12 mm and two or three 5 mm. A paradigm shift in the field of minimally invasive surgery is now underway, as laparoscopy progresses toward scar less techniques. With the advent of multichannel single ports as well as curved and articulating instruments, the possibility of complex laparoscopy through a single incision has been reported. As a result, the use of laparoendoscopic single-site (LESS) surgery has increased. Over the last few years there has been increasing enthusiasm for and growing interest in this novel minimally invasive surgical procedure.⁽²⁾ LESS surgery has been done for various urological diseases, and studies have shown that it results in less pain, shorter hospital stays and excellent cosmetic outcomes.⁽³⁾ However, evaluation of LESS cosmesis has largely entailed subjective operator assessment, with objective evaluation limited by small sample sizes and evaluation as a secondary endpoint. LESS adrenalectomy through the umbilical access can be extremely challenging due to the angle of approach and difficult organ retraction. There have been few reports on the use of LESS adrenalectomy without using the transumbilical approach for Japanese patients. In this report, we describe our initial experience with LESS adrenalectomy in Japanese patients using a multichannel single port without using the transumbilical approach.

MATERIALS AND METHODS

Participants

Between November 2009 and January 2011, sixteen consecutive patients with an adrenal tumor (12 primary aldosteronism, 2 Cushing syndrome, and 2 preclinical Cushing syndrome) underwent transperitoneal LESS adrenalectomy by two surgeons (A.M. and S.I.) at Hiroshima University Hospital. All patients consented to LESS adrenalectomy and additional incisions if necessary. The surgeons had previously undergone animal lab training. Various parameters including the insufflation time, estimated blood loss, pain scale, resumption of oral intake and complications were analyzed. Convalescence was measured by using a visual analogue pain scale (VAS) from 0 (negligible pain) to 10 (severe discomfort).

Surgical Technique

Under general anesthesia, the patients were placed in the 60° modified flank position; the operators stood facing the abdomen, between the arcus costalis on the ipsilateral side and the umbilicus. A 2 cm skin incision and an access into the peritoneal cavity were made by open laparotomy. Then, a multichannel port (SILS port™, Covidien, Mansfield, MA, USA) was placed in the incision. An additional port was used in right-sided adrenal tumor for liver traction.⁽⁴⁾ A 5-mm trocar is inserted in the right lateral abdomen for a snake-retractor to pull up the lateral segment of the liver and prevent liver injury. To minimize instrument collision, a flexible 5 mm 0° high-definition laparoscope (Olympus, Tokyo, Japan) was used. Pneumoperitoneum was induced

by CO₂ gas insufflation to 8 mmHg.

The surgical strategy followed that for a conventional transperitoneal adrenalectomy.⁽⁵⁾ Specifically, the Toldt line and the typical vascular landmarks (inferior vena cava and renal vein for right- and left-sided adrenal tumor, respectively) were dissected and exposed using a bent laparoscopic instrument (Roticulator Endo Dissect™, Covidien, Mansfield, MA, USA) and straight standard instruments (**Figure 1**). The adrenal veins were identified, controlled with two 5 mm polymer locking clips (Hem-o-lok, Teleflex Medical, Research Triangle Park, N.C., USA), one proximally and one distally and then divided. A 5 mm LigaSure™ (Covidien, Mansfield, MA, USA) was used to complete the adrenal gland dissection. Then hemostasis was ensured, the entire adrenal gland involving the tumor was freed within the abdomen and placed in an EndoCatch Gold™ (Covidien, Mansfield, MA, USA) inserted through the 12 mm instrument channel. The specimen was retrieved together with the SILS port™ without any further skin incision in all cases. A surgical suction drain was left in place through the surgical port. All patients underwent transperitoneal LESS adrenalectomy.

RESULTS

The patient demographics and surgical outcomes are shown in **Tables 1** and **2**. The mean (range) patient age was 53.8 years and mean body mass index (BMI) was 23.5 kg/m². There was no conversion to open surgery for any patient. One patient, however, was switched to a conventional laparoscopic adrenalectomy by the placement of two additional 12 mm trocars. This patient was slightly obese (BMI 27.2 kg/m²), resulting in a very small working space, which made handling the instruments very difficult. This indicates that the patient selection criteria were less stringent than expected. For the remaining 15 patients, the LESS adrenalectomy was completed successfully without any intraoperative complications. With growing experience, indications can be expanded to include more challenging cases.

In all cases, the SILS port™ was easily inserted, and the articulating instruments facilitated satisfactory dissection and triangulation. The mean (range) insufflation time was 188.0 (95-340) min, and there was learning curve (**Figure 2**). The mean estimated blood loss was 36.3 (10-80) mL, and the dissected tumor weight was 21.2 (8-58) g. The mean insufflation time and estimated blood loss were not significantly different for left side tumors (212.3 min; 27.5 mL) and right side tumors (141.3 min, $P = .07$; 22.9 mL, $P = .66$). A minor serosal injury occurred in patient #1 during open laparotomy and was in situ repaired with intermittent sutures before SILS port™ insertion. None of the patients required blood transfusion. The mean VAS was 2.5 on the first postoperative day (POD) and 0.4 on the seventh. Mean length of hospital stay was 7.9 (5-12) days. All patients at the follow-up visit were satisfied and pleased with their scars (**Figure 3**).

DISCUSSION

Table 1. Patients demographics.

Variables	Values
No. of patients	16
Gender, no. (%)	
Male	10 (62.5)
Female	6 (37.5)
Age, year, mean (range)	53.8 (35-69)
BMI, kg/m ² , mean (range)	23.5 (20.7-27.2)
Preoperative diagnosis, no. (%)	
Primary aldosteronism	12 (75.0)
Preclinical Cushing's syndrome	2 (12.5)
Cushing's syndrome	2 (12.5)
Laterality, no. (%)	
Right	8 (50.0)
Left	8 (50.0)

Abbreviation: BMI, body mass index.

Laparoscopic adrenalectomy has become the gold standard for the treatment of adrenal tumors, and it has various approaches.⁽⁶⁾ Many investigators have developed and reported techniques for reducing the number of ports required to perform safe laparoscopic surgery.⁽⁷⁾ Although several efforts have been made to further reduce invasiveness in laparoscopic adrenalectomy, an incision is ultimately required for specimen retrieval.⁽⁸⁾

The SILS port™ (**Figure 1**) has three legs, each 5 mm in diameter, and one insufflation line and requires only a 20 mm longitudinal incision. Air leaks at the operative sites can be avoided by using a SILS port™. Three instruments with diameters of 5 mm or less can be used simultaneously by inserting each one through a port leg. Alternatively, two 5 mm port legs can be replaced with one 12 mm port leg, enabling the surgeon to use a 10 mm instrument, such as an EndoCatch Gold™, by passing it through the 12 mm channel. The SILS port™ allowed us to perform the whole procedure up until the final incision for specimen retrieval.

A key problem with the use of the LESS procedure is the inability to triangulate the positions of the instruments, which are inserted in parallel.⁽⁹⁾ We had difficulty driving the instruments and avoiding internal and external collisions. These limitations are typical of all LESS procedures, reflecting the small space between the hands of the surgeon and those of the assistant. The introduction of advanced equipment and technical modifications obscured the concept of an essential triangulation in favor of LESS.⁽¹⁰⁾ Cooperation between the surgeons requires skilled camera driving and constant coordination.⁽¹¹⁾ These skills can be honed through laboratory training.⁽¹²⁾ To achieve optimal dissection and triangulation, we used articulating instruments. There is room for technological improvement in the trocars, cameras and instruments.^(4,9) Further development of ergonomically shaped handles designed for LESS would help promote wide adoption of this technique. In this

Table 2. Surgical outcomes.

Variables	Values
Conversion, no. (%)	1 (6.3)
Tumor size, mean (range) (mm)	19.8 (9-45)
Insufflation time, mean (range) (min)	188.0 (95-340)
Estimated blood loss, mean (range) (mL)	36.3 (10-80)
Dissected tumor weight, mean (range) (g)	21.2 (8-58)
Transfusion, no. (%)	0.0 (0.0)
Resumption of oral intake, POD, mean	1.0
Complications, no. (%)	1.0 (6.3)
VAS, mean (range)	
POD 1	2.5 (0-6)
POD 7	0.4 (0-1)

Abbreviations: VAS, visual analog scale; POD, post-operative day.

initial experience, the insufflation time trended down as the surgeons became more experienced with the articulating instruments.

Until now, the main benefit of LESS surgery over conventional laparoscopic surgery has been the improved cosmetic outcome. Few studies have been conducted comparing LESS surgery with conventional laparoscopic surgery. Addition of working port risks morbidity from bleeding, hernia and internal organ damage.⁽¹³⁾ In addition to the cosmetic advantage, LESS has the potential to minimize or eliminate other complications due to surgical incision. All 15 patients underwent surgery safely without major complications. While LESS surgery is more difficult than conventional laparoscopic surgery, the patients in our study made a fast and relatively painless recovery.

The first successful LESS adrenalectomy was reported by Cindolo and colleagues⁽¹⁴⁾ for the excision of a 4 cm non-functional left adrenal mass using a 3 cm incision. Over the last 2 years, several series of LESS adrenalectomy have been reported, so that available evidence on this surgical procedure is larger.⁽¹⁵⁾ One of our LESS adrenalectomy patients had a relatively high BMI (27.2 kg/m²) and although he had a great deal of fat tissue, the operation was successfully performed in two hours. Although it has been reported that a high BMI might be a contraindication for LESS,⁽¹⁶⁾ we believe that selection of our subcostal approach might reduce the difficulty of LESS adrenalectomy in patients with high BMI.

The most common position for access in LESS surgery has been the umbilicus for cosmetic reasons. However, LESS adrenalectomy through the umbilical access is extremely challenging due to the angle of approach and difficult organ retraction. Moreover, as the target area for dissection becomes more cranial, dissection with the transumbilical LESS procedure will become extremely difficult. Our subcostal approach allowed a wider working space for instrumentation than the retroperitoneal approach and more direct and shorter access to the tumor compared with the transumbilical approach.⁽¹⁷⁾ There is also the

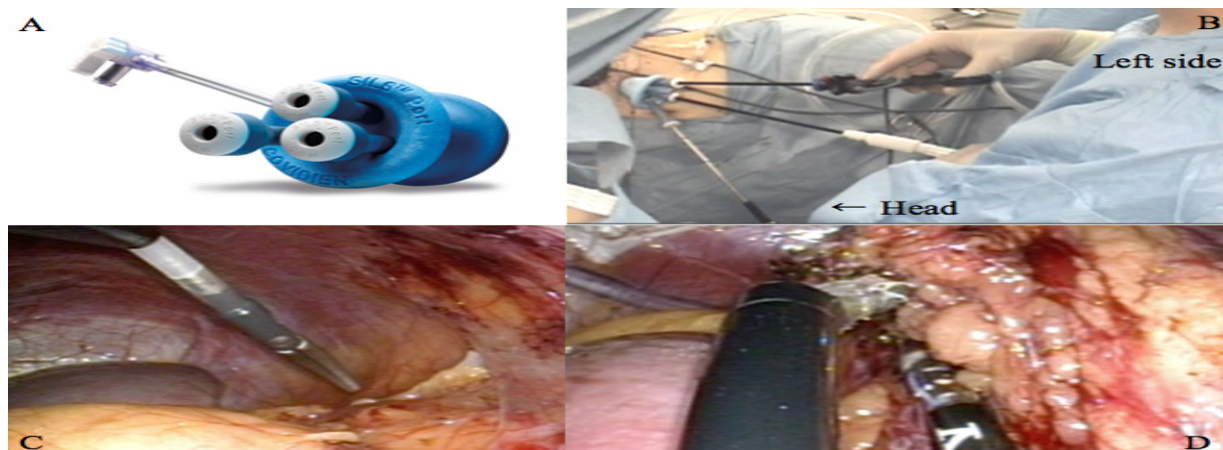


Figure 1. Laparoendoscopic single-site adrenalectomy; (A) multi-channel SILS port™, (B) outside view and (C) inside view during laparoendoscopic single-site adrenalectomy, (D) separation of left adrenal tumor using Reticulator Endo Dissect™ and LigaSure™ device.

question of whether our subcostal approach to LESS adrenalectomy provides more benefits than the transumbilical approach. This question remains for future research.

There were limitations to this study. The small sample size (15 patients) makes it impossible to state any general conclusion. Few studies have compared LESS surgery with conventional laparoscopic surgery. A more extensive randomized comparison between LESS surgery and conventional laparoscopic surgery using tools designed to detect differences in morbidity and assess cosmetic benefits will ultimately determine the future of LESS surgery.⁽¹⁸⁾

We believe that continuing advances in LESS technology will improve this procedure in the near future.⁽⁸⁾ LESS surgery should still be explored with the greatest consideration of all ethical and methodological issues. In our opinion, LESS adrenalectomy without using the transumbilical approach is a safe procedure, with the additional benefit of being minimally invasive; however, long-term follow-up is necessary.

CONCLUSION

Even though these first cases represent only our initial experience with LESS adrenalectomy, we have found that this procedure is apparently safe, effective and minimally invasive for adrenal diseases. LESS adrenalectomy has great potential as a new laparoscopic procedure

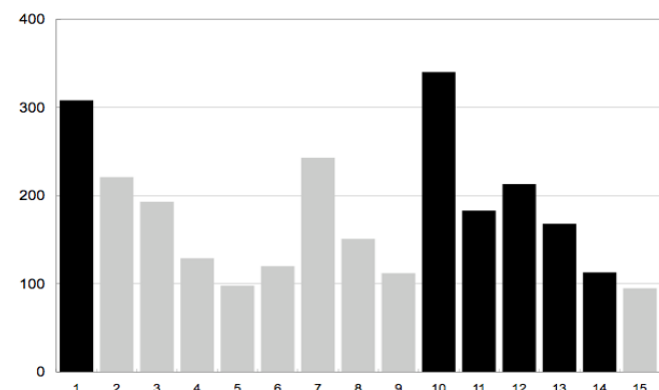


Figure 2. Insufflation time in minutes; black is operator A and gray is operator B.

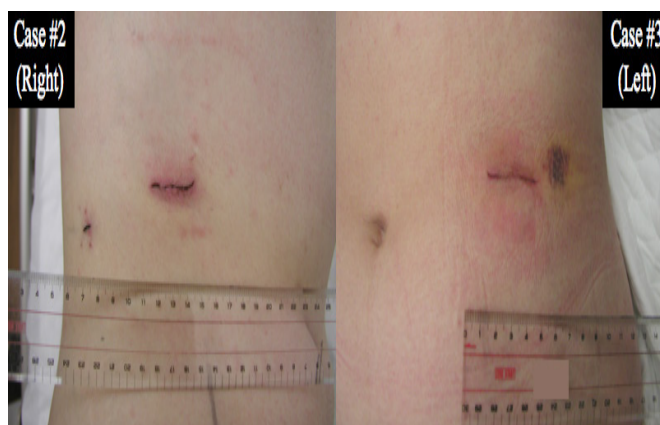


Figure 3. Postoperative appearance of laparoendoscopic single-site surgical incision.

resulting in fewer scars. In our opinion, LESS adrenalectomy without using the transumbilical approach is feasible and easy to introduce, but experience in standard laparoscopy should be accumulated, and patients should be accurately and rigorously screened prior to undergoing LESS adrenalectomy.

CONFLICT OF INTEREST

None declared.

REFERENCES

1. Guazzoni G, Cestari A, Montorsi F, et al. Current role of laparoscopic adrenalectomy. *Eur Urol.* 2001;40:8-16.
2. Autorino R, Cadeddu JA, Desai MM, et al. Laparoendoscopic single-site and natural orifice transluminal endoscopic surgery in urology: a critical analysis of the literature. *Eur Urol.* 2011;56:26-45.
3. Kaouk JH, Autorino R, Kim FJ, et al. Laparoendoscopic single-site surgery in urology: worldwide multi-institutional analysis of 1076 cases. *Eur Urol.* 2011;60:998-1005.
4. Gettman MT, Box G, Averch T, et al. Consensus statement on natural orifice transluminal endoscopic surgery and single-incision laparoscopic surgery: heralding a new era in urology? *Eur Urol.* 2008;53:1117-20.
5. Zacharias M, Haese A, Jurczok A, Stolzenburg JU, Fornara P. Transperi-

- toneal laparoscopic adrenalectomy: outline of the preoperative management, surgical approach, and outcome. *Eur Urol.* 2006;49:448-59.
6. McCauley LR, Nguyen MM. Laparoscopic radical adrenalectomy for cancer: long-term outcomes. *Curr Opin Urol.* 2008;18:134-8.
 7. Han WK, Park YH, Jeon HG, et al. The Feasibility of Laparoendoscopic Single-Site Nephrectomy: Initial Experience Using Home-made Single-port Device. *Urology.* 2010; 76: 862-5.
 8. Cindolo L, Gidaro S, Neri F, Tamburro FR, Schips L. Assessing feasibility and safety of laparoendoscopic single-site surgery adrenalectomy: initial experience. *J Endourol.* 2010;24:977-80.
 9. Stolzenburg JU, Kallidonis P, Hellowell G, et al. Technique of laproscopic-endoscopic single-site surgery radical nephrectomy. *Eur Urol.* 2009;56:644-50.
 10. Canes D, Desai MM, Aron M, et al. Transumbilical single-port surgery: evolution and current status. *Eur Urol.* 2008;54:1020-9.
 11. Cindolo L, Berardinelli F, Bellocchi R, Schips L. Laparoendoscopic Single-Site Unclamped Nephron-Sparing Surgery: A Case Report. *Eur Urol.* 2010;60:591-4.
 12. Kaouk JH, Haber GP, Goel RK, et al. Single-port laparoscopic surgery in urology: initial experience. *Urology.* 2008;71:3-6.
 13. Raman JD, Cadeddu JA, Rao P, Rane A. Single-incision laparoscopic surgery: initial urological experience and comparison with natural-orifice transluminal endoscopic surgery. *BJU Int.* 2008;101:1493-6.
 14. Cindolo L, Gidaro S, Tamburro FR, Schips L. Laparoendoscopic single-site left transperitoneal adrenalectomy. *Eur Urol.* 2010;57:911-4.
 15. Rane A, Cindolo L, Schips L, De Sio M, Autorino R. Laparoendoscopic single site (LESS) adrenalectomy: Technique and outcomes. *World J Urol.* 2012;30:597-604.
 16. Miyajima A, Hattori S, Maeda T, et al. Transumbilical approach for laparo-endoscopic single-site adrenalectomy: initial experience and short-term outcome. *Int J Urol.* 2012;19:331-5.
 17. Wang L, Liu B, Wu Z, et al. Comparison of single-surgeon series of transperitoneal laparoendoscopic single-site surgery and standard laparoscopic adrenalectomy. *Urology.* 2012;79:577-83.
 18. Desai MM, Berger AK, Brandina R, et al. Laparoendoscopic single-site surgery: initial hundred patients. *Urology.* 2009;74:805-12.