

## Idiopathic Spontaneous Bladder Perforation: A Rare Case

Erdal Uysal,<sup>1\*</sup> Mehmet Dokur,<sup>2</sup> Mehmet Ali Ikidag,<sup>3</sup> Turkey Kirdak<sup>4</sup>

**Keywords:** rupture; spontaneous; radiography; female; urinary bladder diseases; surgery.

### INTRODUCTION

Idiopathic, spontaneous bladder perforation is a very rare and life threatening clinical condition. It is not always possible to diagnose by radiological imaging.<sup>(1)</sup> On the other hand, cystography is more proper diagnostic choice for the patients who may have the possibility of urinary bladder perforation.<sup>(2)</sup> However, idiopathic, spontaneous bladder perforation is not primarily considered for the patients because of its rareness. Bladder perforations are usually iatrogenic or encountered secondary to trauma, malignancies or radiation exposure.<sup>(3)</sup> Patients usually admit with lower abdominal pain, dysuria or anuria. There are findings compatible with acute abdomen in physical examination. White blood cell count, urea, creatinine and C-reactive protein (CRP) levels may be elevated.<sup>(4)</sup> Blood is usually observed in urine test. Despite these radiological evaluations and findings in laboratory and physical examinations, correct diagnosis is usually made by laparoscopy. Urgent surgery, repairing and drainage are the first choice of therapy. Delay in diagnosis and treatment increase mortality and morbidity.<sup>(5)</sup> In this case report, we present a case of idiopathic spontaneous bladder perforation.

### CASE REPORT

A 78 years old female was admitted to our hospital with complaints of nausea, vomiting and severe abdominal pain, starting 4 days ago and gradually increasing. In our case, bladder perforation was not associated with cancer, ureterolithiasis, surgery, urinary retention and radiotherapy. Her prior medical history was insignificant, except for hypertension. There is also no voiding problem in her medical history. On physical examination, there were abdominal tenderness, defense and rebound in all quadrants, consistent with acute abdomen.

White blood cell was 5300/mm<sup>3</sup> (normal range, 4.8 -10.8 103/mm<sup>3</sup>). Blood chemistry tests revealed blood urine nitrogen 9 mg/dL (normal range, 6-20 mg/dL), serum creatinine level of 3 mg/dL (normal range, 0.6-1.3 mg/dL), potassium 6.2 mmol/L (normal range, 3.5-5.1 mmol/L) and CRP 372 mg/L (normal range, 0-5 mg/L). A urinary catheter was placed as a first step, and approximately 80 mL cloudy and dark urine was observed. However, we did not observe any increased amount of urine even after intravenous liquid replacement. Hematuria was observed in the urine test. Abdominal computed tomography (CT) scan revealed free fluid in perihepatic, perisplenic and both paracolic spaces, prominent in pelvic region and right subdiaphragmatic space. Due to the increased preoperative creatinine value, renal or urological pathologies could be also considered. Since there were the symptoms of acute abdomen, and existence of free abdominal liquid, gastrointestinal perforation was primarily considered and because of the possibility of idiopathic, spontaneous bladder perforation the patient underwent urgent laparotomy with midline incision. There were widespread free abdominal purulent fluid and peritonitis. Whole gastrointestinal tract was examined, but perforation was not found. A perforation in the dome of the bladder, which was 1 cm in size, was found eventually (**Figure**). Contours of the perforation were debrided, and inside of the bladder was explored, but no underlying condition was found. Multiple biopsies were taken from the bladder and perforation side. Samples from free fluid were taken for cytological and microbiological analyses and culture, but no bacterial growth was observed. Bladder was sutured primarily.

The patient was followed up in intensive care unit. She was intubated, and supportive positive inotropes were delivered. Wide spectrum antibacterial therapy was administered. Ventilator related pneumonia developed in 7th day of operation. Gram negative (pseudomonas species) and positive bacteria (staphylococcus) were found in broncho alveolar culture. Despite intensive therapy, sepsis and related multiple organ failures developed, and finally cardiac arrest occurred. The patient did not respond to resuscitation and she died on the fifteenth day after the surgery. Biopsy samples from bladder were reported as inflammation and necrosis. No atypical cells were found in the abdominal fluid sample.

### DISCUSSION

Spontaneous bladder perforation is usually not considered in the differential diagnosis of acute abdomen because of its

Departments of General Surgery,<sup>1</sup> Emergency<sup>2</sup> and Radiology<sup>3</sup>, Faculty of Medicine, Sanko University, 27090 Gaziantep, Turkey.

<sup>4</sup> Department of General Surgery, Faculty of Medicine, Uludag University, 16059 Bursa, Turkey.

\*Correspondence: Department of General Surgery, Faculty of Medicine, Sanko University, 27090 Gaziantep, Turkey.

Tel: +90 506 4845803. Fax: +90 342 2115010. E-mail: drerdaluyosal@hotmail.com.

Received October 2014 & Accepted January 2015

**Table.** Demographic and clinical characteristics of patients in different studies.

Study	Age/Sex	Comorbidity	Preoperative Time	Time of Diagnosis	Type of Surgery	Type of Operation	Mortality	Morbidity
Wieloch et al. <sup>1</sup>	84/F	HT+AF	Several day	Preoperatively	Open	Primary suture	Yes	No
Ahmed et al. <sup>5</sup>	47/F	No	Unknown	Preoperatively	Open	Primary suture	No	No
Al-Qassim et al. <sup>7</sup>	33/F	No	5 days	Preoperatively	Laparoscopy	Primary suture	No	No
Limon et al. <sup>6</sup>	52/F	Diabetes mellitus	Unknown	Preoperatively	Open	Primary suture	Yes	No
Cusano et al. <sup>4</sup>	60/F	No	Unknown	Preoperatively	Open	Primary suture	No	No
Albino G et al. <sup>3</sup>	73/M	No	Unknown	Preoperatively	Open	Primary suture	Yes	No
Current Case	78/F	HT	4 days	Preoperatively	Open	Primary suture	Yes	No

**Abbreviations:** HT, hypertension; AF, atrial fibrillation; F, female; M, male.

rarity. There is no specific diagnostic tool for it, and the diagnosis is usually made during operation.<sup>(4)</sup> The most prominent symptom is sudden onset of lower abdominal pain. Mortality and morbidity increase significantly in lack of prompt diagnosis and early treatment.<sup>(5)</sup> The most challenging factor that influences management and therapy, seems to be the difficulty in preoperative diagnosis. Also, in our case, diagnosis of preoperative bladder perforation was possible after the surgery.

Laparoscopy is an effective procedure for diagnosis and treatment which allows examining wide range of the area by a small incision. Also, in our case, this procedure might be used for diagnosis and treatment. However, we preferred direct laparotomy approach because the patient was in hypovolemia, and partial carbon dioxide level increased in the blood with low saturation. Another reason to choose direct laparotomy approach was also that the surgeon has less experience in this kind of urgent case.

Cystography is very helpful tool to diagnose bladder perforation. Especially, in the case of suspicion of bladder perforation, it provides accurate diagnosis as well as helps in planning medical treatment. Moreover, cystography is pretty successful tool to diagnose bladder perforation for the patients who experience penetrating or blunt abdominal trauma. Nowadays, computed

cystotomography is an alternative of conventional cystography to diagnose bladder perforation, and has several advantages including quickly and easily use, and allowing to investigate surrounding tissues in depth. On the other hand, cystography could be also considered to support the diagnosis of preoperative urinary bladder perforation, or, for small perforation, conservative treatment approach with urinary catheter might be also considered. However, we planned laparotomy for our patient due to the presence of the symptoms of acute abdomen.

Sampling of abdominal free fluid by ultrasound guidance and measuring the levels of urea and creatinine may be helpful in the diagnosis, but diagnosis of bladder perforation must be remembered before for this. Biopsy samples from bladder wall revealed inflammation and necrosis. But there were no clusters of bacteria. The reason of necrosis and inflammation could not be explained. The changes in bladder wall capillary microcirculation may lead to ischemia and necrosis.<sup>(6)</sup>

Late admission of the patient led to generalized peritonitis and adverse influence in healing process. Though intense care and broad spectrum antibacterial therapy, sepsis and multiple organ failures could not be prevented. The lack of early diagnosis and therapy onset may be the main reason of mortality in this patient. Bladder perforations are usually iatrogenic or encountered secondary to trauma, malignancies, or radiation exposure. Only a few cases of idiopathic spontaneous perforation of bladder are reported until today (**Table**).<sup>(1,3-7)</sup> Moreover, spontaneous perforation of bladder for puerperal patients due to the extreme bladder distension was also reported.<sup>(8)</sup>

## CONCLUSION

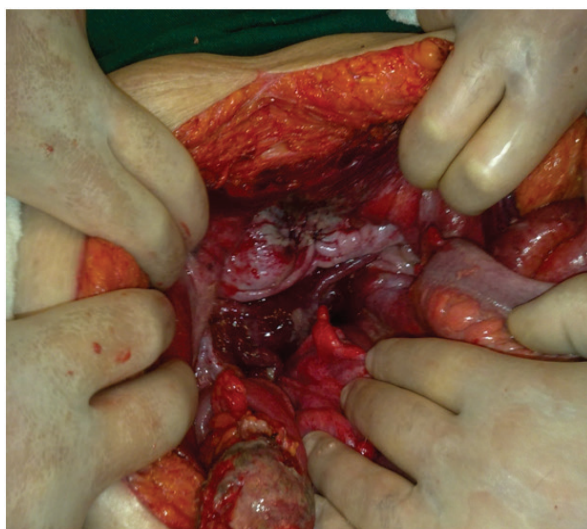
In conclusion, idiopathic, spontaneous bladder perforation is a very rare and life threatening clinical condition that is difficult to recognize preoperatively. The possibility of it should be kept in mind among other acute abdomen reasons.

## CONFLICT OF INTEREST

None declared.

## REFERENCES

1. Wieloch M, Bazylńska K, Ziemiak P. Spontaneous, idiopathic urinary bladder perforation--case report. *Pol Przegl Chir.* 2013;85:727-9.



**Figure.** A perforated about 1 cm was discovered at the dome of the urinary bladder

2. Iverson AJ, Morey AF. Radiographic evaluation of suspected bladder rupture following blunt trauma: critical review. *World J Surg.* 2001;25:1588-91.
3. Albino G, Bilardi F, Gattulli D, Maggi P, Corvasce A, Marucco EC. Spontaneous rupture of urinary bladder: a case report and review. *Arch Ital Urol Androl.* 2012;84:224-6.
4. Cusano A, Abarzua-Cabezas F, Meraney A. Spontaneous bladder perforation unrelated to trauma or surgery. *BMJ Case Rep.* 2014;12:2014.
5. Ahmed J, Mallick IH, Ahmad SM. Rupture of urinary bladder: a case report and review of literature. *Cases J.* 2009;2:7004.
6. Limon O, Unluer EE, Unay FC, Oyar O, Sener A. An unusual cause of death: spontaneous urinary bladder perforation. *Am J Emerg Med.* 2012;30:2081.e3-5.
7. Al-Qassim Z, Mohammed A, England R, Khan Z. Idiopathic spontaneous rupture of the urinary bladder (SRUB). A case report and review of literature. *Cent European J Urol.* 2012;65:235-7.
8. Sailo SL, Sailo L. Spontaneous puerperal bladder perforation presenting with urinary retention. *Urol J.* 2014 6;11:1854.