

Obstructive Azoospermia Secondary to Obstructed Ejaculatory Ducts Treated with Resection of the Verumontanum

Michael S Floyd (Jr),^{1*} Sylvia Connolly,² Hosea Baba Yisa Gana¹

A 25-year old male presented with primary infertility. He and his partner had been trying to conceive for over 12 months despite normal gynecological investigations. There was no history of chronic respiratory disease, infections, sexual dysfunction, genetic abnormalities, trauma or illicit substance use. Secondary sexual characteristics were normal. Physical examination including digital rectal examination was unremarkable. Scrotal ultrasound demonstrated a grade 0 varicocele. Karyotype and hormonal profile were normal. Semen analysis was consistent with obstructive azoospermia, with absent sperm, low pH and reduced volume. Magnetic resonance imaging of his pelvis revealed an 8 mm midline cyst and dilated seminal vesicles (**Figures 1A and 1B**). Subsequent cystoscopy demonstrated an edematous verumontanum which, when resected, immediately released retained semen (**Figures 2A and 2B**). A clinical diagnosis of obstructed ejaculatory ducts was suspected. Ejaculatory duct obstruction causes disruption of spermatozoa transport from the vas deferens to the prostatic urethra via the ejaculatory ducts. Clinical findings such as azoospermia, low volume acidic ejaculate with normal sexual development and dilated seminal vesicles with a midline cyst are highly suggestive.⁽¹⁾ Transurethral resection of the ejaculatory ducts (TURED) and verumontanum has been shown to increase semen volume in patients and successful pregnancies have been reported.^(2,3)

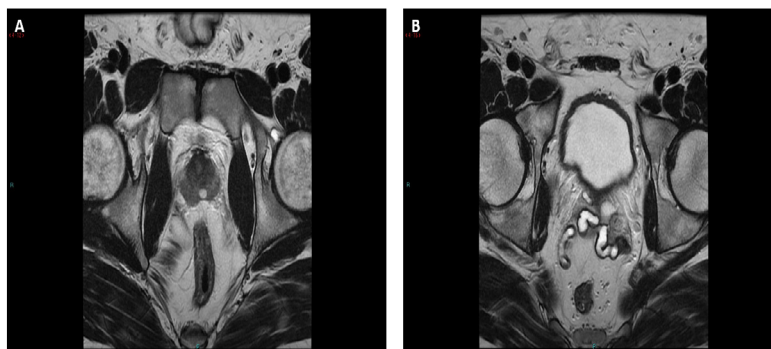


Figure 1. Magnetic resonance imaging of pelvis demonstrates an 8 mm midline cyst (**A**) and dilated seminal vesicles (**B**).

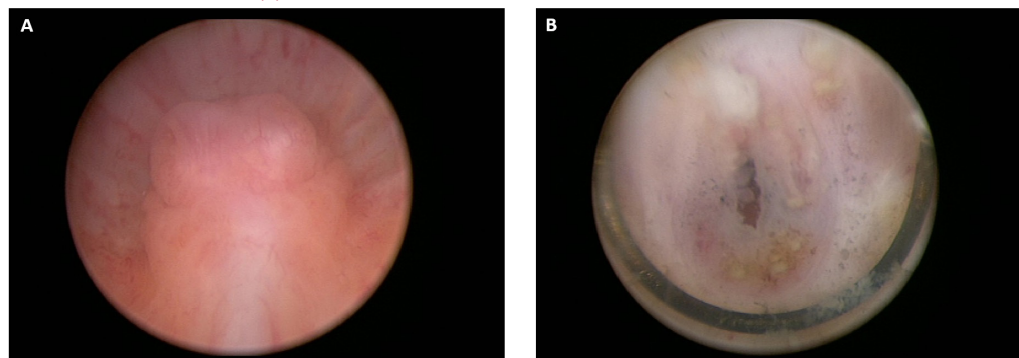


Figure 2. Cystoscopy demonstrates an edematous verumontanum (**A**) which, when resected, immediately released retained semen (**B**).

REFERENCES

1. Paick JS. Transurethral resection of the ejaculatory duct. *Int J Urol.* 2000;7 Suppl:S42-7.
2. Fisch H, Lambert SM, Goluboff ET. Management of ejaculatory duct obstruction: etiology, diagnosis, and treatment. *World J Urol.* 2006;24:604-10.
3. Fuse H, Mizuno I, Iwasaki M, Akashi T. Transurethral treatment of ejaculatory duct obstruction in infertile men. *Arch Androl.* 2003;49:429-31.

Departments of Urology¹ and Radiology,² Whiston Hospital, St Helen's and Knowsley Hospital NHS Trust, Merseyside L35 5DR, UK.

*Correspondence: Department of Urology, Whiston Hospital, St Helen's and Knowsley Hospital NHS Trust, Merseyside, L35 5DR, UK.

Tel: 00 44 1514261600. Fax: 00 44 151 4301405. E-mail: nilbury@gmail.com.

Received December 2014 & Accepted March 2015

Pictorial | 2204