

Successful Perineal Urethroplasty for Long Pelvic Fracture Urethral Distraction Defect (PFUDD) in a 9 Year-Old Boy

Zhai Jianpo,* Wang Jianwei, Li Guizhong, Wang Hai, He Feng, Huang Guanglin, Man Libo

Keywords: fractures; bone; complications; pelvic bones; urethra; injuries; surgery; treatment outcome.

INTRODUCTION

Posterior urethral stricture or pelvic fracture urethral distraction defect (PFUDD) is relatively uncommon in children. Trauma and iatrogenic injury are the most common causes of stricture occurrence.⁽¹⁾ Given the specificity of children's urethra, treating their posterior urethral stricture is difficult, specifically for the children with long segment urethral stricture. We report a successful perineal urethroplasty for 6 cm long PFUDD in a 9 year-old boy.

CASE REPORT

A 9 year-old boy with a long PFUDD was admitted to our hospital in April 2013. Five months before the admission, the boy suffered pelvic fracture and posterior urethral disruption caused by a traffic accident. Given the severity of the combined injuries, he underwent suprapubic cystostomy for acute phase management. Five months later, we performed urethrogram and cystoscopy and found that the urethral distraction defect was 6 cm in length (**Figure 1**). Perineal urethroplasty was thereby performed. In the operation, the boy was placed in the lithotomy position. The bulbospongiosus muscle was dissected through an inverted Y-shaped incision. Afterwards, the bulbar urethra was circumferentially dissected down to its proximal end and sharply divided at the strictured segment. To increase the perineal space, the midline intercrural incision was made and the lower part of pubic symphysis was removed with a power drill. The scar tissue involving the membranoprostic region was excised using retrograde piecemeal method until healthy, soft and pliable mucosa of proximal urethra was identified. This step was assisted by antegrade passage of a bougie through the suprapubic tract. In the last procedure, we placed a 10 French Foley catheter through the urethra into the bladder and performed the end-to-end anastomosis. The operation lasted for five

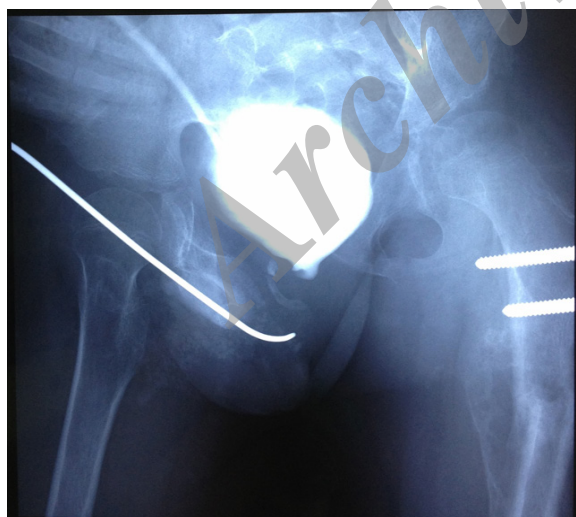

Figure 1. Preoperative combined cystography and retrograde urethrography.

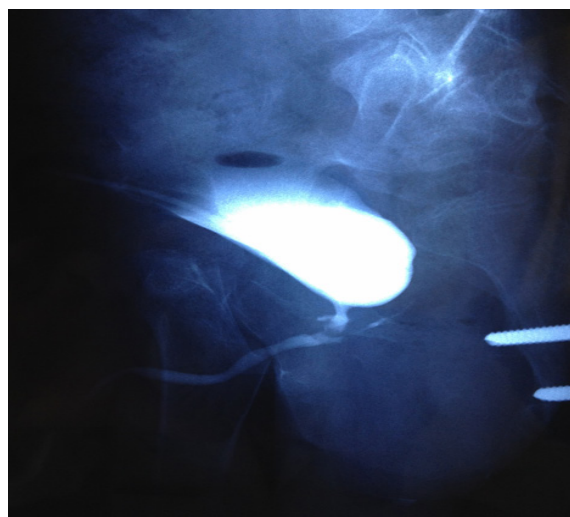


Figure 2. Postoperative cystourethrography.

Department of Urology, Beijing Jishuitan Hospital, Beijing 100035, China.

*Correspondence: Department of Urology, Beijing Jishuitan Hospital, Beijing 100035, China.

Tel: +86 010 58398241. E-mail: dczhaijp@126.com.

Received May 2015 & Accepted November 2015

hours, and the blood loss was less than 200 mL. One month after the operation, the Foley catheter was removed, wherein no post-operative complications were found. The boy recovered well without penile curvature or penile shortening. Urinary incontinence and urethral diverticula were not observed. Currently, the boy has normal urination functions and does not need urethral dilatation (**Figure 2**).

DISCUSSION

Posterior urethral stricture in children is common and the causes include pelvic fracture, straddle injuries, or crush injuries. Sunay and colleagues⁽²⁾ reported that the most frequent cause of urethral stricture is urethral injury (78.6%), which results from pelvic fracture caused by a traffic accident. In the study by Pfalzgraf and colleagues,⁽³⁾ 47.1% of the children have post-traumatic strictures. The urethral distraction defect in the present case report was also caused by pelvic fracture.

Urethral strictures in children, whether caused by trauma or surgery, are difficult to treat due to smaller pelvic confines, decreased caliber urethra, and increased tissue fragility. Posterior urethral trauma imposes severe impairment on the quality of life and is considered one of the most debilitating injuries if not managed properly. It can cause urinary incontinence and impotence, as well as urethral stricture which may require repeated interventions.⁽⁴⁾

Several treatments options, including urethral dilatation, endoscopic visual internal urethrotomy, and open urethral reconstruction, are available for the management of urethral strictures in children. Urethral dilatation is one of the commonly applied procedures in the initial management of urethral strictures. However, the long-term outcome of this procedure is unsatisfactory. Anastomotic urethroplasty is another option for the treatment of urethral strictures. Podesta and Podesta⁽⁵⁾ reviewed records of 49 male children with PFUDDs who underwent anastomotic urethroplasties from 1980 to 2006. The median follow-up time was 6.5 years and they found that the primary success rate was 89.7%. Similarly, Shenfeld and colleagues⁽⁶⁾ evaluated the safety and efficacy of urethroplasty, which applies the perineal approach for bulbar and membranous urethral strictures in children and adolescents. The study showed that the primary success rate of the surgery was 93%. The mean maximal urinary flow rate increased from 2.65 mL/s preoperatively to 27.65 mL/s postoperatively, and no significant complications occurred. The researchers suggested that in pediatric patients, bulbar and membranous strictures can be treated successfully

with urethroplasty using the perineal approach. These patients probably shouldn't be treated "conservatively" with urethral dilatation or endoscopic incision. In addition, the long-term treatment effect of perineal urethroplasty was also confirmed by Orabi and colleagues.⁽⁷⁾ Therefore, perineal urethroplasty is a safe and effective treatment for urethral strictures in children.

The maximum length of stricture that can be treated by end-to-end anastomosis is inconclusive. Koraitim⁽⁸⁾ found that a satisfactory perineal anastomosis could be achieved if the stricture segment was up to 3 cm in length. Moreover, Morey and colleagues demonstrated that they could successfully bridge a urethral gap of up to 5 cm in length after fully mobilizing the urethra.⁽⁹⁾ Regardless of the length of stricture segment, the key to a high success rate in urethral stricture repair is the excision of all of the fibrous tissues along with the complete mobilization of the proximal and distal urethra so as to achieve a tension-free anastomosis. Partial symphysiectomy is sometimes needed to achieve this goal.⁽¹⁰⁾ Given that the length of urethral stricture is 6 cm in this case report, partial symphysiectomy (the lower part) was performed to insure tension-free anastomosis.

CONCLUSIONS

In conclusion, perineal urethroplasty is an excellent surgical procedure for treating children with long segment PFUDD. Partial symphysiectomy is sometimes needed to achieve the tension-free anastomosis.

CONFLICT OF INTEREST

None declared.

REFERENCES

1. Lumen N, Hoebeke P, Willemsen P, De Troyer B, Pieters R, Oosterlinck W. Etiology of urethral stricture disease in the 21st century. *J Urol*. 2009;182:983-7.
2. Sunay M, Karabulut A, Dadalı M, Bağbancı S, Emir L, Erol D. Single-institution Outcomes of Open Reconstruction Techniques for Management of Pediatric and Adolescent Post-traumatic Urethral Strictures. *Urology*. 2011;77:706-10.
3. Pfalzgraf D, Isbarn H, Meyer-Moldenhauer WH, Fisch M, Riechardt S. Etiology and outcome of the perineal repair of posterior and bulbar urethral strictures in children: A single surgeon experience. *J Pediatr Urol*. 2013;9:769-4.
4. Singh A, Panda SS, Bajpai M, Jana M, Baidya DK. Our experience, technique and long-term outcomes in the management of posterior urethral strictures. *J Pediatr Urol*. 2014;10:40-4.

5. Podesta M, Podesta M Jr. Delayed surgical repair of posttraumatic posterior urethral distraction defects in children and adolescents: long-term results. *J Pediatr Urol.* 2015;11:67.e1-6.
6. Shenfeld OZ, Gdor J, Katz R, Gofrit ON, Pode D, Landau EH. Urethroplasty, by perineal approach, for bulbar and membranous urethral strictures in children and adolescents. *Urology.* 2008;71:430-3.
7. Orabi S, Badawy H, Saad A, Youssef M, Hanno A. Post-traumatic posterior urethral stricture in children: how to achieve a successful repair. *J Pediatr Urol.* 2008;4:290-4.
8. Koraitim MM. Gapometry and anterior urethrometry in the repair of posterior urethral defects. *J Urol.* 2008;179:1879-81.
9. Morey AF, Kizer WS. Proximal bulbar urethroplasty via extended anastomotic approach. What are the limits? *J Urol.* 2006;175:2145-9.
10. Ranjan P, Ansari MS, Singh M, Chipde SS, Singh R, Kapoor R. Post-traumatic urethral strictures in children: what have we learned over the years? *J Pediatr Urol.* 2012;8:234-9.