

X-Ray Free Minimally Invasive Surgery for Urolithiasis in Pregnancy

Abbas Basiri,¹ Akbar Nouralizadeh,^{1*} Amir H Kashi,^{1,2} Mohammad Hadi Radfar,¹ Mahmoodreza Nasiri,¹ Mahdi Zeinali,¹ Reza Sarhangnejad,¹ Seyed-Hossein Hosseini-Sharifi¹

Purpose: Our goal was to present our experience with ultrasound guided supine or prone percutaneous nephrolithotomy in three pregnant women under spinal anesthesia.

Materials and Methods: Three pregnant women in the 16th, 20th and 28th weeks of pregnancy presented with symptomatic large renal stone in the first patient and multiple renal stones in the second and third patients which were unresponsive to conventional medical therapy. They requested a definitive stone treatment. The operations were done in November 2012, June 2014 and February 2015. Data was gathered prospectively. All steps of gaining access to the pyelocalyceal system including needle insertion, tract dilation, and Amplatz sheath placement were performed under ultrasonography guidance. Tract was dilated with a single shot technique. The first two procedures were performed in supine position and the third procedure was performed in lateral flank position.

Results: Two patients were stone-free postoperatively and one patient had only an asymptomatic 4 mm residual stone. They were discharged on the 2nd postoperative day and had an uneventful postoperative course. No fever, bleeding or renal colic was noticed during postoperative hospitalization. All patients delivered their fetuses at term without any abnormality reported by the examining pediatric specialist after their birth.

Conclusion: Ultrasonography can be used as an imaging modality guiding all steps of obtaining percutaneous access in pregnant women. Supine or flank ultrasound guided percutaneous nephrolithotomy can be offered to pregnant women in whom conservative measures fail to the patients' wellbeing.

Keywords: percutaneous nephrolithotomy, ultrasonography, pregnancy, supine, flank.

INTRODUCTION

Since the first percutaneous nephrolithotomy (PCNL) which was performed in 1976, PCNL technique has evolved substantially.⁽¹⁾ Traditionally, PCNL was performed under general anesthesia and fluoroscopy guidance in prone position. In recent years, various positions and imaging techniques with high success rates have been applied in PCNL. PCNL has been performed in supine, flank, and prone-flexed positions using X-ray, ultrasonography (US), computed tomography (CT) scan, or blind access techniques.⁽²⁻⁷⁾

In pregnancy, 70-80% of symptomatic calculi pass spontaneously with conservative management leaving no sequelae. However; fever, infection, uncontrolled pain and progressive hydronephrosis, occurring in 30% of the patients, are indications for surgical intervention.⁽⁸⁾ The current recommended interventions for symptomatic pregnant women with renal calculi are placement of nephrostomy or ureteral catheter. However in some

patients, it becomes necessary to implement a definitive intervention or the patients ask for a definitive intervention. The concerns about percutaneous management of renal stones in a pregnant woman are anesthesia, prone positioning, and delivery of hazardous X-ray. We previously reported the use of totally US-guided PCNL in supine and flank positions^(9, 10) and the use of spinal anesthesia for PCNL.⁽¹¹⁾ We used this method in three pregnant women who presented to our center. To our knowledge, there is limited prior experience in this field.^(12,13)

Patient 1

A 26-year-old pregnant woman presented with severe left flank pain, nausea, and vomiting in the 16th weeks of pregnancy. The patient had history of previous stone passage. US revealed a 2.4 cm stone in the pelvis of the left kidney with mild to moderate hydronephrosis. Analgesic and serum therapy were given to the patient. Urine culture was positive and the patient was given

¹ Urology and Nephrology Research Center, Shahid Labbafinejad Medical Center, Shahid Beheshti University of Medical Sciences, Tehran, Iran.

² Hasheminejad Kidney Center, Tehran, Iran.

*Correspondence: Urology and Nephrology Research Center, Shahid Labbafinejad Medical Center, 9th Boostan Street, Pasdaran Avenue, Tehran, Iran.

Tel: +98 21 22588016. E-mail: Nouralizadeh@yahoo.com.

Received October 2015 & Received December 2015

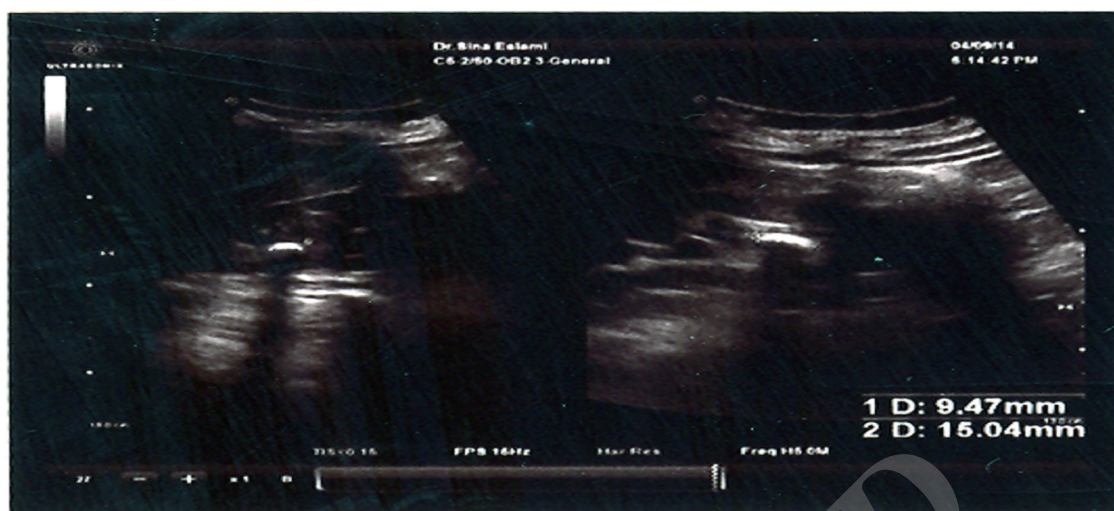


Figure 1. Ultrasonography demonstrates kidney stones in the second patient.

antibiotics for 7 days and a repeat urine culture was negative. Conservative measures were continued for 3 weeks but she still experienced severe pain. Nephrostomy or double-J (DJ) stent insertion was suggested to the patient, but she refused and requested for a definitive stone treatment. After consultation with her obstetrician

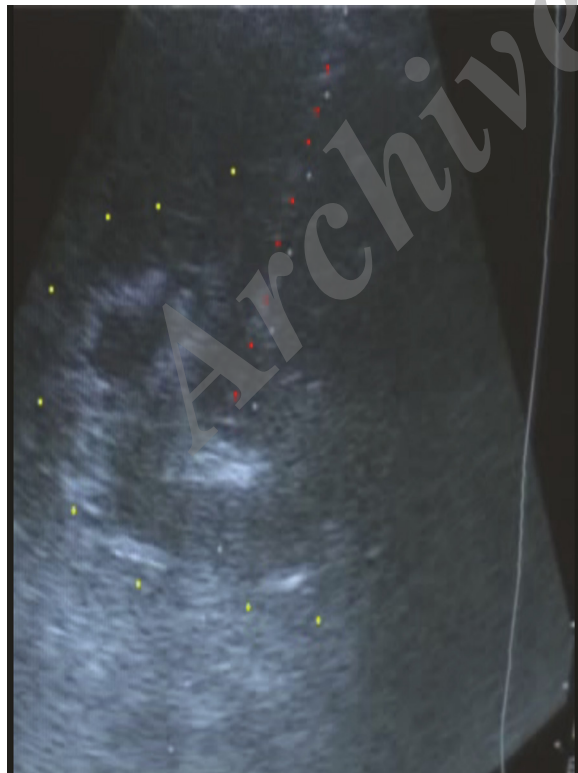

Figure 2. Applying needle-holder under Ultrasonography guidance to enter the proper calyx. The red line indicates the needle path denoted by its echogenicity.

and anesthesiologist, we suggested performing supine US-guided PCNL.

Potential risks of the procedure were explained to the patient and her family, and informed consent was obtained. The patient was operated on the 10th of November 2012. After spinal anesthesia, the patient was placed in supine position. Cystoscopy was performed and a 5 French (F) ureteral catheter was inserted. Access to the lower calyx was obtained under US guidance. All steps of tract dilation and 28 F Amplatz sheath insertion were controlled with US avoiding X-ray exposure. Nephroscopy was performed, and the stone was fragmented using pneumatic LithoClast and removed from the kidney. Residual stones were checked with US. Ureteral catheter was then removed and DJ ureteral stent inserted anterogradely. No nephrostomy tube was inserted at the end of procedure. Operation duration was 45 minutes. The patient was stone free on the first postoperative day US, and was discharged on the second postoperative day. No fever, gross bleeding or renal colic was noticed during postoperative hospitalization. DJ was removed after 4 weeks. The patient was followed until delivery and the after birth neonatal examination by the pediatric specialist revealed no abnormality.

Patient 2

A 25-year-old female was referred by a urologist suffering from intractable renal colic in the 20th week of pregnancy. She had history of kidney stones. Conservative management strategies (nephrostomy or DJ) had been offered to the patient but she had requested for a definitive modality and hence referred to the office of one

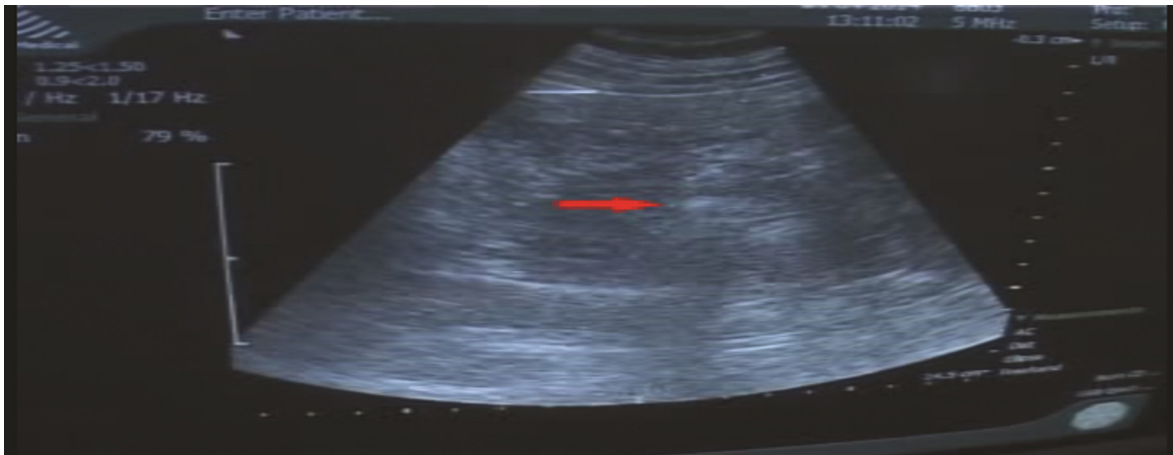


Figure 3. Ultrasonography from the anterior abdominal wall guided the tract dilation step. The red arrow indicates the tip of Amplatz sheath in the renal collecting system.

of the authors (A.B). US revealed 4 stones on the right side (15 mm, 9 mm, 4 and 3 mm) with mild-moderate hydronephrosis (**Figure 1**). MRI was requested which confirmed mild to moderate hydronephrosis of the right kidney. The patient was consulted about the potential risks of supine US-guided PCNL and informed consent was obtained. She was operated on the 4th of June 2014. The operation was performed in supine position. Ureteral catheter was fixed by cystoscopy. The middle calyx was punctured under US guidance (**Figure 2**) and guide wire inserted. Then the tract was dilated under US guidance (**Figure 3**) up to 30 F and drainage of urine

from the tip of dilation instruments was confirmed at each step. Nephroscopy was performed and the large stone was extracted by forceps and smaller stones were removed by irrigation and/or forceps. Operation duration was 51 minutes. Nephrostomy was fixed at the end of operation which was removed on the second postoperative day. Ureteral catheter was removed on the first postoperative day. The patient did not experience fever or renal colic after the operation. She only experienced minor abdominal cramps after the operation for one day duration around her umbilicus. We requested a gynecologic consultation which reported no obstetric complication and the patient was given analgesics. The patient was uneventful at follow-up and a follow-up US one week after the operation only revealed an asymptomatic 4 mm stone in the right kidney. The patient was followed until delivery and the examination of her baby was normal after birth.

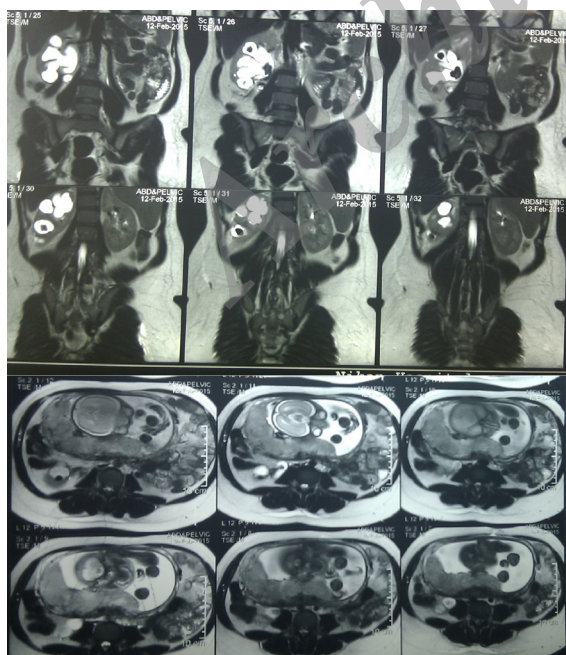


Figure 4. Magnetic resonance imaging revealed stones in the right kidney and distal ureter (red arrow).

Patient 3

A 34-year-old pregnant woman presented with severe left flank pain, nausea, and vomiting in the 28th week of pregnancy. The patient had no history of previous stone passage. US revealed one 20 mm stone in the pelvis, one 12 mm stone in the upper pole, and one 10 mm stone in the lower pole of the right kidney with severe hydronephrosis and three 10 mm stones in distal ureter. Analgesic and serum therapy were given to the patient. Nephrostomy was placed for the patient under US guidance. The patient suffered from sustained flank discomfort despite insertion of percutaneous nephrostomy and requested for definitive stone treatment. MRI was requested which confirmed severe hydroureteronephrosis of the right kidney (**Figure 4**). After consultation with her obstetrician and anesthesiologist, we suggested per-

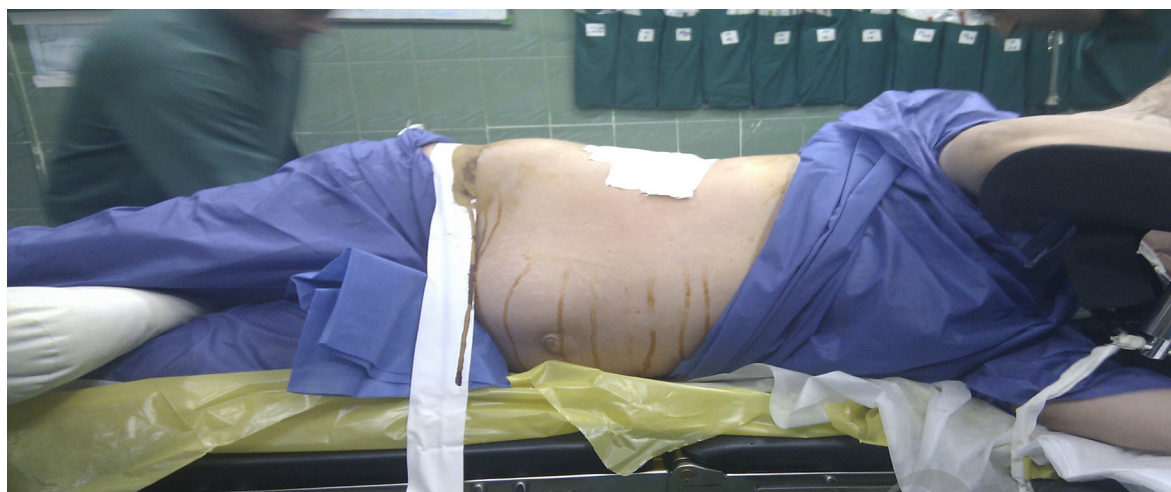

Figure 5. Lateral flank position of the patient (image taken after the operation).

forming flank US-guided PCNL.

Potential risks of the procedure were explained to the patient and her family, and informed consent was obtained. The patient was operated on the 19th of February 2015. After spinal anesthesia, the patient was placed in supine position. Ureteroscopy was performed and ureteral stones were fragmented using pneumatic LithoClast and removed from ureter and a 5 F ureteral catheter was inserted. Then the patient was placed in right flank position (**Figure 5**). Access to the lower calyx was obtained under US guidance. All steps of tract dilation and 30 F Amplatz sheath insertion were controlled with US avoiding X-ray exposure. Nephroscopy was performed, and the stones were fragmented using pneumatic LithoClast and removed from the kidney. Residual stone presence was checked with US. Ureteral catheter was removed and a DJ stent inserted antegrade. Nephrostomy was fixed at the end of operation which was removed on the second postoperative day. Operation duration was 65 minutes. The patient was stone free on the first postoperative US, and was discharged on the second postoperative day. No fever, gross bleeding or renal colic was noticed during postoperative hospitalization. DJ was removed after 4 weeks. The patient was followed until delivery and the examination of her baby was normal after birth.

DISCUSSION

The actual incidence of urinary stones in pregnancy is similar to non-pregnant women.^(8,14) Because of limitations and special concerns raised by pregnancy, urolithiasis is a particular diagnostic and therapeutic challenge in pregnancy.⁽¹⁵⁾ Approximately 70-80% of stones presented during pregnancy will pass spontaneously; therefore a trial of conservative management should be

given to most of the patients, if possible.⁽¹⁶⁾ Urinary diversion via DJ stent or percutaneous nephrostomy tube should be applied when the patient has refractory pain, urinary tract infection, or an obstructed single kidney.^(17,18) These interventions are unpleasant to some patients due to the requirement for their periodic exchange (6-8 weeks).⁽¹⁹⁾ Besides, carrying a nephrostomy tube is uncomfortable for many patients and many are bothered by the irritative lower urinary symptoms associated with DJ stents.⁽¹⁹⁾ Furthermore, encrustation of the DJ stent is another concern which in some cases necessitated a PCNL operation to remove the proximal encrusted end of the catheter.⁽²⁰⁾

Percutaneous nephrolithotomy is not generally advocated during pregnancy because of considerations regarding the length of anesthesia, need for fluoroscopy, and prone positioning.⁽⁸⁾ Nevertheless many publications in recent years reported the feasibility and safety of totally US-guided PCNL in supine, prone and flank positions,^(10,21-25) Basiri and colleagues reported their experience with X-ray free supine PCNL in 19 patients.⁽⁹⁾ Others have used various US types (Doppler, B-mode) and positions (supine, flank, prone).^(26,27) Agarwall and colleagues used ultrasonography as a guide for the puncture step, and fluoroscopy for the rest of surgery. They concluded that US-guided puncture helps decrease radiation exposure and increase puncture accuracy.⁽¹²⁾ Furthermore, advances in anesthesia has made it less problematic for pregnant women and there is an increasing trend for the use of definitive interventions requiring regional anesthesia (e.g. ureteroscopy) in pregnancy⁽²⁸⁻³⁰⁾ so that ureteroscopy is now offered as an alternative treatment strategy together with nephrostomy or ureteral stent for ureteral stones in pregnancy in European Association of Urology (EAU) and American

Urological Association (AUA) guidelines.^(31,32) There have been reports on the feasibility and safety of PCNL under regional anesthesia including our previous publications.^(11,33,34)

Shah and colleagues described their experience in a 33-year-old pregnant woman presented with right-sided pyonephrosis due to a 1.8 cm renal calculus obstructing the ureteropelvic junction. PCNL was carried out at 14 weeks of gestation with 6 seconds of radiation exposure confined to the right kidney.⁽³⁵⁾ Toth and colleagues published a report on a 31-year-old, 11 weeks pregnant woman with an 8 mm stone who underwent successful PCNL in prone position under spinal anesthesia and US guidance.⁽³⁶⁾ Feregonesi and colleagues reported a 24-year-old woman with symptomatic 2.7 cm right renal stone in the 22nd weeks of pregnancy who was successfully treated by supine US-guided PCNL.⁽¹³⁾ Our experience also supports the feasibility of supine US-guided PCNL for definitive treatment of renal stones in patients who are candidates for a definitive intervention. In this study we did not encounter any obstetric problem during operation or after operation until delivery. The nephrostomy and ureteral catheter which were inserted for the second patient were removed on postoperative days 1 and 2 and caused only a short time discomfort for the patient. DJ was inserted for the 1st and 3rd patients as they were the first experiences of the attending surgeons (A.B and A.N respectively) as we preferred to be conservative and have a medium term drainage catheter in case of any unpredicted problem. All patients were followed up until after delivery. No abnormality was reported in their after birth neonatal examination carried out by the pediatric specialists; however this study included a limited number of patients.

We think that the following tips will help to perform a safe PCNL in pregnancy. Applying needle-holder under US guidance results in higher accuracy in entry to the selected target calyx (**Figure 2**). US also allows for checking the depth of dilator insertion precisely. We dilated the tract with a single shot technique, while US from the anterior abdominal wall guided the procedure (**Figure 3**).

CONCLUSIONS

In conclusion, we suggest that PCNL can be more freely offered to pregnant women with renal stone who are unwilling to undergo several sessions of nephrostomy or DJ stent exchange and prefer to receive definitive treatment especially if conservative measures fail to the patients' wellbeing.

ACKNOWLEDGEMENTS

The authors would like to thank Iran's National Elites Foundation for their help and support.

CONFLICT OF INTEREST

None declared.

REFERENCES

1. Fernstrom I, Johansson B. Percutaneous pyelolithotomy. A new extraction technique. *Scand J Urol Nephrol.* 1976;10:257-9.
2. Basiri A, Mehrabi S, Kianian H, Javaherforooshzadeh A. Blind puncture in comparison with fluoroscopic guidance in percutaneous nephrolithotomy: a randomized controlled trial. *Urol J.* 2007;4:79-83.
3. Gamal WM, Hussein M, Aldahshoury M, et al. Solo ultrasonography-guided percutaneous nephrolithotomy for single stone pelvis. *J Endourol.* 2011;25:593-6.
4. Roy OP, Angle JF, Jenkins AD, Schenkman NS. Cone beam computed tomography for percutaneous nephrolithotomy: initial evaluation of a new technology. *J Endourol.* 2012;26:814-8.
5. Honey RJ, Wiesenthal JD, Ghiculete D, Pace S, Ray AA, Pace KT. Comparison of supracostal versus infracostal percutaneous nephrolithotomy using the novel prone-flexed patient position. *J Endourol.* 2011;25:947-54.
6. Jang WS, Choi KH, Yang SC, Han WK. The Learning Curve for Flank Percutaneous Nephrolithotomy for Kidney Calculi: A Single Surgeon's Experience. *Korean J Urol.* 2011;52:284-8.
7. Mazzucchi E, Vicentini FC, Marchini GS, Danilovic A, Brito AH, Srougi M. Percutaneous nephrolithotomy in obese patients: comparison between the prone and total supine position. *J Endourol.* 2012;26:1437-42.
8. Swanson SK, Heilman RL, Eversman WG. Urinary tract stones in pregnancy. *Surg Clin North Am.* 1995;75:123-42.
9. Basiri A, Mohammadi Sichani M, Hosseini SR, et al. X-ray-free percutaneous nephrolithotomy in supine position with ultrasound guidance. *World J Urol.* 2010;28:239-44.
10. Basiri A, Ziaee SA, Nasseh H, et al. Totally ultrasonography-guided percutaneous nephrolithotomy in the flank position. *J Endourol.* 2008;22:1453-7.
11. Nouralizadeh A, Ziaee SA, Hosseini Sharifi SH, et al. Comparison of percutaneous nephrolithotomy under spinal versus general anesthesia: a randomized clinical trial. *J Endourol.* 2013;27:974-8.
12. Agarwal M, Agrawal MS, Jaiswal A, Kumar D, Yadav H, Lavania P. Safety and efficacy of ultrasonography as an adjunct to

- fluoroscopy for renal access in percutaneous nephrolithotomy (PCNL). *BJU Int.* 2011;108:1346-9.
13. Fregonesi A, Dias FG, Saade RD, Dechaalani V, Reis LO. Challenges on percutaneous nephrolithotomy in pregnancy: Supine position approach through ultrasound guidance. *Urol Ann.* 2013;5:197-9.
 14. Drago JR, Rohner TJ, Jr., Chez RA. Management of urinary calculi in pregnancy. *Urology.* 1982;20:578-81.
 15. McAleer SJ, Loughlin KR. Nephrolithiasis and pregnancy. *Curr Opin Urol.* 2004;14:123-7.
 16. Loughlin KR, Ker LA. The current management of urolithiasis during pregnancy. *Urol Clin North Am.* 2002;29:701-4.
 17. Jarrard DJ, Gerber GS, Lyon ES. Management of acute ureteral obstruction in pregnancy utilizing ultrasound-guided placement of ureteral stents. *Urology.* 1993;42:263-7.
 18. Kavoussi LR, Albala DM, Basler JW, Apte S, Clayman RV. Percutaneous management of urolithiasis during pregnancy. *J Urol.* 1992;148:1069-71.
 19. Osman M, Wendt-Nordahl G, Heger K, Michel MS, Alken P, Knoll T. Percutaneous nephrolithotomy with ultrasonography-guided renal access: experience from over 300 cases. *BJU Int.* 2005;96:875-8.
 20. Pais VM, Jr., Chew B, Shaw O, et al. Percutaneous nephrolithotomy for removal of encrusted ureteral stents: a multicenter study. *J Endourol.* 2014;28:1188-91.
 21. Alan C, Kocoglu H, Ates F, Ersay AR. Ultrasound-guided X-ray free percutaneous nephrolithotomy for treatment of simple stones in the flank position. *Urol Res.* 2011;39:205-12.
 22. Desai M. Ultrasonography-guided punctures-with and without puncture guide. *J Endourol.* 2009;23:1641-3.
 23. Falahatkar S, Neiroomand H, Enshaei A, Kazemzadeh M, Allahkhah A, Jalili MF. Totally ultrasound versus fluoroscopically guided complete supine percutaneous nephrolithotripsy: a first report. *J Endourol.* 2010;24:1421-6.
 24. Fu YM, Chen QY, Zhao ZS, et al. Ultrasound-guided minimally invasive percutaneous nephrolithotomy in flank position for management of complex renal calculi. *Urology.* 2011;77:40-4.
 25. Karami H, Rezaei A, Mohammadhosseini M, Javanmard B, Mazloomfard M, Lotfi B. Ultrasonography-guided percutaneous nephrolithotomy in the flank position versus fluoroscopy-guided percutaneous nephrolithotomy in the prone position: a comparative study. *J Endourol.* 2010;24:1357-61.
 26. Lu MH, Pu XY, Gao X, Zhou XF, Qiu JG, Si-Tu J. A comparative study of clinical value of single B-mode ultrasound guidance and B-mode combined with color Doppler ultrasound guidance in mini-invasive percutaneous nephrolithotomy to decrease hemorrhagic complications. *Urology.* 2010;76:815-20.
 27. Tzeng BC, Wang CJ, Huang SW, Chang CH. Doppler ultrasound-guided percutaneous nephrolithotomy: a prospective randomized study. *Urology.* 2011;78:535-9.
 28. Lifshitz DA, Lingeman JE. Ureterscopy as a first-line intervention for ureteral calculi in pregnancy. *J Endourol.* 2002;16:19-22.
 29. Ulvik NM, Bakke A, Hoisaeter PA. Ureterscopy in pregnancy. *J Urol.* 1995;154:1660-3.
 30. Watterson JD, Girvan AR, Beiko DT, et al. Ureterscopy and holmium:YAG laser lithotripsy: an emerging definitive management strategy for symptomatic ureteral calculi in pregnancy. *Urology.* 2002;60:383-7.
 31. EAU/AUA Nephrolithiasis Guideline Panel; Preminger GMT, H.G, Asimos DG, Alken P, Buck AC, Gallucci M. Ureteral Calculi; 2007 Guideline for management of ureteral calculi: European Association of Urology and American Urological Association Research and Education; 2007. Available from: <http://www.auanet.org/education/guidelines/ureteral-calculi.cfm>.
 32. Turk CK, C., Petrick A, Sarica K, Skolarikos A, Straub M. Guidelines on Urolithiasis. In: Members EGO, editor. *European Association of Urology Guidelines; 2014 Edition: European Association of Urology; 2014.* p. 54-5.
 33. Kuzgunbay B, Turunc T, Akin S, Ergenoglu P, Aribogan A, Ozkardes H. Percutaneous nephrolithotomy under general versus combined spinal-epidural anesthesia. *J Endourol.* 2009;23:1835-8.
 34. Singh V, Sinha RJ, Sankhwar SN, Malik A. A prospective randomized study comparing percutaneous nephrolithotomy under combined spinal-epidural anesthesia with percutaneous nephrolithotomy under general anesthesia. *Urol Int.* 2011;87:293-8.
 35. Shah A, Chandak P, Tiptaft R, Glass J, Dasgupta P. Percutaneous nephrolithotomy in early pregnancy. *Int J Clin Pract.* 2004;58:809-10.
 36. Toth C, Toth G, Varga A, Flasko T, Salah MA. Percutaneous nephrolithotomy in early pregnancy. *Int Urol Nephrol.* 2005;37:1-3.