

Giant Vesicoprostatic Calculus Combined with Vesico-Cutaneous Fistula

Georgios Goumas, Konstantinos Stasinopoulos, Charalampos Fragkoulis, Georgios Papadopoulos,* Georgios Stathouros, Konstantinos Ntoumas

Keywords: urinary bladder; calculi; etiology; prostatic diseases; prostate; pathology; male.

INTRODUCTION

Bladder lithiasis is a common condition that accounts for 5% of all urinary calculi.⁽¹⁾ Predisposing factors include bladder outlet obstruction, neurogenic bladder abnormalities, as well as foreign bodies.⁽²⁾ The size of the stones is rarely large and some sporadic case reports of calculi with giant dimensions have been published. In our reference we report a case of an extremely sizable calculus covering the whole vesicoprostatic lumen, from bladder dome to verumontanum accompanied by vesicocutaneous fistula.

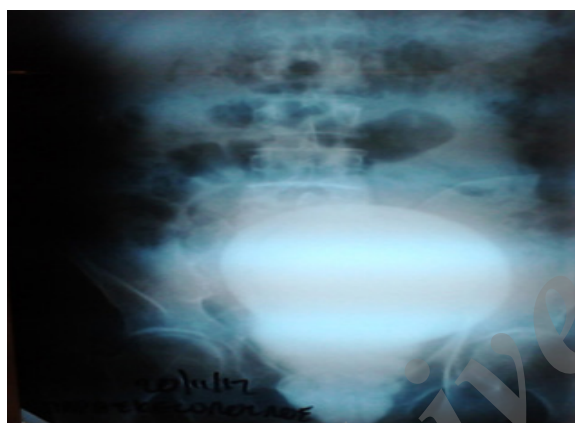


Figure 1. Kidney-Ureter-Bladder X-ray shows sizable vesicoprostatic stone.

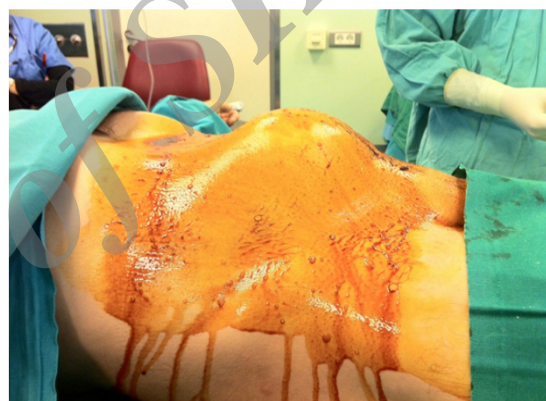


Figure 2. Suprapubic protrusion produced by bladder stone.

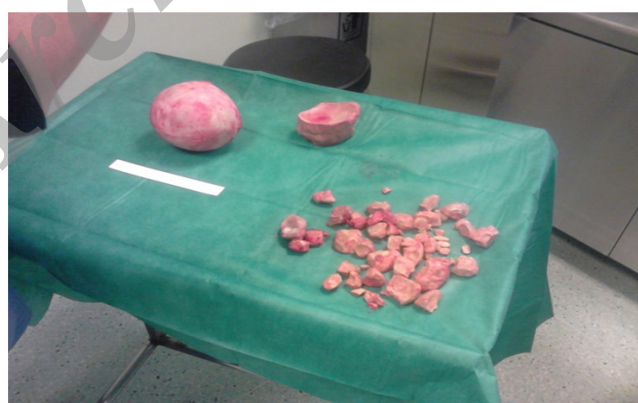

Figure 3. Stone burden after removal.

Department of Urology, Athens General Hospital "G. Gennimatas", Athens, Greece.

*Correspondence: 1B, Kefallinias St., Maroussi, Athens, PC: 15126, Greece.

Tel: +30 694 5540032. Fax: +30 210 6106258. E-mail: gipapadopoulos@yahoo.gr.

Received June 2015 & Accepted February 2016

CASE REPORT

A 56-year-old man was referred to our urological Clinic complaining of lower urinary tract symptoms (LUTS) and vesicocutaneous fistula (in the mid of the distance between umbilicus and pubic symphysis) which he had first detected a few days before. His personal history comprised an abdominal operation because of a severe car accident 3 decades ago. The exact abnormality and operation of that accident was not clear (records were not available) but might have played a role in bladder innervations and emptying, especially if pelvic area had been involved. His medications included amlodipine due to arterial hypertension and tamsulosin for the aforementioned LUTS. However, patient was not on proper follow-up due to a particular mentality and temperament.

Clinical examination revealed the above fistula as well as a characteristic suprapubic protrusion which was quite clear due to patient's low body mass index (**Figure 1**). The area was firm and produced a blunt sound on percussion. Biochemical assays revealed a slightly impaired renal function [serum urea and creatinine were 58 mg/dL (normal values: 20-50 mg/dL) and 1.8 mg/dL (normal values: 0.8-1.4 mg/dL), respectively]. His hematocrit was 32.8% and white blood cells count were marginally elevated (11.800/mm³). Urinalysis showed pyuria and microscopic hematuria. Urine culture confirmed *Escherichia Coli* colonization. Subsequent imaging with plain X-ray and computerized tomography (CT) scan displayed a large calculus occupying the whole bladder and prostatic area (**Figure 2**). Moreover, mild bilateral pelvicalyceal dilatations were observed.

The patient was subsequently admitted to our department. Two days later he underwent an open cysto-prostato-lithotomy and fistula repair (endoscopic cystoscopy was initially performed, to assess urethra's patency, but the scope could not be negotiated further than verumontanum).

Bladder wall was very thin and a large diverticulum on left lateral wall was also fully occupied by stones. Fortunately, the diverticular "neck" was wide, so the stones in it could be removed. Surprisingly, the whole prostatic urethra and prostatic adenoma area were also occupied by calculi that were removed with the usage of index finger, like the technique applied in transvesical prostatectomy. The vesico-cutaneous fistula was easily removed (in fact, this was too short, due to the small distance between bladder wall and skin). The whole stone burden removed weighed 2.4 kg with a maximum diameter of 12 cm (**Figures 3**). Bladder was sutured in

two layers and a 3-way urethral catheter was placed. This was removed on the 8th postoperative day and the patient started restoring his voiding. However, due to the long presence of the above described condition, the patient could not empty his bladder and retained a post-void residual urine volume of constantly over 300 mL. Therefore, he is now (1 year later), on clean intermittent catheterizations. Stone analysis showed magnesium ammonium phosphate.

DISCUSSION

Vesical calculi, though commonly diagnosed, are rarely over 100 gr in weight. In our paper we present one of the heaviest (possibly the heaviest) vesical stones (2.4 Kg). Moreover, the stone occupied the whole prostatic urethra, being imaged as having replaced prostatic adenoma completely (**Figure 2**). In literature there have been published a number of sizable vesical calculi and a smaller one regarding prostatic stones.^(3,4) Our case, not only describes the biggest stone but combines vesical and prostatic anatomical areas, both in the same patient. Most of such stones are of mixed composition. If infection is present, struvite is the major constituent.⁽⁵⁾ Regarding symptoms, there is a variety of manifestations of the problem, namely LUTS, hematuria, obstruction, infection, renal failure and bladder rupture.⁽⁶⁻⁸⁾ In the patient we present, the main sign was vesicocutaneous fistula. This has also been reported.^(9,10) Moreover, it has been claimed that weakening of the anterior abdominal wall and bladder due to previous operations might be a predisposing factor to that, since the strength of the rectus abdominis muscle between the bladder and skin, functions protectively regarding fistula formation in that region.

CONFLICT OF INTEREST

None declared.

REFERENCES

1. Schwartz BF, Stoller MF. The vesical calculus. *Urol Clin North Am.* 2000;27:333-46.
2. Hammad FT, Kaya M, Kazim E. Bladder calculi: did the clinical picture change? *Urology.* 2006;67:1154-8.
3. Farshi A, Sari Motlagh R, Jafari Arismani R. Delivery of huge bladder stone in a thirty-five-year-old man. *Nephrourol Mon.* 2014;6:e20574.
4. Bello A, Maitama HY, Mbibu NH, Kalayi GD, Ahmed A. Unusual Giant Prostatic Urethral Calculus. *J Surg Tech Case Rep.* 2010;2:30-2.
5. Hizli F, Yilmaz E. A giant bladder struvite stone in an adolescent boy. *Urol Res.* 2012;40:273-4.

6. Komeya M, Sahoda T, Sugiura S, Sawada T, Kitami K. A huge bladder calculus causing acute renal failure. *Urolithiasis*. 2013;41:85-7.
7. Thakur RS, Minhas SS, Jhobta R, Sharma D. Giant vesical calculus presenting with azotaemia and anuria. *Indian J Surg*. 2007;69:147-9.
8. Kaur N, Attam A, Gupta A, Amratash. Spontaneous bladder rupture caused by a giant vesical calculus. *Int Urol Nephrol*. 2006;38:487-9.
9. Kobori Y, Shigehara K, Amano T, Takemae K. Vesicocutaneous fistula caused by giant bladder calculus. *Urol Res*. 2007;35:161-3.
10. Motiwala HG, Joshi SP, Visana KN, Baxi H. Giant vesical calculus presenting as vesicocutaneous fistula. *Urol Int*. 1992;48:115-6.

Archive of SID