

Outcomes of Patients with Glanular Hypospadias or Dorsal Hood Deformity with Mild Chordee Treated by Modified Firlit's Technique

Farshid Alizadeh*, Shekoufeh Shirani

Purpose: To assess the success and complication rates of glanular hypospadias or dorsal hood deformity surgery, using a modified Firlit's technique without glanuloplasty.

Materials and Methods: Between May 2013 and December 2015, 41 patients with glanular hypospadias or dorsal hood deformity without hypospadias and mild ventral chordee underwent surgery. Thirty-eight who completed the 1 week and 6-month follow-up were retrospectively evaluated. Exclusion criteria were complete absence of corpus spongiosum resulting in very thin distal urethra, moderate to severe ventral chordee or deep urethral plate that seemed to be better served by tubularization techniques. Modified Firlit's technique (a submeatal inverted V incision in addition to the classic technique) was applied to all patients.

Results: The mean age was 20.4 ± 13 months (range: 6-52 months). The only complication was a narrow-band ventral skin necrosis in 1 patient (2.6%) that was replaced by new skin growth without need for further intervention. No other complications including unresolved chordee, urethrocutaneous fistula, meatal stenosis, hematoma, infection or post-operative bleeding was observed. Defining the satisfactory result as the glanular position of the meatus and the absence of residual chordee, all patients had satisfactory outcome.

Conclusion: Modified Firlit's technique is a simple method with excellent cosmetic results and low complication rate that avoids unnecessary glans dissections. When prepucioplasty is not desired, this technique can be considered as a viable option.

Keywords: children; chordee; hypospadias; Firlit's technique.

INTRODUCTION

Repair of glanular hypospadias, once considered unnecessary, is commonplace nowadays.⁽¹⁾ Although the reason for surgery is usually cosmesis, mild degrees of ventral chordee (VC) is sometimes present that could be surgically treated simultaneously. This fact that the cause of chordee is the abnormal adherence of the skin to the underlying structures and the absence of the normal gliding subcutaneous tissue, was first addressed by Smith and Blackfield in 1952.⁽²⁾ Later, in 1973, Devine and Horton proposed a classification system for various penile curvatures,⁽³⁾ based on the presence or absence of corpus spongiosum, Buck's and/or dartos fascia or corporeal disproportion. Regardless of etiology, chordee correction is an important step in surgical correction of hypospadias or dorsal hood deformity. When corpus spongiosum is normally developed, skin and dartos dissection is usually sufficient for chordee correction. This procedure, however, leaves the penis with some ventral skin defect. On the other hand, the mucosa-like, inner prepuce is absent on the ventral aspect of the hypospadiac phallus. To achieve a normal-appearing circumcised penis, this skin zone (zone II), that is distinct from the spongy, glans epithelium (zone I) and the shaft skin (zone III), and is located between them, should be reconstructed.⁽⁴⁾ In 1987, the "mucosal collar" technique was introduced

by Firlit to transpose the dorsal, mucosal-like, inner prepuce from dorsal to ventral penis. This technique can be combined with any hypospadias repair method and also in patients with chordee without hypospadias.⁽⁴⁾ In this paper, the application of the Firlit's technique, with a minor modification, will be assessed in patients with glanular hypospadias and dorsal hood deformity with mild VC, with special attention to chordee correction, complications and final meatal position.

MATERIALS AND METHODS

After obtaining the IRB approval, the records of patients with glanular hypospadias and dorsal hood deformity without hypospadias who had underwent surgery from May 2013 to December 2015 in our university hospital were evaluated. Inclusion criteria were glanular hypospadias or dorsal hood deformity without hypospadias, with mild ($<30^\circ$) VC. Exclusion criteria were complete absence of corpus spongiosum, resulting in a paper-thin distal urethra, moderate to severe VC or deep urethral plate that seemed to be better served by tubularization techniques. After releasing prepucial adhesions under general and caudal anesthesia, the degree of chordee was evaluated by applying gentle downward pressure at the penile base (**Figure 1-A**). If the degree of chordee was mild, one glanular and 2 prepucial stay sutures were placed and the distal urethra was assessed for the presence or absence of corpus spongiosum by passing a 6 F feeding

Isfahan Kidney Transplantation Research Center. Isfahan University of Medical Sciences. Department of Urology. Al-Zahra Hospital. Isfahan, Iran.

*Correspondence: No. 20, Farhad Alley, Daneshgah Blvd., Isfahan, Iran. Postal code: 81739-74589.

Phone: +989133179509. Fax: +983136263383. Email: f_alizadeh@med.mui.ac.ir.

Received July 2016 & Accepted November 2016

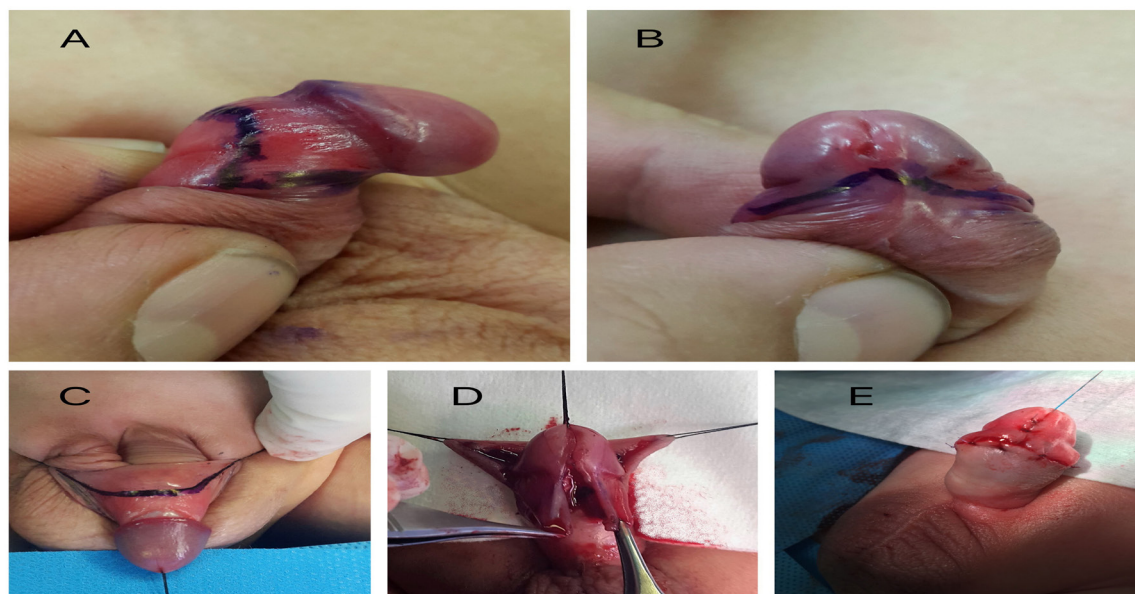


Figure 1. The modified Firlit's technique: procedure steps. **1-A:** Ventral chordee evident by gentle downward pressure at the penile base. **1-B:** The inverted V incision line, pointing toward the meatus. Dorsal meatotomy has not been done yet. **1-C:** The 'Chevron-like' incision line. **1-D:** The two mucosal collars brought to ventral after dissection. **1-E:** The final appearance

tube. If the urethra was thin, it was incised and re-tubularized and the patient was excluded from the study. Thereafter, a dorsal meatotomy was done if necessary. In the presence of a distal pit, the web between it and the hypospadiac meatus was incised and the two were joined. Then, a small amount of distilled water was injected between the distal urethra and skin to facilitate dissection. Then, an inverted V incision was made just proximal to the meatus (**Figure 1-B**). The arms of the inverted V were then extended towards the prepuce stay sutures. After that, the prepuce was retracted proximally and a 'Chevron-like' incision was made on the inner prepuce, about 5 mm proximal to the corona. The arms of incision were extended laterally towards the respective prepuce stay sutures (**Figure 1-C**) and dissection was done, using a sharp microscissor. On the ventral side, dissection was continued proximally to the point that chordee was completely released and all the adhesions between the skin and urethra were taken down. Thereafter, the 2 prepuce wings were brought to the midline, ventral penis (**Figure 1-D**) and sutured together in one layer, using 6-0 or 7-0 Vicryl sutures in a subepithelial or simple fashion. At the conclusion of the operation, chordee correction was ensured by an artificial erection, excess prepuce was excised and the shaft skin was sutured to the newly created mucosal collar (**Figure 1-E**). No urethral catheter was fixed; only a light dressing was applied on the wound that was removed just before discharge.

The patients were evaluated 8 hours post-operatively in terms of consciousness, oral intake tolerance and surgical site bleeding and discharged if no contraindication existed. Patients were asked to return for follow-up visits, 7 days and 6 months after surgery.

RESULTS

A total of 41 patients were operated on. Three of them were lost to follow-up; therefore, data were available for 38 patients. The mean \pm SD of patients' age was

20.4 \pm 13 months (range: 6-52 months). All surgeries were performed by a single pediatric urologist (FA). The 5 mm-wide mucosal collar was sufficient to compensate for the mild ventral skin deficiency after skin dissection in all patients. None of them needed a Byar's flap to cover the ventral shaft. All of the patients were able to void before being discharged the same day of the operation and there was no need for catheter insertion. No hematoma or bleeding was evident in any patient just before discharge. On the 7th day visit, the surgical site was evaluated for infection, prepuce wing or skin necrosis, hematoma and dehiscence. Ventral skin necrosis occurred in one patient (2.6%) in the shape of a narrow band that had been completely shed and replaced by new skin on the next visit (Clavien class I complication). No other complication was evident. On the 6-month visit, meatal stenosis, urethrocutaneous fistula and residual chordee were assessed. Meatal stenosis was checked by passing an 8 F Nelaton catheter. The parents were asked if they had noticed any penile deviation during erection and also downward pressure was applied on the penile base by the surgeon to assess ventral chordee. Fistula was assessed by physical examination and asking the parents about the presence of an extra stream of urine during voiding in toilet trained children. None of the patients developed meatal stenosis, fistula or chordee and no revision was needed in any of the patients. We considered the cosmetic result acceptable whenever there was no residual chordee and the meatus had a glanular position without stenosis. Based on these criteria, all the patients had satisfactory result.

DISCUSSION

Between 30-75% of the hypospadias cases are glanular, based on region and ethnicity⁽⁵⁾ and most hypospadias surgeries worldwide are for this minor type

of the anomaly.⁽⁶⁾ Usual techniques for repair of glandular hypospadias are urethral plate tubularization and MAGPI. In the presence of megameatus, preferred methods are glans approximation (GAP) and pyramid. However, in the absence of chordee, some have advocated simple circumcision.⁽⁶⁾ In glandular hypospadias and dorsal hood deformity, VC is usually absent or only of mild degrees. However, if it is present but not corrected, cosmetic result may be suboptimal. Polak et al. reported their experience with 102 patients with chordee without hypospadias. Forty of these patients had only skin chordee that all were corrected by penile degloving in a single step procedure without complication⁽⁷⁾ that is in similarity to our result.

On the other hand, dissection of the penile skin in the presence of even mild degrees of chordee, will result in some ventral skin deficiency that should be filled. When hypospadias surgery along with circumcision is to be performed, one step that is cosmetically important is to reconstruct the subcoronal skin. The softer skin in this area is less cornified and more translucent.⁽⁴⁾ Simple approximation of the ventral shaft skin to the coronal sulcus will eliminate this skin zone and produce an unnatural appearance. Applying the modified Firlit's technique, will address all the above mentioned issues. Bringing the wings to the ventral side is usually simple and straight forward, thanks to the elasticity of the prepuce tissue. In some cases, however, rotational flaps are needed to approximate the 2 collars without tension.⁽⁸⁾ Using larger size urethral catheter (8 French) has been associated with increased risk of meatal stenosis.⁽⁹⁾ We did catheterize our patients and had no meatal stenosis. The minor modification that we added to the technique is the inverted V incision just below the meatus. This can ensure total separation of the ventral skin from the urethra, resulting in complete chordee release and better cosmetic results. Complication rate in this method was low (2.6%) and of no clinical importance (Clavien class I) and cosmetic results were excellent. Another advantage was that there was no need for urethral catheterization after surgery, reducing the patient's post-operative discomfort. Although some complications of hypospadias surgery may occur after 1 year of surgery, it is unlikely that these happen in patients that have underwent modified Firlit's technique, considering the limited dissection in this method. The limitation of our study is that we did not use a standardized questionnaire to assess patients' and surgeon's satisfaction to present them as measurable parameters.

CONCLUSIONS

Surgical management of glandular hypospadias and dorsal hood deformity by modified Firlit's technique only, without glanuloplasty, is a simple method with excellent cosmetic results and low complication rate that avoids unnecessary glans dissections. Not only does this technique correct the skin chordee, but also fills the skin gap that develops after chordee release. When prepucioplasty is not desired, this technique can be considered as a viable option.

REFERENCES

1. Redman JF. Technique for repair of minimal distal balanitic hypospadias. *Urology*.

- 2006;68:1087-90.
2. Wettlaufer JN. Cutaneous chordee: fact or fancy. *Urology*.1974;4:293-6.
3. Devine CJ Jr, Horton CE. Chordee without hypospadias. *J Urol*. 1973;110:264-71.
4. Kolligian ME, Firlit CF. The mucosal collar revisited. *Urology*. 2000; 55: 114-7.
5. Springer A, van den Heijkant M, Baumann S. Worldwide prevalence of hypospadias. *J Pediatr Urol*. 2016 ;12:152.e1-7
6. Mousavi SA, Mohammadjafari H. Circumcision with the Plastibell device in hooded prepuce or glandular hypospadias. *Adv Urol*. 2009;864816.
7. Polat EC, Erdem MR, Topaktas R, Ersoz C, Onol SY. Our experience in chordee without hypospadias: results of 102 cases. *Urol J*. 2014;11:1783-7.
8. Redman JF. A favorable experience with rotational flap techniques for fashioning the Firlit preputial collar. *J Urol*. 2006;176:715-7.
9. Karakus SC, Koku N, Parmaksiz ME, Ertaskin I, Kilincaslan H, Deliaga H. The effect of urethral catheter size on meatal stenosis formation in children undergoing tubularized incised plate urethroplasty. *Urol J*. 2014 ;10:1095-8.