

A Comparative Study on the Clinical Efficacy of Two Different Disposable Circumcision Suture Devices in Adult Males

Junwen Shen^{1*}, Jihan Shi², Jianguo Gao¹, Ning Wang¹, Jianer Tang¹, Bin Yu¹, Weigao Wang¹, Rongjiang Wang¹

Purpose: We evaluated the safety and efficacy of two different kinds of disposable circumcision suture devices in adult men.

Materials and Methods: Adult male patients (n = 179; mean age: 23.7 years) with redundant prepuce and/or phimosis were included in a clinical trial from July 2015 to August 2016. Patients were divided into 2 groups: group A using the Langhe disposable circumcision suture device (n = 89), and group B using the Daming disposable circumcision suture device (n = 94).

Results: Intraoperative and postoperative bleeding were more serious in the group A of disposable circumcision suture device compared with the group B of disposable circumcision suture device (4.21 ± 1.31 ml) versus (2.56 ± 1.45 ml). Patients in the group B of disposable circumcision suture device had a longer swelling time (group A versus group B: 11.7 ± 0.9 days versus 14.5 ± 1.4 days), the postoperative pain score in the 7 days after surgery (group A versus group B: 2.9 ± 0.9 versus 3.8 ± 1.5), and higher postoperative infection rate (group A versus group B: 4.7% versus 13.8%), the differences were statistically significant ($p < 0.05$).

Conclusion: postoperative complications of the two kinds of disposable circumcision suture devices are different. We should pay attention to the risk of postoperative bleeding when the patients use the Langhe disposable circumcision suture device, while the patients who use the Langhe disposable circumcision suture device will have a longer healing time, and postoperative pain and the risk of infection cannot be ignored after the surgery.

Key words: disposable circumcision suture devices, redundant prepuce, postoperative complications.

INTRODUCTION

Redundant prepuce and phimosis are common male external genital diseases, and circumcision acts as the first-choice therapy for such diseases⁽¹⁾. The traditional circumcision surgery is featured by long operation duration, large intraoperative blood loss and prolonged postoperative healing course⁽²⁻⁴⁾. Disposable circumcision suture devices appeared in China in 2013 and have been widely applied since then. By drawing on the experience of intestinal anastomat cutting principle, circumcision suture devices can simultaneously fulfill foreskin cutting and suturing⁽⁵⁾.

At present, two different disposable circumcision suture devices, both of which are based on the cutting principle of intestinal anastomat, are used in our clinical practice while differ in varied processes for foreskin anastomosis. In clinical use, the effects of these two circumcision suture devices have been shown significantly different in their application to adult males. In this paper, the intraoperative and postoperative data of these two circumcision suture devices will be summarized to compare their differences in the treatment effects.

METHODS

Study Population

The data was collected from July 2015 to August 2016.

Two different disposable circumcision suture devices surgeries were conducted in adult patients with redundant prepuce or phimosis in our department, where the choice of surgical method followed patient's preference. The informed consent was signed before the surgery and the postoperative routine follow-up lasted 1 month. For those with postoperative complications, the follow-up was extended to the incision healing. All adult male patients (older than 18 years) having complete follow-up record were enrolled. A total of 179 patients were enrolled in the study and then divided into two different groups (group A that used Langhe circumcision suture devices and group B that used Daming circumcision suture devices) according to their surgical instrument. As a result, 85 cases were assigned to the group A and 94 cases to the group B.

Procedures

Medical Devices

Foreskin stapler type A: From Jiangxi Langhe Medical Instrument Co., Ltd., see **Figure 1**.

Foreskin stapler type B: Jiangsu Changshu Henry Medical Instrument Co., Ltd., see **Figure 2**.

Surgical Methods

First, the adherent part of foreskin was separated. In the case of ostium praeputiale stenosis, a sharp incision

¹ Departments of Urology, the first people's hospital of Huzhou, Zhejiang province, China.

² Departments of anesthesiology, the first people's hospital of Huzhou, Zhejiang province, China.

*Correspondence: Departments of Urology, the first people's hospital of Huzhou, Zhejiang province, China.

Tel: 0086 135 6722 8765. E mail: 13567228765@163.com.

Received December 2016 & Accepted July 2017

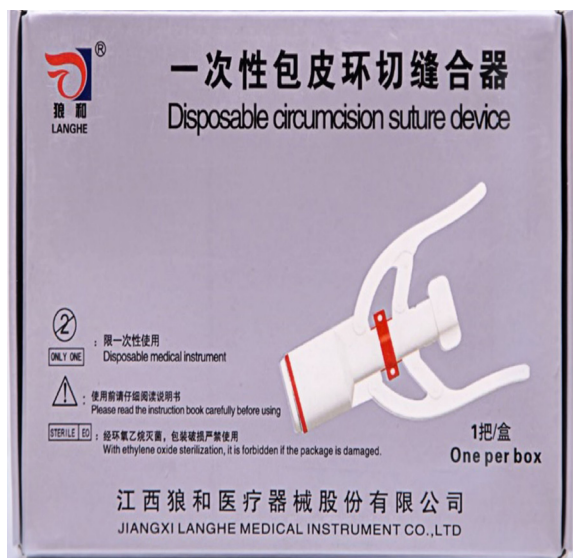

Figure 1. Langhe disposable circumcision suture device.

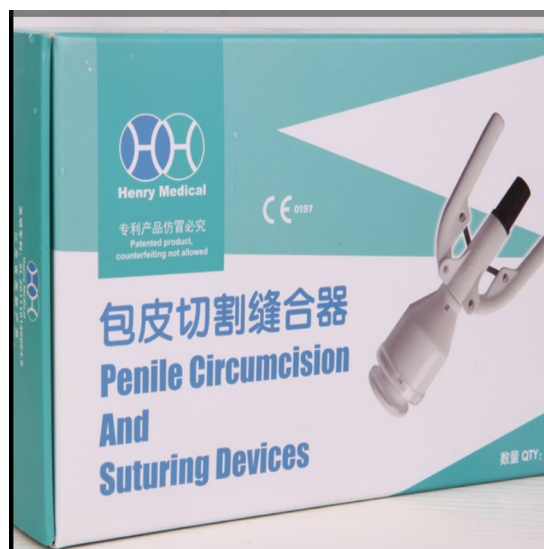

Figure 2. Daming disposable circumcision suture device.

could be performed by scissors, followed by lifting the ostium praeputiale and placing the stapler onto the balanus. With the frenulum loosened, the bell handles was spanned to the back of the frenulum, forming an angle of about 45°. Then the ostium praeputiale was fixed to the bell pole using tie, where the bell pole should be inserted into the center of the housing carefully. The adjustment knob was installed and tightened clockwise to align to end of bell pole with the top of adjustment knob. The safety catch was removed; the handles were held for 15-20 seconds and then released. The adjustment knob was turned counterclockwise and the bell stand was removed. The adherent foreskin was cut off. The entire bell stand was detached and the circular anastomotic site was pressed for 2 min, followed by pressure bandaging of the surgical wound. The pressure bandage was opened 3 days after surgery, and the wound was cleaned every day until healing⁽⁶⁻⁸⁾.

Evaluations

1. Operation duration: The time spent from the onset of anesthesia to the end of surgery.
2. Pain scores: With the scale set between 0 points and 10 points, visual analogue pain score (VAS) was used for pain scoring to record the intraoperative pain, pain within 24 hours after surgery, and pain within 1 week after surgery respectively.
3. Blood loss: Calculated by 5cm×5cm gauzes that could suck 5ml blood.
4. Postoperative complications assessment: Including postoperative infection, bleeding, incision dehiscence, second operation and other surgical complications.
5. Wound healing period: The time from the day of surgery to the day of complete wound healing.
6. Appearance satisfaction: Upon patients' visit to our department for review 1 month after surgery, their postoperative foreskin condition was recorded, including incision healing, cutting edge neatness, residual foreskin symmetry, penile erection restriction; the patient satisfaction was reported as "satisfactory" and "dissatisfactory".
7. The situation of staple shedding after surgery was recorded to identify whether the patient needed to visit

the hospital for manual removal of staples.

Statistical Analysis

SPSS19.0 statistical software was used to process the data, T test was adopted for numerical data comparison and χ^2 test for categorical data comparison, where $P < .05$ was defined as statistically significant difference.

RESULTS

Average age in group A was 23.2 ± 2.6 years, while average age in group B was 24.0 ± 3.1 years. 74 patients in group A had redundant prepuce, and 11 patient had phimosis. At the same time, 80 patients in group B had redundant prepuce and 14 patients had phimosis..

The intraoperative and postoperative recovery situations were compared between two groups (Table 1). The comparison of intraoperative and postoperative outcomes between two groups showed that the intraoperative blood loss of group A was higher than of group B and 2 cases from group A underwent second operation for suture hemostasis due to postoperative active bleeding. Group B was featured by longer staple-shedding time after surgery and thereby higher probability of visiting the hospital for removing staples; besides, these patients also suffered longer postoperative edema, greater postoperative pain degree as well as higher incidence of postoperative infection.

DISCUSSION

As male genital diseases commonly seen in urology, redundant prepuce and phimosis may increase the risk of urinary tract infection. Surgical excision of the redundant foreskin to expose the penis serves as the mainstream regime at present. Furthermore, excision of redundant foreskin can also reduce the risk of HIV infection^(2,9-12).

Conventional surgical circumcision had been used widely in past decades, however disposable circumcision suture devices had been recognized by the more and more urology doctors in the recent years. Comparing the two surgical methods, disposable circumcision suture devices has the advantages of short

Table 1. Comparison of two different operations' clinical outcome and complications.

	Group A (n=85)	Group B (n=94)	P-value
Operation duration (minutes)	8.1 ± 2.0	7.6 ± 2.2	> 0.05
Blood loss (mL)	4.21 ± 1.31	2.56 ± 1.45	< 0.01
Intraoperative pain (score)	2.8 ± 1.1	2.7 ± 1.5	> 0.05
Pain within 24 hours after surgery (score)	3.8 ± 1.7	4.0 ± 1.4	> 0.05
Second operation	2	0	< 0.001
Period of complete staple shedding (days)	14 ± 3	21 ± 4	< 0.001
Pain within 7 days after surgery (score)	2.9 ± 0.9	3.8 ± 1.5	< 0.001
Incision edema time (days)	11.7 ± 0.9	14.5 ± 1.4	< 0.001
Cases requiring manually removing staples	7/85	18/94	< 0.05
Cases reporting dissatisfactory appearance	8	7	> 0.05
Cases of postoperative incision infection	4(4.7)	13(13.8)	< 0.05

Data is presented as mean ± SD, N, N(%) or %

operation time, less operation pain and less blood loss. This method benefits both the doctor and patients. That is the reason why it had been used widely in the recent years.

However, with the extensive use of the disposable circumcision suture devices, we found some problems in the surgical procedures themselves, such as postoperative incision edema, infection, local incision dehiscence, especially the longer time for staple shedding after surgery; those, whose staples fail to shed, need to visit the hospital for manual removal. All of this increase the patient's pain and mental stress⁽¹³⁻¹⁶⁾.

Two different types of disposable circumcision suture devices are currently used in our medical center. Although both of them are based on the principle of intestinal anastomat and can simultaneously fulfill foreskin cutting and suturing, the intraoperative and postoperative efficacy of these two surgical instruments have been shown differently (Figures 3-4).

Compared with patients using foreskin stapler type B, those using foreskin stapler type A were associated with more obvious intraoperative blood loss and higher risk of postoperative bleeding. Of 85 patients, obvious oozing within 6 hours after surgery was reported in 2 cases, who underwent second operation for cut suturing to achieve hemostasis. By comparing these two different disposable circumcision suture devices, it was demonstrated that stapler type B incorporates a pressure by plastic sheet upon the incision wound and the staples

fix the wound outside the plastic sheet (Figure 4). On the contrary, the surgical instrument type A directly fixes the incision wound with the staples (Figure 3). It is precisely this difference that leads to the fact that instrument type B has more ideal intraoperative and postoperative compression hemostasis effect as well as significantly reduced intraoperative and postoperative bleeding risk.

At the same time, we also found that the patients undergoing operation type B were characterized by longer postoperative recovery time. First, the postoperative edema time of patients undergoing operation type B was found to be significantly longer than those undergoing operation type A, so was the case with postoperative pain degree and postoperative infection rate. We believe that the cause resulting in the 3 differences above is the process used by surgical instrument type B. As mentioned before, the work principle of surgical instrument type B is to press the wound with a plastic sheet while the staples are used to fix the wound and plastic sheet. Therefore, it is more likely to cause wound compression and incarceration, further leading to local edema and inflammation, especially on the site of frenulum of prepuce, which appears to be the position most likely to develop edema. Edema may accelerate incarceration and cause local pain or even local inflammation (Figures 5-6).

Secondly, the comparison of staple shedding indicated that the staple shedding time of group B was longer than

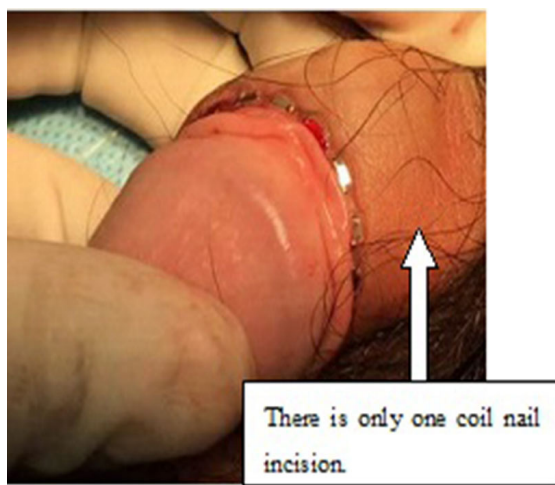


Figure 3. Surgical outcomes in group A.

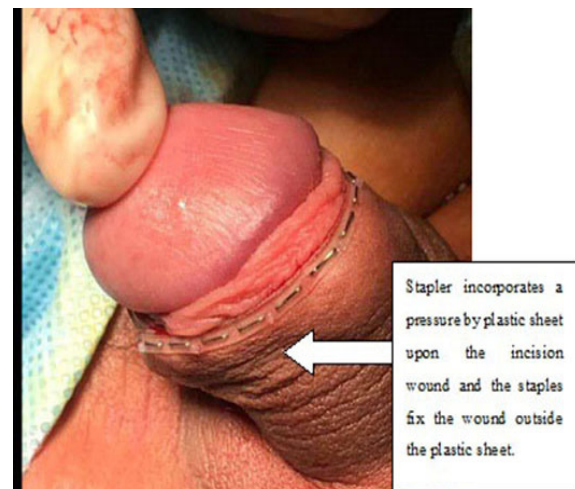


Figure 4. Surgical outcomes in the group B.

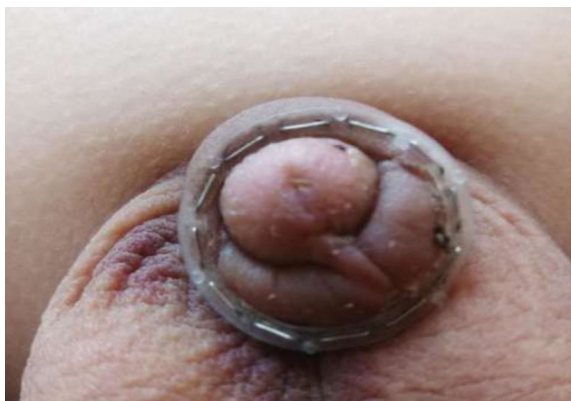

Figure 5. Edema of frenulum of prepuce was likely to be most serious.

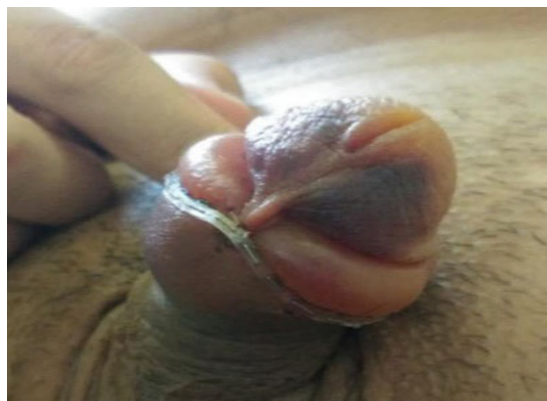


Figure 6. Edema may accelerate incarceration.

group A and associated with more cases of manually removal. In our opinion, the tendency of group B to cause postoperative incision edema will lead to the incarceration of circular plastic sheet in the edema tissue, which impedes staple shedding. Meanwhile, the comparison of the specific postoperative incarceration situation of stapling between two groups reported two differences. For group A, the residual staples were usually single and isolated; the staples were often embedded by the surrounding skin and difficult to remove due to deeply stapling into skin. For group B, the residual staples after surgery were often segmental, and the common situation was that several or a row of staples failed to shed, which led to the incomplete shedding of plastic sheet; however, the staples were easy to remove since the stapling depth was relatively shallow.

According to the investigation on postoperative adverse symptoms and causes of two surgery procedures, we summarize that the different postoperative complications of two disposable circumcision suture devices were derived from their different processes, which requires us to take corresponding measures to reduce such adverse symptoms based on these two set of conditions. For circumcision suture devices type A, absorbable suture can be used for intermittent reinforcement of the wound after intraoperative foreskin anastomosis, and the patients will also be asked to reduce physical activity within 24 hours after surgery so as to lower the risk of postoperative bleeding. For circumcision suture devices type B, the clearance of circular plastic sheet among the staples can be cut with scissors. In general, we cut at three positions, namely, the 12 o'clock, 4 o'clock and 8 o'clock, to reduce the possibility of plastic sheet incarceration in the incision after surgery. Besides, the patients are also informed of the fact that the postoperative edema may last slightly longer so as to relieve their postoperative anxiety. However, if the pain remains obvious 24 hours after surgery, then prompt hospital visit will be recommended to observe whether the plastic sheet is incarcerated in the incision and, if necessary, manually removal as early as possible.

CONCLUSIONS

In conclusion, these two namely are featured by different postoperative recovery situations due to process differences. Langhe circumcision suture devices is associated with greater intraoperative and postoperative

blood loss and higher risk of secondary bleeding, while Daming circumcision suture devices may lead to longer postoperative edema and slower postoperative recovery. Although difficult postoperative staple shedding is reported in both of them, Daming stapler has a higher incidence, and the patient needs to visit the hospital for manual removal if the staples fail to shed within one month after surgery. Finally, we found that the postoperative recovery can be improved if differentiated treatment is conducted regarding the postoperative recovery characteristics of these two staplers. For patients reporting postoperative stapler incarceration, the plastic sheet and staples should be removed promptly.

REFERENCES

1. Dunsmuir, W. D. & Gordon, E. M. The history of circumcision. *BJU Int* 1993; 83 Suppl 1, 1-12.
2. Hayashi, Y. & Kohri, K. Circumcision related to urinary tract infections, sexually transmitted infections, human immunodeficiency virus infections, and penile and cervical cancer. *Int J Urol* 2013; 769-75.
3. Williams, N. & Kapila, L. Complications of circumcision. *Br J Surg* 1993; 1231-6.
4. Ahmed, A., Mbibi, N. H., Dawam, D. & Kalayi, G. D. Complications of traditional male circumcision. *Ann Trop Paediatr* 1999 : 113-7.
5. Gu, C. et al. Introducing the Quill device for modified sleeve circumcision with subcutaneous suture: a retrospective study of 70 cases. *Urol Int* 2015 : 255-61.
6. Pan, F. et al. Circumcision with a novel disposable device in Chinese children: a randomized controlled trial. *Int J Urol* 2013: 220-6.
7. Mohta, A. Editorial Comment from Dr Mohta to circumcision with a novel disposable device in Chinese children: a randomized controlled trial. *Int J Urol* 2013: 228-9.
8. Millard, P. S., Wilson, H. R., Goldstuck, N. D. & Anaso, C. Rapid, minimally invasive adult voluntary male circumcision: a randomised

- trial of Unicirc, a novel disposable device. *S Afr Med J* 2013: 52-7.
9. Shaffer, D. N. et al. The protective effect of circumcision on HIV incidence in rural low-risk men circumcised predominantly by traditional circumcisers in Kenya: two-year follow-up of the Kericho HIV Cohort Study. *J Acquir Immune Defic Syndr* 2007: 371-9.
 10. Kelly, R. et al. Age of male circumcision and risk of prevalent HIV infection in rural Uganda. *AIDS* 1999: 399-405.
 11. Gray, R. et al. The effectiveness of male circumcision for HIV prevention and effects on risk behaviors in a posttrial follow-up study. *AIDS* 2012: 609-15.
 12. Bitega, J. P., Ngeruka, M. L., Hategekimana, T., Asimwe, A. & Binagwaho, A. Safety and efficacy of the PrePex device for rapid scale-up of male circumcision for HIV prevention in resource-limited settings. *J Acquir Immune Defic Syndr* 2011: 127-34.
 13. Zhang, Z. et al. Application of a novel disposable suture device in circumcision: a prospective non-randomized controlled study. *Int Urol Nephrol* 2016: 465-73.
 14. Ren, Y. & Yan, J. J. [Modified circumcision with a disposable suture device]. *Zhonghua nan ke xue = National journal of andrology* 2015: 541-4.
 15. Huo, Z. C. et al. Use of a disposable circumcision suture device versus conventional circumcision: a systematic review and meta-analysis. *Asian J Androl*, 2017: 362-7.
 16. Cao, D. H., Dong, Q. & Wei, Q. Commentary on "Disposable circumcision suture device: clinical effect and patient satisfaction". *Asian J Androl* 2015: 516.