

Extra-renal Transplanted Kidney Stone: Case Presentation and Literature Review

Abbas Basiri, Mohammad Nadjafi Semnani, Hamed Mohseni Rad*

Keywords: Transplantation; urolithiasis.

Soft tissue calcification is common in uremic patients. Wound calcification or ossification is not so prevalent except in specific conditions like inflammation and ischemia or wound tension. We present a 40-year-old transplanted patient, not only perirenal ossification but also with multiple perirenal stones. The presentation was severe pain on the site of transplantation. Pre-op CT scan revealed perirenal calcified mass. Intraoperative finding was very thick tissue accompanied with a lot of stones around the transplanted kidney. The patient had history of ureteral fistula after renal transplantation that needed temporary percutaneous nephrostomy and then uretero-neocystomy. It seems that urinary leakage through nephrostomy site probably is the predisposing factor for stone formation around the kidney where as there is no stone inside the Kidney.

INTRODUCTION

Postoperative calcifications are visible in up to 25.7% of postoperative abdominal computed tomography (CT) scans of midline incisions⁽¹⁾. Soft tissue and vascular calcifications are commonly present in uremic patients due to disturbances in calcium and phosphate balance and also, hyperparathyroidism⁽²⁾. However, visceral calcifications are serious and uncommon complications of end-stage renal disease⁽³⁾. Subcutaneous calcification has been well described in the medical literature as a complication of chronic venous insufficiency, inflammation and ischemia or wound tension⁽⁴⁾. Regardless of the etiology, the presence of calcium deposits in soft tissues may lead to chronic wounds that do not respond to conservative local wound care⁽⁵⁾. While calcification and opacification is reported in literature, but to our best knowledge there is no report of stone formation around the kidney.

CASE REPORT

A 40-year-old man received a first renal transplant in 2011 from living donor by right pararectal incision. The cause of end-stage renal disease was hypertension. Percutaneous nephrostomy had been performed six months after transplantation due to hydronephrosis and fever with ureteral fistula and the patient had eventually undergone ureteral neocystostomy operation with same para-rectal incision and 4-0 Vicryl suture and 4.8 Fr double-J stenting which was extracted 4 weeks later.

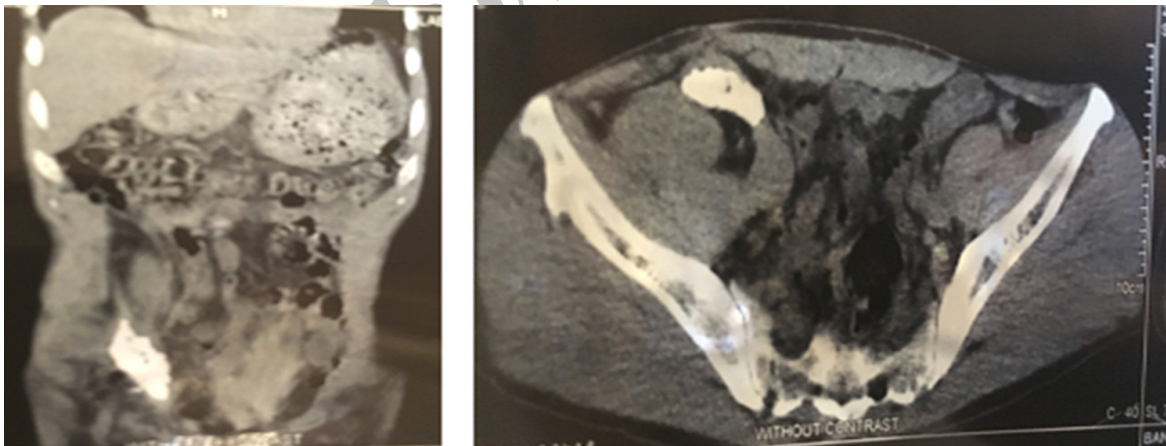


Figure 1. Pre-operative abdomen-pelvic CT scan.

Urology and Nephrology Research Center, Shahid Labbafinejad Medical Center, Shahid Beheshti University of Medical Sciences, Tehran, Iran.

*Correspondence: Urology and Nephrology Research Center, Shahid Labbafinejad Medical Center, Shahid Beheshti University of Medical Sciences, Tehran, Iran.

E- mail: Sirhamed@hotmail.com.

Received January 2017 & Accepted June 2017



Figure 2. Extra renal stones excised.

Five years later, he came with pain and discomfort at right lower quadrant around the graft. Examination revealed subcutaneous tense and immobile mass. Patient serum creatinine was 1.7 mg/dl without any urinary problem. We accomplished biopsy which reported inflammation and fibrosis with calcification. Computed tomography (CT) marked large calcified mass ventral to graft but sparing the graft and spreading to pelvic cavity. (**Figure 1**)

We planned surgery by incision on previous surgery line. The graft was intact without any invasion. We excised the calcified mass and stones. The excised masses were just like numerous packed kidney stones (Figure 2). Histology demonstrates calcification and ossification and stone analysis reported Calcium Oxalate 20%, Calcium Hydrogen Phosphate 20%, Ammonium Mg Phosphate 5% and remaining 55% as undetermined. 24 hour urine collection of patient was as follows: Volume 1440 cc, Creatinine: 1303mg, PH: 6.6, Calcium: 323 mg, Oxalate 27mg, Citrate 299mg, and Uric Acid 389mg. Serum investigations revealed Calcium: 9.9 mg/dL, PTH: 69 pg/mL, and Uric Acid 6.9 mg/dL.

DISCUSSION

A review of the literature suggests that dystrophic wound calcification is a topic that is currently not well understood. Despite tight regulation of serum calcium, subcutaneous or cutaneous tissue calcification may occur⁽⁷⁾. Focal tissue damage (hematoma, infection, injection of heparin, wound tension) can yield to calcification or ossification⁽³⁾. Dystrophic calcifications have been seen in a variety of clinical settings, including chronic venous insufficiency, areas of trauma, osteomyelitis, panniculitis, hypervitaminosis D and areas of infarcts. Metastatic tissue calcification is seen in cases where there is an underlying defect in calcium and/or phosphate metabolism. The most well published form of metastatic tissue calcification is seen in chronic renal failure⁽⁶⁾. Chronic renal failure may deposit calcium in tissues as benign nodular calcifications or in the form of calciphylaxis. Calciphylaxis is characterized by progressive vascular calcification, soft tissue necrosis, and ischemic necrosis of the skin⁽⁸⁾. Cutaneous ossification involves membranous and enchondral bone formation in the skin. This condition may be seen in areas surrounding neoplasm, in calcified tissue, in inflammatory and metabolic diseases, and infrequently in normal tissue⁽⁹⁾.

Differentiating subcutaneous calcification from subcutaneous ossification cannot be made by gross visualization of the wound or wound deposits. Use of

radiographs is only somewhat helpful in making the distinction. Histopathologic evaluation of the deposits is the only way to differentiate the two types of wound deposits. Calcified tissue may be seen with osseous deposits at the time of biopsy⁽⁷⁾.

It is believed that calcification is a precursor to ossification. It is a common occurrence to see calcium deposits in conjunction with osseous tissue⁽⁷⁾. The mechanism of formation of such material is not well understood but involves deposition of collagen type I matrix by osteoblasts. It is interesting to note that virtually any process that calcifies may secondarily ossify, but primary ossification is a rare occurrence⁽⁹⁾. As for normal ossification, the exact mechanisms by which osseous metaplasia development is triggered remains unclear; however, heterotopia, dystrophic calcifications, ossification of damaged areas, metastatic calcification, and metaplasia in healing tissue may be considered predisposing factors. Dense areas of scar tissue may become secondarily ossified⁽¹⁰⁾.

While fibroblasts potentially represent osteogenic precursor cells and orchestrate the whole process of neo-osteogenesis, ischemia and inflammation may act as inducing factors, altogether forming a suitable environment for ossification⁽¹¹⁾. Increasing evidence suggests that pericytes, the smooth muscle cells enveloping micro vascular endothelial cells, behave like mesenchymal stromal cells and can be the source of osteogenic cells in heterotopic ossification⁽¹²⁾. In this case there was a lot of real stone beside histologic report of inflammation, calcification and ossification. Probably urine leakage in the setting of percutaneous nephrostomy is the culprit. So we concluded to name it extra renal kidney stone which is rare complication in kidney transplantation post operational care based on our literature review.

REFERENCES

1. Kim J, Kim Y, Jeong WK, and et al. Heterotopic ossification developing in surgical incisions of the abdomen: analysis of its incidence and possible factors associated with its development. *J Comput Assist Tomogr.* 2008;32:872-6
2. Alfrey AC, Solomons CC, Ciricillo J, Miller NL. Extraosseous calcification. Evidence for abnormal pyrophosphate metabolism in uremia. *J Clin Invest* 1976;57:692-9
3. Labidi J, Ariba YB, Gabsia AB, Ajili F,

- Battikh R, Louzir B, et al. Severe metastatic calcifications in a hemodialysis patient. *Saudi J Kidney Dis Transpl* 2016;27:1037-42
4. Peled I, Bar-Lev A, Wexler M. Subcutaneous calcifications of the lower limbs. *Ann Plastic Surg* 1982; 8:310-3
 5. Sunquist A, Kurien A, Duke M. Subcutaneous calcification of the legs in chronic venous insufficiency. *Connecticut Med* 1966; 30:41-2.
 6. Walsh J, Fairley J. Calcifying disorders of the skin. [Continuing Medical Education] *J Amer Acad Dermatol* 1995; 33:1-28.
 7. Richard J, Brietstein, E. David Sonkin, Charles Jason Hubbard. Nonhyperparathyroid Wound Calcifications: Two Case Presentations and Literature Review. *WOUNDS*. 2002; 14:136-41.
 8. Burkhart CG, Burkhart CN, Mian A. Calciphylaxis: A case report and review of literature. *Wounds* 1999; 11:58-61.
 9. Touart D, Sau P. Cutaneous deposition diseases, part II. [Continuing Medical Education] *J Amer Acad Dermatol* 1998;39:1-34.
 10. Sanders BP, Orlando G, Peloso A, Katari RS, Iskandar SS, Farney AC, et al. Osseous metaplasia in kidney allografts as a paradigm of regenerative medicine principles. *Exp Clin Transplant*. 2014 Aug; 12:371-3.
 11. Asami G, Dock W. Experimental studies on heteroplastic bone formation. *J Exp Med*. 1920; 32:745-66.
 12. Doherty MJ, Ashton BA, Walsh S, et al. Vascular pericytes express osteogenic potential in vitro and in vivo. *J Bone Miner Res*. 1998; 13:828-838.