

Calculi in the Prostatic Surgical Bed as a complication after Holmium Laser Enucleation of the Prostate

Young Ju Lee¹, Seung-June Oh^{2*}

Purpose: To report de novo calculi in the prostatic surgical bed as a complication of Holmium laser enucleation of the prostate (HoLEP).

Materials and Methods: Patients who underwent HoLEP and were enrolled in our Benign Prostatic Hyperplasia (BPH) Database Registry from July 2008 to December 2015 were reviewed. Cases of calculi removal in the prostatic surgical bed were identified. Clinical data, including preoperative evaluation, postoperative symptoms with a detailed history, urinalysis, pathology, cystourethroscopy, and stone analysis were collected and described.

Results: Eight patients were identified including one patient who underwent HoLEP at another hospital. Among the 877 patients in our BPH database, 7 (0.8%) underwent calculi removal in the prostatic surgical bed. Median age was 67.0 years. Median prostatic volume was 75.5mL. The most common symptom was severe stabbing urethral pain (n = 4), with a median of 13 months after HoLEP. Calculi were pedunculated in the prostatic surgical bed or in the bladder neck with a small mucosal connection. Pathology of the resected tissue showed granulation tissue formation and dystrophic calcification.

Conclusion: Calculi in the prostatic surgical bed or the bladder neck after HoLEP have never been reported previously. Although it is very rare, recurrent urethral pain, persistent pyuria, and recurrent gross haematuria are signs for further investigation. Cystourethroscopy should be performed to rule out the presence of stones. Careful history taking and having an index of suspicion are important for the diagnosis.

Keywords: prostatic hyperplasia; urinary calculi; transurethral resection of prostate; complication.

INTRODUCTION

Open prostatectomy or transurethral resection of the prostate (TURP) has been the standard of care in the treatment of benign prostatic hyperplasia (BPH). Laser prostatectomy was initially described in 1986 and became popular in 1990s⁽¹⁾. The use of this method has increased in the last decade in the treatment of BPH⁽²⁾. Holmium laser enucleation of the prostate (HoLEP) is an effective and less invasive alternative to open prostatectomy for the surgical treatment of BPH. This method is associated with more favourable outcomes than monopolar TURP⁽³⁾. The coagulative property of holmium laser provides a relatively bloodless field with no risk of systemic fluid absorption resulting in transurethral resection syndrome.

Overall, the complications after HoLEP are fewer than those after TURP⁽⁴⁾. However, we discovered patients with de novo calculi in the prostatic surgical bed or bladder neck after HoLEP, which has never been reported previously. The purpose of this study is to report this as a complication and the characteristics of its clinical presentation.

PATIENTS AND METHODS

Patients

We reviewed a patient cohort who had undergone HoLEP at our institution by a single surgeon (SJO) from July 2008 to December 2015. After the approval of institutional review board, we identified patients who also underwent urethral stone removal after HoLEP and reviewed their clinical presentation. In the course of research, additional 1 patient was identified who underwent HoLEP at another hospital and included for the analysis. Patients who underwent transurethral surgery due to de novo calculi were included. Patients who had previous urinary calculi were excluded.

HoLEP was performed as we have previously described⁽⁵⁾. For the enucleation, the three-lobe or four-lobe technique was used with 26Fr resectoscope. After careful haemostasis by using Holmium laser, morcellation was performed with a tissue morcellator (Versacut; Lumenis Ltd.) through the guidance of a 26-Fr nephroscope. After the operation, the patients were discharged on postoperative day 1 after a voiding trial. When considerable haematuria existed, the discharge was deferred for 1 or 2 days. Follow-up was done at postoperative 2 weeks, 3 months, 6 months, and 12 months. Careful

¹Department of Urology, Seoul National University Bundang Hospital, Seongnam-si, Republic of Korea.

²Department of Urology, Seoul National University Hospital, Seoul National University School of Medicine, Seoul, Republic of Korea.

*Correspondence: Department of Urology, Seoul National University Hospital, Seoul National University School of Medicine, 101 Daehak-ro, Jongno-gu, Seoul, 03080, Korea.

Phone: +82-2-2072-2406. Fax: +82-2-742-4665. E-mail: sjo@snu.ac.kr.

Received May 2017 & Accepted December 2017

Table 1. Characteristics of the patients.

Clinical characteristics at the time of HoLEP	Case 1	Case 2	Case 3	Case 4 ^b	Case 5 ^c	Case 6	Case 7	Case 8
Age (years)	61	61	67	62	71	77	73	67
Total prostate volume (mL) ^a	121	39	68	N.A.	85	56	83	N.A.
Prostatic calcification	No	No	No	N.A.	No	No	No	N.A.
Main presenting symptom	New onset persistent Pyuria	Severe urethral pain after voiding	Gross haematuria, postvoid urethral discomfort	Severe urethral stabbing pain, urgency	Severe urethral pain during and after voiding, UUI	Gross haematuria, UUI	Urethral pain at the end of voiding, new onset persistent pyuria	New onset microscopic haematuria
Symptom onset after HoLEP (months)	3	13	19	13	11	6	44	26
Symptom onset to diagnosis (months)	3	1	0.7	1	6	12	3	1
Stone analysis	90% CA, 10% CaOxD	65% CaOxD, 35% CA	80% Brushite, 20% CaOxD	60% CaOxD, 10% CA	60% CaOxD, 10% CA	65% CaOxD, 35% CA	80% CaOxD, 20% Struvite	95% CaOxD, 5% CaOxD

Abbreviations: CA, carbonate apatite; CaOxM, calcium oxalate monohydrate; CaOxD, calcium oxalate dihydrate; N.A., not available; PSA, prostate-specific antigen; PVR, postvoid residual volume; Qmax, maximal flow rate; UUI, Urge urinary incontinence.
^{a)} Measured with transrectal ultrasonography. ^{b)} Referred from another hospital. ^{c)} Had a recurrence after 8 months.

history taking, physical examination, and workups including urinalysis and uroflowmetry were performed at every follow-up visit. Cystoscopic examination was performed when the patient complained of severe urethral pain, gross haematuria or persistent microscopic haematuria. Computed tomography was performed for gross haematuria and persistent pyuria.

Data analysis

Data on preoperative evaluation, HoLEP procedures, the date of calculi removal in the prostatic surgical bed, the main presenting symptom, symptom onset after HoLEP, the interval from symptom onset to the diagnosis, cystoscopic findings, pathology if present, and the result of stone analysis were obtained. The pathological images were examined by a pathologist. Physical stone

analysis was performed using infrared absorption spectrometry. The results were expressed as a true value or median, which was calculated by using Microsoft Excel software.

RESULT

A total of 8 patients who underwent calculi removal in the prostatic surgical after HoLEP were identified, including one patient who underwent HoLEP at another hospital. In our prospective BPH database, 7 (0.8%) patients were identified among 877 patients who underwent HoLEP between July 2008 and December 2015. The characteristics of the patients are presented in **Table 1**. Their median age was 67 years. All patients underwent HoLEP without immediate complications and were discharged at postoperative day 1 after a successful voiding trial.

Severe urethral stabbing pain (n = 4) was the most common presenting symptom followed by gross haematuria (n = 2), pyuria (n = 2), and microscopic haematuria (n=1). The urethral pain was typically very unpleasant, burning sensation after voiding or during voiding. The median duration from HoLEP to symptom onset was 13 months (range, 3–44 months). The median interval from the initial onset of symptoms to the diagnosis was 2 month (range, 0.7–12 months).

After the diagnosis of calculi in the prostatic surgical bed, calculi removal was performed. All patients had calculi at the bladder neck and/or the prostatic surgical bed. The cystoscopic images of five patients are presented in **Figure 1**. The largest one was 1.7 cm sized (Case 3). Most calculi were less than 1 cm and spiculate in shape. The stones were hanging and/or impacted in the prostatic surgical bed in a scattered pattern. Calculi in the bladder neck dangled from the bladder neck, connected to the mucosa. Transurethral resection of the surgical bed was performed in one patient, and the pathological examination revealed urothelial denudation, granulation tissue formation, and dystrophic calcification (**Figure 2**). The symptoms were resolved after the surgery. However, 1 patient (case 5) had a turbid urine and microscopic haematuria after 8 months and underwent the same surgery again for recurred

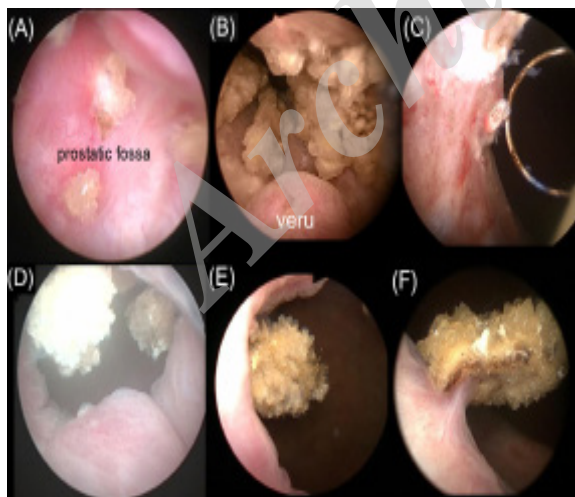


Figure 1. Cystoscopic images. (a) Small stellated stones are impacted in the mucosa of the prostatic surgical bed (Case 1). (b) Numerous stones were identified in the prostatic surgical bed and the bladder neck (Case 4). (c) Transurethral resection of the prostatic surgical bed in case 4 after clearing the stones from the surgical bed. (d) Stones dangled from the bladder neck (Case 5). (e) Recurred stone hanging in the bladder neck (Case 5). (f) Stone dangled from the bladder neck connected to the bladder mucosa (Case 6).

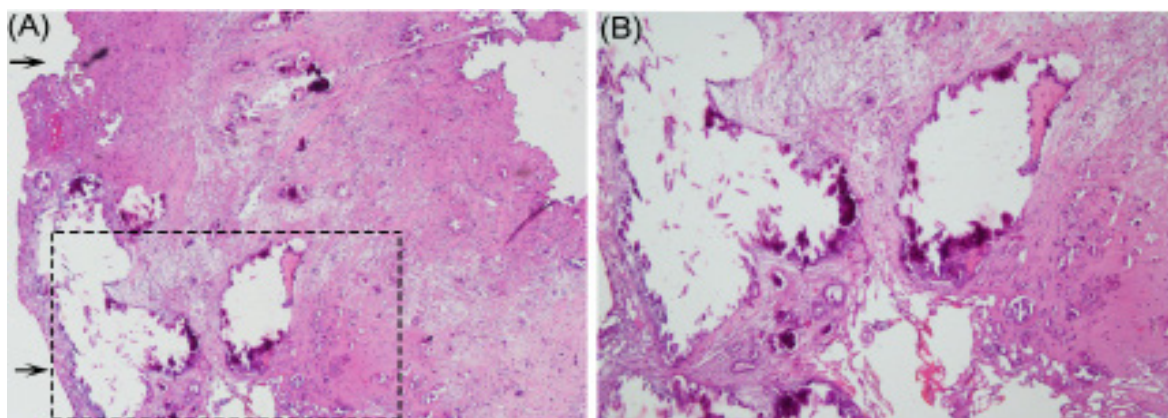


Figure 2. Pathology of the specimen from the transurethral resection described in Fig. 1C (Case 4). (a) Haematoxylin and eosin staining of the resected tissue showing granulation tissue formation ($\times 40$) and dystrophic calcification. (b) A magnified view of the rectangled area of Fig. 2a showing dystrophic calcification ($\times 100$). The urethral luminal side is marked with an arrow.

bladder neck stone. Stone analysis for the 2nd operation revealed 95% Calcium oxalate dihydrate and 5% Calcium oxalate monohydrate. There were no evidence of urinary tract infection before the diagnosis, except 1 patient (Case 1) who complained of left testicular discomfort.

DISCUSSION

Long-term complications of HoLEP include retreatment, urethral stricture, bladder neck contracture, and meatal stenosis. To our knowledge, this is the first case series on calculi in the prostatic surgical bed after HoLEP. The occurrence of calculi in the surgical bed after laser prostatectomy is rare but possible. Previous reports include a case of urethral stone formation after potassium-titanyl-phosphate (KTP) laser ablation of the prostate⁽⁶⁾. These stones can form even 5 years postoperatively⁽⁷⁾.

Many etiologic factors have been postulated to explain calculi formation after photoselective vaporization of the prostate with a KTP laser. First, stasis of urine at the prostatic fossa can form urethral calculi, provided that no concurrent urethral strictures exist⁽⁶⁾. Second, the presence of debris or foreign bodies after the surgery can serve as a nidus for stone formation, which can grow with time⁽⁷⁾. Finally, the coagulative necrosis caused by the laser energy itself can induce dystrophic calcification as a reaction to tissue damage, leading to calculi formation.

A holmium laser operates at a wavelength of 2,140 nm in a pulsed mode⁽⁸⁾. This high-power energy can be used for incision, ablation, resection, and enucleation of prostatic tissues. Diffusion of thermal energy into the surrounding tissue is minimal when using a holmium laser. The thermal energy is absorbed by water, and the safety of the tissue is not compromised, unless direct contact occurs⁽⁹⁾. A holmium laser can be used for superficial tissue ablation and adequate haemostasis for vessels with a < 1 mm diameter. Substantial tissue coagulation can be accomplished at a depth of 3–4 mm⁽¹⁰⁾. Although the holmium-YAG laser can penetrate tissues to a depth of only 0.4 mm, a 1–2-mm rim of surrounding tissue coagulation was observed after holmium ablation of the prostate in a canine model⁽¹¹⁾. Because we use cutting, ablation, and coagulation freely during

surgery, coagulative necrosis may occur, which can induce dystrophic calcification as a postoperative reactive change. In addition, threads of mucosa can serve as a nidus for stone formation during the wound-healing process, as fluttering mucosal flags are observed immediately after surgery. Unlike in radical prostatectomy, mucosa-to-mucosa anastomosis is not possible during an endoscopic procedure. The wound-healing process is essential for the recovery process. During the recovery, chronic inflammatory infiltrates and granulation tissues replace the necrotic coagulum from the base at 7 weeks after thermal laser injury⁽¹²⁾. Until 12 weeks after the laser surgery, a few fragments of necrotic tissues or eschars adhere to the prostatic urethra. During the restoration of mucosal injury, mucosal flags can serve as a nidus for calculi formation. During the healing process, crystal deposition can occur on the de-epithelialized surface, resulting in subsequent stone growth.

The presence of pyuria and microscopic haematuria after prostatic surgery is not always a pathological finding⁽¹³⁾. Persistent pyuria is one of the most common complications after transurethral prostatectomy⁽¹⁴⁾. Previous reports have noted that pyuria persisted longer than microscopic haematuria regardless of the type of the surgery (monopolar TURP vs. bipolar TURP vs. open prostatectomy). Persistent pyuria lasted a median of 274 days, which was significantly longer than the duration of persistent microscopic haematuria (176 days). Therefore, postoperative pyuria can be underestimated, and even ignored, if the patient does not have the compatible symptoms. However, as one patient in this study showed persistent pyuria after treatment with antibiotics, further evaluation is necessary. As noted in our cases, a high degree of suspicion for urethral stones should be adopted in patients with recurrent gross haematuria and unexplained severe urethral pain at any time after HoLEP. Early and careful history taking and cystourethroscopy can be helpful in such cases. A large intake of water might prevent urine stasis and urethral calculi formation, especially during the early postoperative recovery period.

Our study has a few limitations. This study was retrospective in nature, involving a cohort of patients operated by a single surgeon. However, the data were prospectively collected. Although this is a very rare complication, the surgeon's preference for the use of

laser power and the haemostatic pattern can be factors affecting the incidence of urethral stones after HoLEP.

CONCLUSIONS

In conclusions, urinary calculi formation in the prostatic fossa or the bladder neck after HoLEP is a rare but possible complication. Unexplained urethral pain or discomfort, persistent pyuria, and recurrent gross haematuria require further investigation. Cystourethroscopy should be performed to rule out the presence of stones. A focused history taking and having an index of suspicion are essential to the diagnosis.

ACKNOWLEDGEMENT

Ye-Young Rhee provided photos of pathology.

CONFLICT OF INTEREST

The authors report no conflict of interest.

REFERENCES

1. Floratos DL, de la Rosette JJ. Lasers in urology. *BJU Int.* 1999;84:204-11.
2. Schroeck FR, Hollingsworth JM, Kaufman SR, Hollenbeck BK, Wei JT. Population based trends in the surgical treatment of benign prostatic hyperplasia. *J Urol.* 2012;188:1837-41.
3. Cornu JN, Ahyai S, Bachmann A, et al. A Systematic Review and Meta-analysis of Functional Outcomes and Complications Following Transurethral Procedures for Lower Urinary Tract Symptoms Resulting from Benign Prostatic Obstruction: An Update. *Eur Urol.* 2015;67:1066-96.
4. Vincent MW, Gilling PJ. HoLEP has come of age. *World J Urol.* 2015;33:487-93.
5. Kim M, Lee HE, Oh SJ. Technical aspects of holmium laser enucleation of the prostate for benign prostatic hyperplasia. *Korean J Urol.* 2013;54:570-9.
6. Tasci AI, Tugcu V, Ozbay B, Mutlu B, Cicekler O. Stone formation in prostatic urethra after potassium-titanyl-phosphate laser ablation of the prostate for benign prostatic hyperplasia. *J Endourol.* 2009;23:1879-81.
7. Malde S, Rajagopalan A, Koslowski M, Simoes AD, Choi WH, Shrotri NC. Potassium-titanyl-phosphate laser vaporization of the prostate: a case series of an unusual complication. *J Endourol.* 2012;26:682-5.
8. Le Duc A, Gilling PJ. Holmium laser resection of the prostate. *Eur Urol.* 1999;35:155-60.
9. van Rij S, Gilling PJ. In 2013, holmium laser enucleation of the prostate (HoLEP) may be the new 'gold standard'. *Curr Urol Rep.* 2012;13:427-32.
10. Toohar R, Sutherland P, Costello A, Gilling P, Rees G, Maddern G. A systematic review of holmium laser prostatectomy for benign prostatic hyperplasia. *J Urol.* 2004;171:1773-81.
11. Kabalin JN. Holmium: YAG laser prostatectomy canine feasibility study. *Lasers Surg Med.* 1996;18:221-4.
12. Orihuela E, Pow-Sang M, Motamedi M, Cowan DF, Warren MM. Mechanism of healing of the human prostatic urethra following thermal injury. *Urology.* 1996;48:600-8.
13. Olvera-Posada D, Villeda-Sandoval C, Ramirez-Bonilla M, et al. Natural history of pyuria and microhematuria after prostate surgery. *Actas Urol Esp.* 2013;37:625-9.
14. Cho KH, Song KH, Chang YS. Study of the Duration of Pyuria after Transurethral Prostatectomy. *Korean J Urol.* 2007;48:199-205.