

Kimura's Disease Presenting As Scrotal Mass: A Difficult Diagnosis

Deng Piao Xie¹, Yan Fang Xu², Ming Quan Li^{1*}

Keywords: Kimura's disease; scrotal mass.

Herein we report a case of Kimura's disease with unusual manifestations. A 46-year-old Chinese man presented with mass in scrotum which gradually increased in size for approximately 7 years. A computerized tomographic scan of abdomen revealed a soft-tissue density shadow in scrotum and enlargement of lymph nodes in groin and retroperitoneum. The scrotal mass was excised and the biopsy specimen revealed angiolymphoid hyperplasia with infiltration of eosinophils. In conclusion, clinical doctors should pay attention that the patient with eosinophilia and scrotal mass could be indicative for Kimura's disease.

INTRODUCTION

Kimura's disease(KD) is a rare, chronic inflammatory disease of unknown etiology firstly described by Chinese in 1937. KD usually manifests as single or multiple subcutaneous masses, chiefly in the head and neck. Lymph nodes and salivary glands could also be involved. Significant elevation of serum IgE and eosinophils often occurs in KD. The characteristic of biopsy lesions in KD are follicular hyperplasia and reactive germinal centers infiltrated by significant eosinophils. The diagnosis of KD largely depends on the biopsy and manifestations.

CASE REPORT

A 46-year-old Chinese man presented with the mass in scrotum which gradually increased in size for approximately 7 years. Two months ago, the patient was admitted to Nephrology department because of recurrent episodes of edema in legs and complained of scrotal mass enlargement. On physical examination, there was a soft-tissue mass in scrotum about 3x3cm in size. Laboratory results were: white blood cells, 13.6x10⁹/L; eosinophils, 5.58x10⁹/L,(41%); serum IgE,4330IU/ml;serum creatinine,3.6mg/dL. 24-hour urinary protein quantitation was 0.8g. The patient underwent renal biopsy due to kidney failure as well as proteinuria. Re-

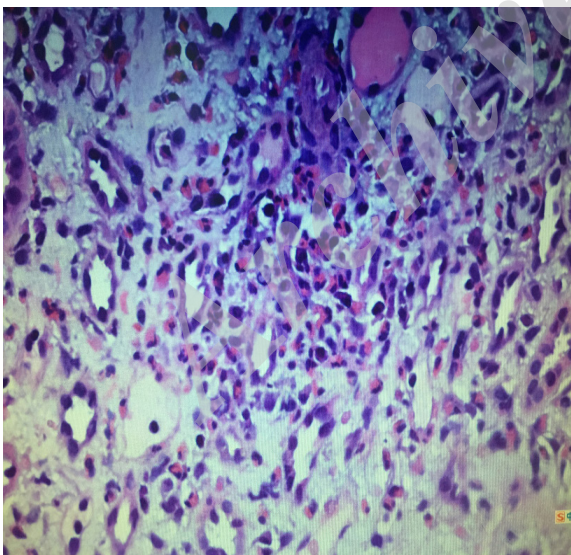


Figure 1. A large of esinophil and some lymphocytes deposit in renal interstitium.

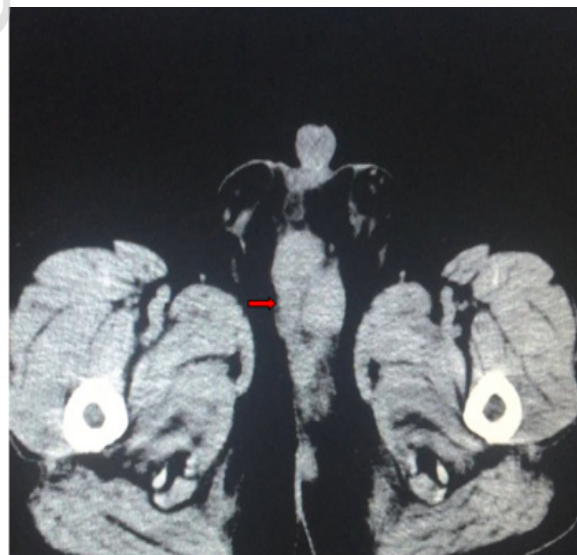


Figure 2. Red arrow points scrotal mass about 5x3.5cm in size.

¹Chengdu University of Traditional Chinese Medicine, Sichuan Province, China.

²Department of Nephrology, First Affiliated Hospital of Fujian Medical University, Fujian Province, China.

*Correspondence: Chengdu University of Traditional Chinese Medicine, Sichuan Province, China.

E-mail: 3511725549@qq.com.

Received September 2017 & Accepted January 2018

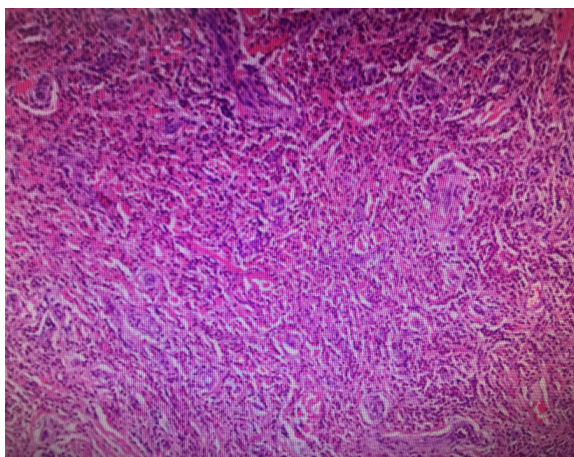


Figure 3. The specimen shows angiolymploid hyperplasia with significant infiltration of eosinophils.

nal biopsy specimen revealed that lots of eosinophils were deposited in renal interstitium (**Figure 1**). A computerized tomographic scan of abdomen revealed a soft-tissue density shadow in scrotum and enlargement of lymph nodes in groin and retroperitoneum (**Figure 2**). Ten days later, the patient was admitted to Urology department, because the patient complained that scrotal mass was larger. Besides, cardiovascular, respiratory and abdominal physical examinations were unremarkable. Laboratory data changed to: white blood cells, $16.3 \times 10^9/L$; eosinophils, $11.78 \times 10^9/L$; (66.1%); serum creatinine, 1.57mg/dL. The scrotal mass was excised and was about 5x3.5x2cm in size. The biopsy specimen revealed angiolymploid hyperplasia with infiltration of eosinophils (**Figure 3**). KD was diagnosed based on the histological features combined with laboratory results.

DISCUSSION

KD is often misdiagnosed because its rarity and this patient was even harder to be correctly diagnosed because the patient was lacking the characteristic symptoms. A retrospective study conducted by Kawada showed that 163 patients had facial involvement in total of 194 cases. Other involved sites included 43 cases in neck, 40 cases in popliteal region, 35 cases in groin, 23 cases in axilla and 2 cases in forearm and male to female ratio was 7:1⁽¹⁾. The patient we reported only had involved scrotum rather than head or neck. Therefore, we speculate that KD might involve any subcutaneous tissues. The patient with KD need to be differentiated from some diseases. The most common disease is angiolymploid hyperplasia with eosinophilia (ALHE), because there are some similar features between these two diseases, including predisposition for involvement of the head and neck, some histopathological features and easy recurrence⁽²⁾. However, there are some characteristics to distinguish KD from ALHE. KD has the following features: male predominance, usually elevated serum IgE and peripheral blood eosinophils > 10% of total white cell count. On the other hand, ALHE has the following features: female predominance, usually normal serum IgE and peripheral blood eosinophils < 10% of total white cell count⁽³⁾. Hodgkin's lymphoma and myeloid leukemia that both can present as eosinophilia should also be differentiated from KD. Hodgkin's lymphoma

and myeloid leukemia can be diagnosed based on the lymph node biopsy and bone marrow biopsy. In this patient, the differential diagnosis should have included common diseases that cause the scrotal mass, including scrotal tumor, tuberculosis of scrotum and inguinal hernia. Both scrotal tumor and tuberculosis of scrotum can be diagnosed based on biopsy. A CT scan of abdomen could diagnose inguinal hernia.

There is no consensus diagnostic criteria for KD. We recommend clinical doctors to consider KD, if patients present with the following characteristics: 1. Young male Asian, 2. Chronic history, 3. Swelling of subcutaneous tissues in head or neck, 4. Lymphadenopathy, 5. Significantly elevated serum eosinophils and Ig E, 6. Histopathological features: the involvement of tissue shows follicular hyperplasia and reactive germinal centers with significant infiltration of eosinophils^(4,5). However, there are some patients who have unusual manifestations. Therefore, if the patient presents with eosinophilia and subcutaneous masses, KD needs to be considered and biopsy should be performed to further confirm the diagnosis.

CONCLUSIONS

Clinical doctors should bear in mind that eosinophilia and scrotal mass could be indicative for KD.

CONFLICT OF INTEREST

The authors have no conflicts of interest to disclose.

REFERENCES

1. Kawada A. Kimura's disease: manifestation of the disease and its differential diagnosis. *Hautarzt*, 1976;27:309-17.
2. Seregard S. Angiolymploid hyperplasia with eosinophilia should not be confused with Kimura's disease. *Acta Ophthalmol Scand* 2001; 79: 91-93.
3. Kung I T M, Gibson J B, Bannatyne P M. Kimura's Disease: A Clinico-Pathological Study Of 21 Cases And Its Distinction From Angiolymploid Hyperplasia With Eosinophils. *Pathology*, 1984, 16:39.
4. Motoi M, Wahid S, Horie Y, Akagi T. Kimura's disease: clinical, histologic and immunohistochemical studies. *Acta Med Okayama* 1992;46:449-55.
5. R P S Punia, R Aulakh, S Garg. Kimura's disease: clinicopathological study of eight cases. *The Journal of Laryngology & Otology*, 2013, 127, 170-4.