

## Voluminous Urethral Stone – A Very Rare Complication After Male Suburethral Sling Surgery As A Result of Sling Erosion Into Proximal Urethra

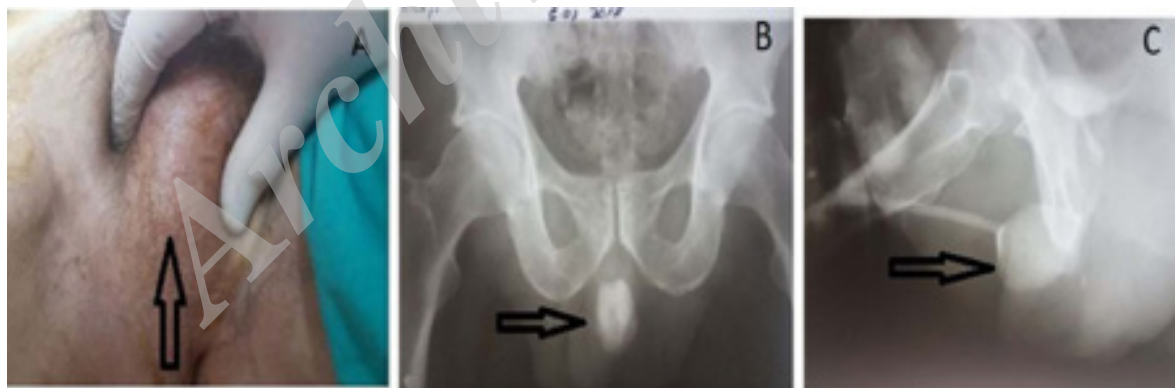Ioan Scarneciu<sup>1,2</sup>, Cristian Andrei<sup>2</sup>, Camelia Scarneciu<sup>1</sup>, Aura-Mihaela Lupu<sup>3</sup>, Ovidiu Gabriel Bratu<sup>4</sup>, Sorin Lupu<sup>2\*</sup>

**Keywords:** male sling; incontinence; sling complications; urethral stone; urethral erosion.

Male sling for urinary incontinence is usually accompanied by very good results, with a small number of complications, but, when appear, they may be redundant. Voluminous urethral stone developed on suburethral sling as a result of sling erosion into the proximal urethra is an extremely rare complication (following the analysis of cases published on the internet, the authors of this article no longer identified another similar case). We present the case of a patient who presented in our clinic for severe and permanent urinary incontinence, perineal discomfort and pain that was influenced by position. His past medical history showed polytrauma with lumbar fracture and medullary involvement (34 years ago) and transobturator suburethral sling surgery for urinary incontinence about 6 years ago in another urology unit, without relieving symptoms. Imaging investigations have showed a voluminous urethral stone developed on polypropylene sling and another small stones in that area. Stones surgical extraction was performed by perineal approach (together with the mesh), proximal urethra was closed after excision to apparently healthy urethral tissue (to prevent possibility of later severe incontinence) and a permanent suprapubic cystostomy catheter was inserted. Patient is dry at follow-up visits (at 1 and 3 months) and he reported significant improvement in quality of life. The case is spectacular due to the rarity of the complication presented, patient developing urethral erosion without clinical manifestations to suggest this matter (infection or fistula), the symptoms being absent for a long time.

### INTRODUCTION

Urinary incontinence after spinal cord injury is a major problem affecting the quality of life of those patients. Patients not responding to drug treatment can benefit from a surgical treatment with inconsistent results<sup>(1)</sup>. Suburethral sling, especially from synthetic materials, is most commonly used in patients with stress urinary incontinence as a complication of radical prostatectomy. As a technical option, this procedure can also be used in patients with urinary incontinence after congenital or acquired neurological lesions, being considered second-line therapy after failure of non-surgical methods<sup>(1,2)</sup>. Although the overall rate of success is appreciated between 50 and 85%, with very low frequency of complications, these interventions can sometimes be followed by redundant complications<sup>(2,3)</sup>.



**Figure 1.** A. Hard and round palpable mass in the perineum. B. Voluminous and round radiopaque image in perineum. C. Voluminous and round radiopaque image in perineum, with urethral involvement.

<sup>1</sup>Faculty of Medicine, "Transilvania" University from Brasov, Brasov, Romania.

<sup>2</sup>Clinic of Urology, Emergency Clinical County Hospital from Brasov, Brasov, Romania.

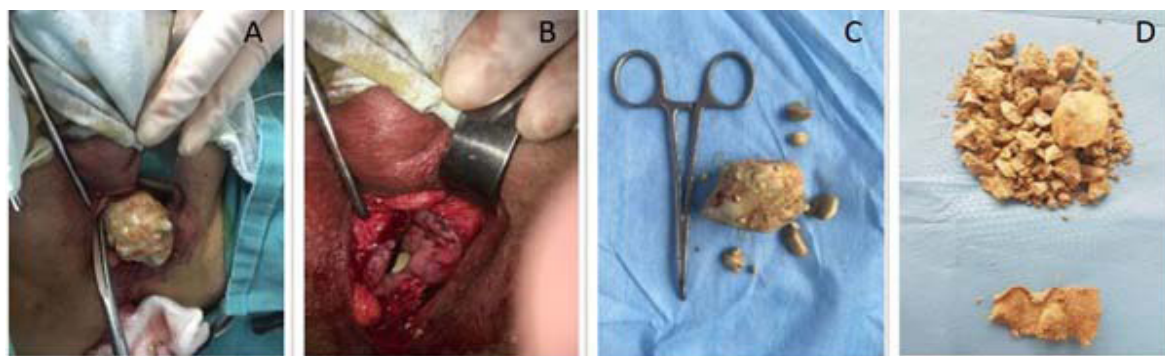
<sup>3</sup>Department of Radiology and Medical Imaging, CFR General Hospital, Brasov, Romania.

<sup>4</sup>Faculty of Medicine, University Of Medicine and Pharmacy "Carol Davila" Bucharest, Romania.

\*Correspondence: Clinic of Urology, Emergency Clinical County Hospital from Brasov, Oltet str., no. 2, Brasov, Romania.

Tel: 0040722988921. Email: so\_lupu@yahoo.com.

Received July 2017 & Accepted February 2018



**Figure 2.** A. Intraoperative aspect - the stone was found after urethral opening. B. The aspect of very dilated urethra, with another pro-found stone. C. Extracted stones. D. Fragmented stones and polypropylene sling from the inside.

## CASE REPORT

A 62-year-old man was admitted to our clinic for permanent and severe urinary incontinence (without urinary retention), permanent perineal discomfort and intermittent perineal pain (especially in the seated position). Symptomatology with an onset of about 6 years and progressive accentuation.

His past medical history showed polytrauma as a result of a fall from a height, with lumbar spinal fracture and medullary involvement (34 years ago). In 2010 he had a transobturator suburethral sling surgery for urinary incontinence, in another unit of urology, without relieving symptoms. In 2011 the patient is discovered with a small calcification in the urethra when he has undergone a cystoscopy (in the same unit of urology were was done sling surgery). No treatment was performed for this condition because the patient refused it in that moment and no other urological control has been performed since then until the presentation in our unit. Careful physical examination revealed a hard and round palpable mass in the perineum, without inflammatory signs, accompanied by discomfort with palpatory sharpening. Pelvic radiography and retrograde urethrocytography showed a voluminous and round radiopaque image in perineum, with urethral involvement (**Figure 1**). Abdominal ultrasound was inconclusive (empty bladder). During the current admission, his laboratory data showed normal values.

Given the degree of urinary incontinence and the marked impact on the quality of life for this patient, after discussing the case in the clinic, definitive suprapubic cystostomy and surgery for removal of the perineal foreign body is considered in order to relieve painful symptoms. After signing the informed consent and adequate pre-operative preparation, surgery was performed. Percutaneous placement of a suprapubic cystostomy was done and an incision was made in the perineum, with wide opening of the urethra. The urethra itself was very dilated due to big stone presence (not urethral diverticula). A urethral stone of about 5 cm and smaller ones were extracted, partial resection of excess urethral wall was performed to apparently healthy urethral tissue (to prevent possibility of later severe incontinence), the proximal orifice of the urethra was closed and sutured with absorbable material and parietal planes were closed. On macroscopic examination we observed that the stones were formed around the polypropylene sling (mesh was inside the big stone and were removed together) (**Figure 2**).

Evolution after surgery was without complications. There was a rapid relieve of perineal pain. The patient was discharged 5 days after surgery with permanent suprapubic catheter. The patient was reviewed at 1 month and 3 months. There have been a significant improvements in the quality of life: absence of perineal pain, without the need to use pads.

## DISCUSSION

The rate of urinary incontinence in men is estimated to be between 12 and 17% in the US population, with increasing prevalence with age<sup>(4)</sup>. Urinary incontinence secondary to spinal trauma is an important topic that causes marked impairment in patient's quality of life. Also, surgery for male urinary incontinence is an extremely important aspect, determined by the large number of patients that remain incontinent due to spinal trauma (increasing the number of accidents) or after urological surgery procedures (after radical prostatectomy or transurethral resection of the prostate)<sup>(1, 2, 5)</sup>. It is estimated that in the US there are more than 250,000 patients with Spinal cord injury and about 80% of them have varying degrees of bladder dysfunction<sup>(1)</sup>. Surgery techniques and materials used for sling surgery are constantly developing. The type of treatment, medical or surgical, must be individualized according to the degree of incontinence, detrusor contractility and urethral compliance of the patient<sup>(3)</sup>.

Commonly used methods for sling surgery in men are suburethral bone-anchored slings (BAS), retourethral transobturator slings (RTS), and adjustable retropubic slings (ARS). Identifying the most effective method is still extremely difficult due to the lack of comparative studies and differences in patient follow-up reportings<sup>(4)</sup>.

Numerous authors published very good and good results, in varying percentages, with the rate of severe complications being below 1%<sup>(3,6,7)</sup>. The lesser results are directly dependent on the surgical technique, but also on associated factors; it is appreciated that history of pelvic radiotherapy or sling surgery could be major risk factors for sling failure<sup>(3)</sup>. It is appreciated that sling procedures are less invasive compared to artificial sphincters. Also, the transobturator tape variant is considered to be safer and accompanied by lower complications compared to the retropubic variant<sup>(8)</sup>.

Although many studies consider to be extremely safe and fast, with excellent results, complications after sling surgery may still exist. The most common compli-

cations are: urinary retention, infectious complications, urethral erosion, scrotal pain or numbness, perineal haematoma, need for sling removal. These are generally dependent by the sling surgery type<sup>(1,2,3,4,9)</sup>.

Except for sling removal, it is estimated that the rest of the complications are transient, appear in a small percentage and disappear after a maximum of 4 months<sup>(4)</sup>. Urethral erosion may occur immediately or subsequent after surgery, being secondary to an unrecognized urethral injury during surgery. The solution consists in sling removal. It is also estimated that perineal pain is almost quasi-conscious in most cases, but it resolves spontaneously within a few months<sup>(4,9)</sup>. However, although it is thought that sling surgery is very easy, fast, almost without complications, there are rare situations where complications are surprising.

In this report we presented a very rare complication case: the development of a voluminous urethral stone and other smaller ones on a suburethral sling after transobturator tape surgery. The case is spectacular due to the fact that the patient developed an urethral erosion without clinical manifestations to suggest this matter, the symptom being absent for a long time. Also, the patient has not developed any obvious fistula or infectious complications over a period of several years, although they would normally have appeared in such a situation. It is strange that the patient did not have the clinical manifestations of a urethral erosion, a possible infection or fistula. Patient presentation was totally atypical, only with perineal discomfort, severe incontinence and the presence of a hard and round palpable mass in the perineum.

The case presented is a particular, exceptional situation, consisting in formation of a voluminous stone on the synthetic material used in sling surgery, by urethral erosion. At least in the studied literature, the authors have never met a case report like this.

Patients undergoing such sling interventions should be advised, particularly with regard to potential complications, as well as the possibility of failure from a functional point of view.

Although male sling surgery is considered relatively simple and with low rate complications, it should not be forgotten that any manoeuvre may be accompanied by complications that may affect the quality of life of the patient.

### CONFLICT OF INTEREST

The authors report no conflict of interest.

### GRANT SUPPORT & FINANCIAL DISCLOSURES

None

### REFERENCES

1. Al Taweel W, Seyam R. Neurogenic bladder in spinal cord injury patients. *Res Rep Urol*. 2015; 7: 85–99.
2. Herschorn S, et al. Com. 13 - Surgical treatment of urinary incontinence in men, "Incontinence", Abrams P, Cardozo L, Khoury S, Wein A (Eds), 4th International Consultation on Incontinence, Paris July 5-8, 2008, 4th Edition 2009, 1121-1190.
3. Comiter CV, Dobberfuhl AD. The artificial urinary sphincter and male sling for postprostatectomy incontinence: Which patient should get which procedure?. *Investig Clin Urol*. 2016 ; 57: 3–13.
4. Landon Trost, Daniel S. Elliott. Male Stress Urinary Incontinence: A Review of Surgical Treatment Options and Outcomes. *Advances in Urology*, 2012, 13: 2012.
5. Markland AD, Richter HE, Fwu CW, Eggers P, Kusek JW. Prevalence and trends of urinary incontinence in adults in the United States, 2001 to 2008. *J Urol*, 2011;186 : 589–93.
6. Welk BK, Herschorn S. The male sling for post-prostatectomy urinary incontinence: a review of contemporary sling designs and outcomes. *BJU Int* 2012;109:328-44.
7. Kretschmer A, Buchner A, Leitl B, et al. Long-term outcome of the retrourethral transobturator male sling after transurethral resection of the prostate. *Int Neurourol J*. 2016;20:335-341.
8. Siracusano S, Visalli F, Toffoli L. Male incontinence and the transobturator approach: An analysis of current outcomes. *Arab Journal of Urology* (2013) 11, 331–5.
9. Cornel EB, Elzevier HW, Putter H. Can advance transobturator sling suspension cure male urinary postoperative stress incontinence? *J Urol* 2010;183:1459.