

The Protective Effects of Pulsed Magnetic Field and Melatonin on Testis Torsion and Detorsion Induced Rats Indicated by Scintigraphy, Positron Emission Tomography/Computed Tomography and Histopathological Methods

Serdar Savas Gül^{1*}, Serkan Gürgül², Murat Uysal³, Fikret Erdemir⁴

Purpose: The aim of the present study was to show the protective effect of pulsed magnetic field (PMF) application and melatonin administration on damage in testis in a one-sided torsion detorsion induced rat model using testicular scintigraphy with ^{99m}Tc pertechnetate, PET/CT with ¹⁸F-FDG and histopathological methods.

Materials and Methods: Sixty male rats were used in the study; 30 rats were randomly divided into five groups for one day applications of sham control, torsion, melatonin, pulsed magnetic field (PMF) and melatonin plus PMF. Similarly, the other 30 rats were divided into the same five groups (n = 6) for one week treatment, but the animals were sacrificed after one week. Rats were exposed to 50 Hz, 1 mT PMF for two hours. PET/CT with 37 MBq ¹⁸F-FDG and testicular scintigraphy with and 37 MBq ^{99m}Tc pertechnetate examinations were carried out, and testicular tissue was examined using histopathological methods.

Results: In one day treatment, melatonin administration significantly increased perfusion and glucose metabolism compared to torsion group ($P < 0.01$). Perfusion and glucose metabolism was also higher in the PMF and melatonin plus PMF groups than torsion group ($P < 0.01$). In one week treatment, melatonin administration resulted in a significantly higher perfusion and glucose metabolism rates compared to torsion group ($P < 0.01$ and $P < 0.001$, respectively). In addition, perfusion and glucose metabolism significantly increased in PMF and melatonin plus PMF groups compared to torsion group ($P < 0.01$ and $P < 0.001$, respectively). Furthermore, caspase-3 immunoreactivity and pathological changes increased in the torsion group ($P < 0.05$). Melatonin and melatonin plus PMF treatment reduced the rate of immunoreactivity and pathological findings compared to the torsion group ($P < 0.05$).

Conclusion: According to these results it can be concluded that PMF application has a therapeutic benefit as effective as melatonin administering. In addition, it was indicated that PET/CT with ¹⁸F-FDG and testicular scintigraphy with ^{99m}Tc pertechnetate could be efficiently used in determining the treatment efficiency in testicular torsion.

Keywords: positron emission tomography/computed tomography; pulsed magnetic field; scintigraphy; testis torsion

INTRODUCTION

Testis torsion is a surgical condition with acute onset especially in childhood and young adolescent men, and it needs to be diagnosed and treated. It refers to inhibition of blood flow into testis and associated structures depending upon twisting of spermatic cord around its axis. It has an incidence rate of 1/4,000 in men younger than 25 years of age.⁽¹⁾ The main treatment in testis torsion is manual or surgical detorsion of testis. Even with successful intervention, testis atrophy and infertility develops in 40–60% of these patients.⁽²⁾ The major pathology after testis torsion is testis ischemia. In testis where developed torsion was detorsioned, injury continues after reperfusion. At start, ischemic damage occurs in testis, and during restoration of blood flow reperfusion damage may also occur.⁽³⁾ Free oxygen radicals that formed during reperfusion

causes testis injury.⁽⁴⁾ The main damage of free oxygen radicals to testis is in the form of cell viability loss through lipid peroxidation and break of membrane integrity.⁽⁵⁾ Since sperms have high levels of unsaturated fatty acids in their plasma membranes, they are highly sensitive to oxidative stress and especially to lipid peroxidation. Accordingly, loss of sperm motility due to negative effect of free oxygen radicals on sperms via this mechanism, especially adenosine triphosphate loss within cell and axoneme damage, loss of sperm viability and morphological changes impairs sperm capacity and acrosome reaction.^(6,7) Many studies in literature established torsion models and investigated histological changes in serum and tissue levels. Antioxidants were also extensively studied for treatment purposes. It is known that antioxidants act in a way to counterbalance the effect of free oxygen radicals and block their negative effects. Many antioxidant agents, mainly

¹Gaziosmanpasa University, Faculty of Medicine, Department of Nuclear Medicine, Tokat 60100, Turkey.

²Gaziantep University, Faculty of Medicine, Department of Biophysics, Gaziantep 27000, Turkey.

³Gaziosmanpasa University, Faculty of Medicine, Department of Anatomy, Tokat 60100, Turkey.

⁴Gaziosmanpasa University, Faculty of Medicine, Department of Urology, Tokat 60100, Turkey.

*Correspondence: Gaziosmanpasa University, Faculty of Medicine, Department of Nuclear Medicine, Tokat 60100, Turkey.

Tel: +90 356 2120045, Fax: +90 356 2120045, E-mail: gopnukleertip@gmail.com.

Received February 2018 & Accepted May 2018

Table 1. Statistical data to left/right testis ratio from one day treatment groups (Abbreviations: PMF, pulsed magnetic field). One-way ANOVA test was used for comparing groups. ‡ $p < 0.01$, * $p < 0.001$ and € $p < 0.01$ compared with torsion.

	One Day Groups	N	Mean	Std. Deviation	Std. Error
18F FDG glucose metabolism	Sham	6	0.998‡	0.024	0.010
	Torsion	6	0.754	0.075	0.030
	Melatonin	6	1.088‡	0.085	0.034
	PMF	6	1.065‡	0.107	0.044
	Melatonin plus PMF	6	1.142‡	0.153	0.062
	Total	30	1.009	0.165	0.030
99mTc Perchnetate testicular perfusion	Sham	6	1.001*	0.051	0.020
	Torsion	6	0.750	0.054	0.022
	Melatonin	6	1.171€	0.116	0.047
	PMF	6	1.311€	0.317	0.129
	Melatonin plus PMF	6	1.175€	0.159	0.065
	Total	30	1.082	0.252	0.046

latonin, have been used to treat the oxidative damage from free oxygen radicals.⁽⁸⁻¹⁰⁾

Despite these classical studies, magnetic field application was not investigated in testis torsion and, except for diagnostic purposes, nuclear medicine imaging methods were not commonly used to determine the changes and efficiency of treatments using the same parameters. The aim of the present study was to evaluate the protective effect of pulsed magnetic field (PMF) and melatonin applications on damage during and after one sided testis torsion using positron emission tomography/computed tomography (PET/CT) with (18) Flour fluoro-2-deoxy-D-glucose (18F-FDG) examination, testicular scintigraphy with (99m) Technesium (99mTc) pertechnetate and histopathological methods.

MATERIALS AND METODS

This study was conducted with permission of the Local Ethics Committee (2014 HADYEK-50). All experiments and protocols described in the present study were performed in accordance with the Guide for the Care and Use of Laboratory Animals, as adopted by National Institutes of Health (U.S.). All procedures were approved by the Medical Faculty Experimentation Ethics Committee of Gaziosmanpaşa University.

Study Population

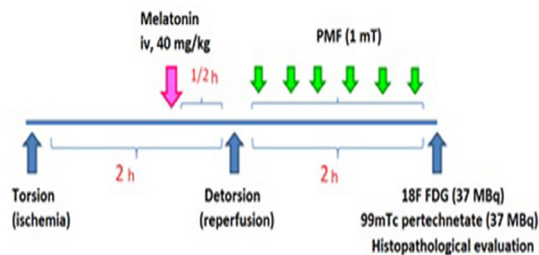
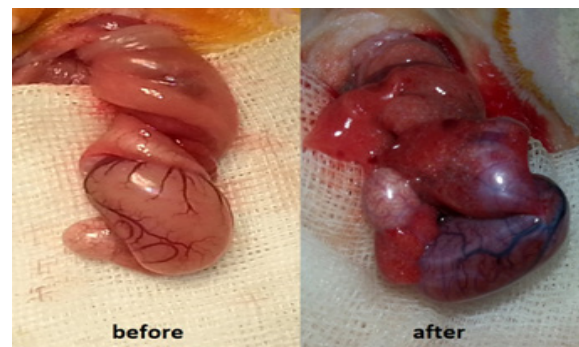
Sixty male Wistar-Albino rats, 90 days of age and weighing 200–250 g each, were used in this study. The

rats were raised under a 12h light/12h dark cycle (light from 07:00 to 19:00) in quiet rooms with 22–24°C ambient temperature and they had free access to standard rat nutrients and purified drinking water ad libitum. For one day treatment groups, 30 rats were divided into five groups; sham control, torsion, melatonin, PMF and melatonin plus PMF. Similarly, for one week group, other 30 rats were divided into the same five groups (n = 6). In sham control group, testes were taken out via scrotal cutting, put back without any other procedure, and the skin was appropriately closed. In torsion group, no treatment was carried out after torsion procedure. After the experiment, rats were sacrificed using intraperitoneal administration of high dose pentobarbital (100 mg/kg).

Procedures

Testis Torsion and Detorsion

In the day of experiment, rats were taken to operation room. After anesthesia using intraperitoneal administration of 50 mg/kg ketamine (Ketalar®, Parke-Davis) and 10 mg/kg xylazine (Alfazyne®, Alfasan), rats were stabilized in operation table. For rats which would be subjected to torsion, detorsion and sham operations, standard scrotal incision was realized after local anesthesia application to left side ilioinguinal area carried out using (2% Citanest®, Astra Zeneca). In all groups, left testis was taken out after scrotal incision. In testis torsion groups, torsion was carried out via twisting left

**Figure 1.** Schematic representation of work plan (Abbreviations: PMF, pulsed magnetic field; 99mTc, (99m)Technesium; 18F FDG, (18)Flour fluoro-2-deoxy-D-glucose).**Figure 2.** Testis torsion and detorsion model images.

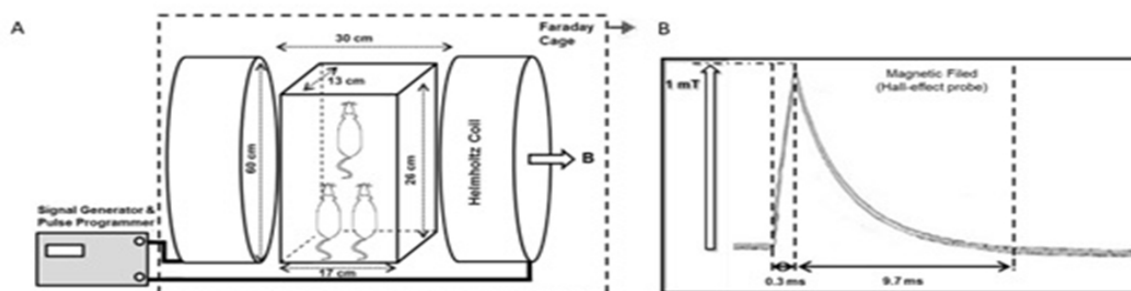


Figure 3. A) Schematic drawing of PMF exposure system. B) Magnetic field amplitude with Hall-effect probe.

testis 720° clockwise. In order to maintain the torsion, testis was fixed to scrotum at tunica albuginea via silk suture after twisting. After the operation, incision was closed. After two hours of torsion, left testis was detorsioned. Then, tissues were closed appropriately. All details about the study were shown in **Figure 1**. Testis torsion and detorsion model was shown in **Figure 2**.

Melatonin Treatment

In one day melatonin group, a single dose of 40 mg/kg melatonin was administered intravenously, while in one week melatonin group a daily 40 mg/kg of melatonin was administered intravenously.

PMF Application Protocol

Before PMF application, rats were acclimated to their environment for a week. Habituation to the treatment conditions was accomplished by placing the rats in a restrainer at least three times for 30 min. PMF was conditioned using Helmholtz coil apparatus in a earthed shielded Faraday cage (90x90x55 cm³) (Figure 3A). Coils of 60 cm diameter and 30 cm clearance were constructed by electrically and thermally insulated copper wire of 2.5 mm diameter with 50 turns. Resistance was 0.78 Ω and inductance was 8.8 mH. Coils were connected to a signal generator (ILFA Electronic Ltd., Adana, Turkey) to produce magnetic field with a peak amplitude of 1 mT. The peak value of the magnetic field was measured using a gaussmeter equipped with a Hall-effect probe (FW Bell 5180, Pacific Scientific OECO, Milwaukie, OR) (Figure 3B). The time-varying magnetic field consisted of quasi-triangular waveform, a rise time of 0.3 ms and a fall time of 9.7 ms. The maximum induced electrical field between the coils was 0.25 V/m calculated based on Faraday's law. After two-

hour testis torsion and detorsion, rats were placed in a 26x17x13 cm restrainer and housed in the center of the Helmholtz coils. The horizontal, uniform, and homogeneous PMF (1 mT; 15 Hz) was applied. Rats (F-MF; M-MF) were then exposed to a horizontal and sinusoidal MF (50Hz, 1mT) for two hours, while the control rats (FC; MC) were kept at the same laboratory conditions as intact groups. The ambient geomagnetic field was recorded as 50 μT. No significant temperature change was detected during the experiments between two activated Helmholtz coils. The temperature (20–22 °C) and humidity (40–60%) were monitored continuously throughout the experiment. All PMF applications were carried out at the same hours of the day (9:00–11:00 a.m.). Sham treatment was performed under the same environmental conditions using another apparatus including only Helmholtz coils in a Faraday cage. The polycarbonate cages were cleaned after every test session to avoid any biochemical effects. After two hours of PMF exposure, scintigraphic evaluation was made on rats. PMF application was carried out by two investigators (SG and MU) who were unaware of the study groups.

Nuclear Medicine Imaging

All groups had testicular perfusion imaging using ^{99m}Tc pertechnetate testicular scintigraphy and glucose metab-

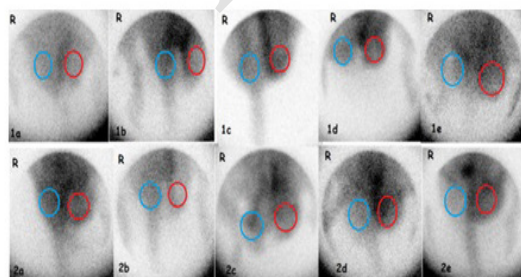


Figure 4. Testicular scintigraphy using ^{99m}Tc pertechnetate; one day sham control (1a), torsion (1b), melatonin (1c), PMF (1d), melatonin plus PMF (1e), and one week sham control (2a), torsion (2b), melatonin (2c), PMF (2d), melatonin plus PMF (2e).

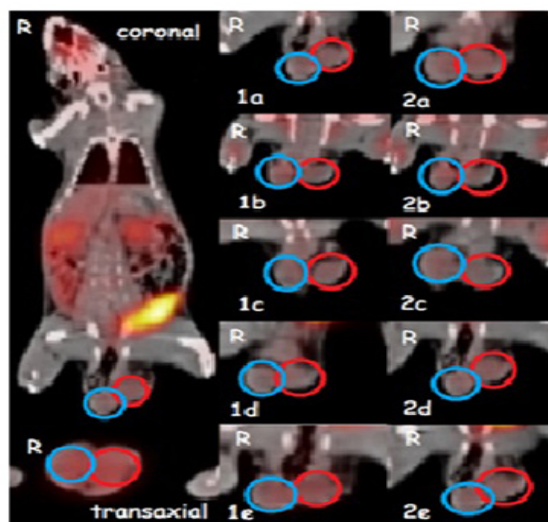


Figure 5. Examination of glucose metabolism using PET/CT with ¹⁸F-FDG; one day sham control (1a), torsion (1b), melatonin (1c), PMF (1d), melatonin plus PMF (1e), and one week sham control (2a), torsion (2b), melatonin (2c), PMF (2d), melatonin plus PMF (2e).

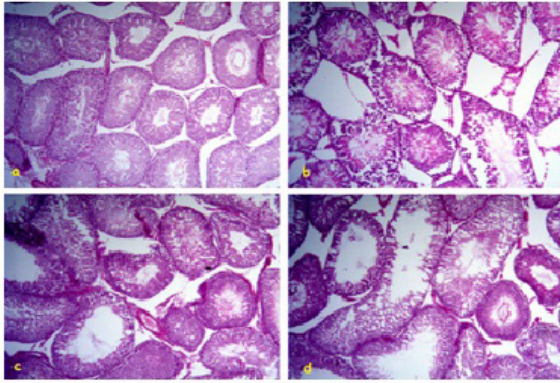


Figure 6. Microscope images of hematoxylin eosin stained tissues in one day sham control (a), torsion (b), melatonin (c) and pulsed magnetic field (d) groups

olism imaging using PET/CT with 18F-FDG. 18F-FDG PET/CT was performed to assess glucose metabolism in bilateral testes. Rats received intravenous injections of 1 mCi (37 MBq) of FDG 1 hour before the acquisition of the PET/CT image. PET imaging was performed using a combined PET/CT scanner (Siemens Biograph 2 PET/CT, New Jersey, USA). Attenuation correction of PET images with the CT data was performed. Right after CT data acquisition, a standard PET imaging protocol was taken from the cranium to the mid-thigh with an acquisition time of 3 min/bed in 3-dimensional mode. CT and PET images were matched and fused into transaxial, coronal and sagittal images.

The testicular scintigraphy was performed with intravenous injection of 1 mCi (37 MBq) of ^{99m}Tc pertechnetate. The perfusion phase (5 second/frame, for 2 minutes) and static imaging (5 minute anterior view, immediately after dynamic imaging) using a dual head variable angle nuclear gamma camera (Symbia Siemens, Hoffman Estates, USA) equipped with a low energy high resolution collimator and 140 keV ^{99m}Tc photopeak) demonstrated arterial flow in the bilateral testes. Images obtained were evaluated. Region of interest (ROI) were drawn in both testis regions after imaging and left/right testis activity rates were determined using semi-quantitative method. Image analysis was carried out by a researcher (SSG) who was not informed about the source of the images.

Histopathological Examination

During the torsion period, color changes due to edema

and venous stasis which were macroscopic results of ischemia were observed in all testes to which surgical procedure was applied. Histopathological evaluations carried on tissue samples were recorded in forms prepared to this aim. There were normal distributions among all groups. Left and right testis tissues in all groups were studied for glucose metabolism and perfusion. In addition, histopathological evaluations were carried out.

Testis tissue samples were taken and submersed in 10% formaldehyde solution. These tissues underwent routine histological procedures and were embedded in paraffin. Five and twenty-five micron dissections were taken from these paraffin embedded tissues using rotary microtome. Histopathological evaluations were carried out after hematoxylin eosin staining of testis tissue samples. Numbers of spermatogonium and spermatocyte, and volume and diameter of seminiferous tubules were determined. In addition, the Johnsen score was used to evaluate the morphological damage of testis tissue as a result of testis torsion. Johnsen score was determined and damage in seminiferous tubules was assessed for the purpose of evaluation of spermatogenesis. The Johnsen scoring system is principally based on the progressive degeneration of germinal epithelium and a successive loss of the most mature cell types during testicular damage evaluated using the following categories: 1 (No cells at all within the tubules), 2 (No germinal cells, only Sertoli cells), 3 (Only spermatogonia), 4 (No spermatozoa and spermatids, less than 5 spermatocytes, but numerous spermatogonia per cross-section), 5 (No spermatozoa and spermatids, numerous spermatocytes and spermatogonia), 6 (No spermatozoa, 5 ± 20 spermatids, numerous spermatocytes and spermatogonia per cross-section), 7 (No spermatozoa, numerous spermatids, spermatocytes and spermatogonia), 8 (Less than 5 ± 10 spermatozoa per tubular cross-section), 9 (Numerous spermatozoa, germinal epithelium disorganized with sequestration of germinal cells, tubular lumen was obturated) and 10 (Complete spermatogenesis, numerous spermatozoa, germinal epithelium of regular height, tubular lumen of normal diameter).⁽¹¹⁾ Finally, H-score of caspase-3, an enzyme active in apoptosis, was carried out immunohistochemically to determine the level of this enzyme.⁽¹²⁾ Evaluation of the immunohistochemical labeling was performed using H-Score analyses as previously described. Caspase3 immunoreactivities were semi-quantitatively evaluated using the following categories: 0 (no staining), 1+ (weak but detectable staining), 2+ (moderate or distinct staining),

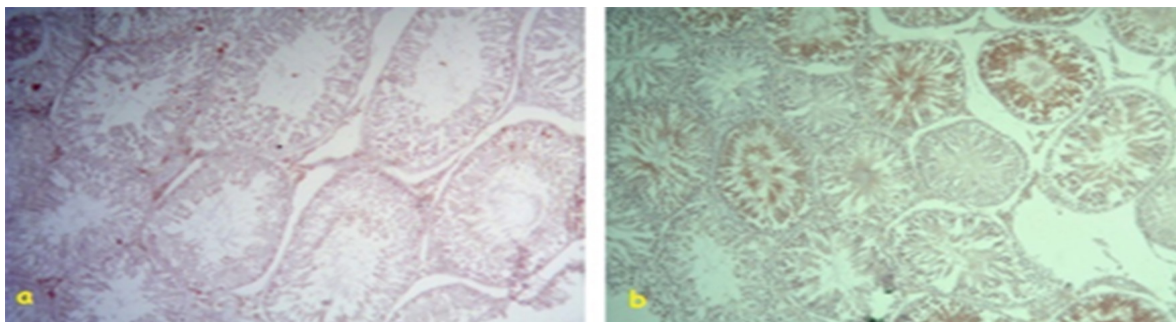
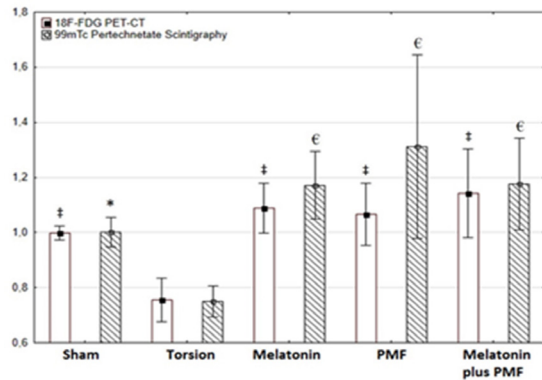
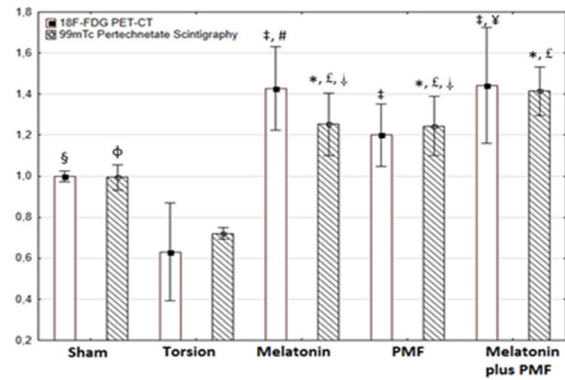


Figure 7. Microscope images of caspase-3 stained tissues in one day sham control (a) and torsion (b) groups.



Graphic 1. Comparison of the results from one day treatment groups (Abbreviations: PMF, pulsed magnetic field). One-way ANOVA test was used for comparing groups. ‡*p* < 0.01, **p* < 0.001 and €*p* < 0.01 compared with torsion.



Graphic 2. Comparison of the results from one week treatment groups (Abbreviations: PMF, pulsed magnetic field). One-way ANOVA test was used for comparing groups. §*p* < 0.05, ‡*p* < 0.01, φ*p* < 0.01 and **p* < 0.001 compared with torsion; #*p* < 0.01, ¥*p* < 0.05 and £*p* < 0.01 compared with sham; †*p* < 0.01 compared with melatonin plus PMF.

and 3+ (intense staining). For each tissue, an H-score value was derived as follows: First, the sum of the percentages of cells that stained at each intensity category was calculated, which was then multiplied by the weighted intensity of the staining using the formula as follows: $H\text{-score} = \sum P_i (i+1)$. In this formula, 'i' represents the intensity scores, and 'Pi' is the corresponding percentage of the cells. Five randomly selected areas were evaluated under a light microscope on each slide (40x objective). Two investigators (MU and SSG), who were not informed about the type and source of the tissues, determined the percentage of cells at each intensity within these areas at different times. The combined average score of both observers was used.

Statistical Analysis

All data were analyzed by IBM SPSS Statistical Software version 18.0. The normal distribution of data and the homogeneity of variance were evaluated using the Kolmogorov Smirnov test and the Levene test, respectively. Because of the normal distribution in the study groups, One-way ANOVA test was used for comparing groups in terms of glucose metabolism, testicular perfusion, Johnsen score and H-score values, and Tukey test was used as post-hoc test. Results of the experiments were given as mean ± standard deviation and *P* < 0.05

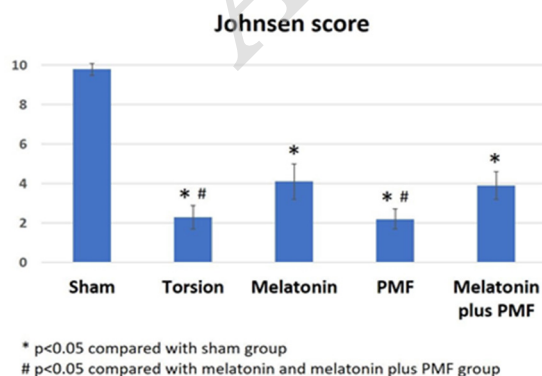
was considered statistically significant.

RESULTS

A. One-day Groups

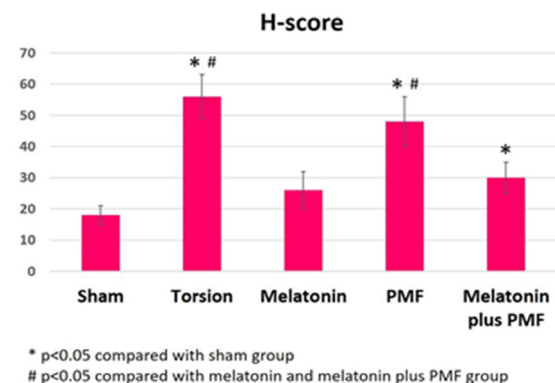
Evaluation of “left testis/right testis” perfusion with testicular scintigraphy using 99mTc pertechnetate Findings of testicular scintigraphy in different groups were shown in **Table 1** and Graphic 1. There was a significant decrease in perfusion based on scintigraphy between torsion and sham groups (*P* < 0.001). Perfusion of left testis was significantly impaired compared with the right one. Melatonin, PMF and melatonin plus PMF application significantly increased the perfusion compared with that in the torsion group (*P* < 0.01), but this increase was more prominent in the PMF group. When compared with the sham group, it was apparent that melatonin, PMF and melatonin plus PMF groups had an increase in perfusion, but these differences were not statistically significant (*P* = .08, *P* = .09 and *P* = .09, respectively). Images from one day treatment were given in **Figure 4**.

Evaluation of “left testis/right testis” glucose metabolism with PET/CT using 18F-FDG Results of PET/CT in different groups were shown in **Table 1** and **Graphic 1**. A significant decrease was



* *p* < 0.05 compared with sham group
p < 0.05 compared with melatonin and melatonin plus PMF group

Graphic 3. Comparison of one day treatment groups using Johnsen score after histopathological examination (Abbreviations: PMF, pulsed magnetic field). One-way ANOVA test was used for comparing groups.



* *p* < 0.05 compared with sham group
p < 0.05 compared with melatonin and melatonin plus PMF group

Graphic 4. Comparison of one day treatment groups using H-score after histopathological examination (Abbreviations: PMF, pulsed magnetic field). One-way ANOVA test was used for comparing groups.

Table 2. Statistical data to left/right testis ratio from one-week treatment groups (Abbreviations: PMF, pulsed magnetic field). One-way ANOVA test was used for comparing groups. [§] $p < 0.05$, [‡] $p < 0.01$, [¶] $p < 0.01$ and ^{*} $p < 0.001$ compared with torsion; [#] $p < 0.01$, [¥] $p < 0.05$ and [£] $p < 0.01$ compared with sham; [‡] $p < 0.01$ compared with melatonin plus PMF.

One Week Groups		N	Mean	Std. Deviation	Std. Error
18F FDG glucose metabolism	Sham	6	0.997 [§]	0.252	0.103
	Torsion	6	0.630	0.193	0.079
	Melatonin	6	1.442 ^{‡, #}	0.144	0.059
	PMF	6	1.199 [‡]	0.270	0.110
	Melatonin plus PMF	6	1.427 ^{‡, ¥}	0.228	0.093
	Total	30	1.139	0.355	0.640
99mTc Perchnetate testicular perfusion	Sham	6	0.994 [¶]	0.059	0.024
	Torsion	6	0.724	0.143	0.058
	Melatonin	6	1.245 ^{*, £, ‡}	0.135	0.055
	PMF	6	1.254 ^{*, £, ‡}	0.114	0.046
	Melatonin plus PMF	6	1.413 ^{*, £}	0.026	0.010
	Total	30	1.126	0.264	0.048

detected between torsion and sham groups in glucose metabolism assay using 18F-FDG PET/CT ($P < 0.01$). It was revealed there was a decrease in glucose metabolism of left testis compared with the right one after one day treatment period and the difference was significant ($P < 0.01$). Glucose metabolism was significantly higher in melatonin, PMF and melatonin plus PMF groups than in torsion group ($P < 0.01$), but this increase was more prominent in the melatonin plus PMF group. There was no significant difference among melatonin, PMF, melatonin plus PMF and sham groups for glucose metabolism. PET/CT images from one day treatment were given in **Figure 5**.

B. One Week Treatment Groups

Evaluation of "left testis/right testis" perfusion with testicular scintigraphy using 99mTc pertechnetate Findings of testicular scintigraphy in different groups were shown in **Table 2** and **Graphic 2**. A significant decrease was observed in perfusion based on scintigraphic method between torsion and sham groups ($P < 0.01$). Perfusion rates in melatonin, PMF and melatonin plus PMF groups, on the other hand, were significantly higher than that in torsion group ($P < 0.001$). Melatonin, PMF and melatonin plus PMF application eliminated the perfusion loss and led to a significant increase in perfusion ($P < 0.01$). Additionally, melatonin plus PMF group had perfusion increase compared with the melatonin and PMF groups ($P < 0.01$). Evaluation of "left testis/right testis" glucose metabolism with PET/CT using 18F-FDG Results of PET/CT in different groups were shown

in **Table 2** and **Graphic 2**. A significant decrease was determined in glucose metabolism via PET/CT using 18F-FDG between torsion and sham groups ($P < 0.05$). After one week of treatment period, left testis metabolism was shown to be significantly lower than right testis metabolism. Glucose metabolism in melatonin, PMF and melatonin plus PMF groups was significantly higher than that in torsion group ($P < 0.01$), but this increase was more prominent in the melatonin and melatonin plus PMF groups. When compared with the sham group, it was apparent that melatonin and melatonin plus PMF groups had a significant increase in glucose metabolism ($P < 0.01$ and $P < 0.05$, respectively).

Histological and immunohistochemical results were presented in **Table 3**. Histopathological analyses using hematoxylin eosin staining of one day treatment group revealed that cell damage was more prominent in torsion group compared to sham group and melatonin plus PMF group ($P < 0.05$) (**Figure 6**). Caspase-3 staining showed a higher level of apoptosis in torsion group than in sham group ($P < 0.05$) (**Figure 7**). Johnsen score indicated the cell damage in testis tissue. Johnsen score was 9.6 for sham group 2.2 for torsion group, 4.0 for melatonin group, 2.1 for PMF group and 3.9 for melatonin plus PMF group (**Graphic 3**). H-score indicated the cell damage in testis tissue. H-score was 18 for sham group, 56 for torsion group, 24 for melatonin group, 49 for PMF group and 30 for melatonin plus PMF group (**Graphic 4**).

DISCUSSION

Table 3. Statistical data to Johnsen score and H-score from one day treatment groups (Abbreviations: PMF, pulsed magnetic field). One-way ANOVA test was used for comparing groups. ^{*} $p < 0.05$ compared with sham group; [#] $p < 0.05$ compared with melatonin and melatonin plus PMF group.

Groups		N	Mean	Std. Deviation
Johnsen score	Sham	6	9.8	0.3
	Torsion	6	2.3 ^{*, #}	0.6
	Melatonin	6	4.1 [*]	0.9
	PMF	6	2.2 ^{*, #}	0.5
	Melatonin plus PMF	6	3.9 [*]	0.7
	Total	30	4.5	0.6
H-score	Sham	6	18	3
	Torsion	6	56 ^{*, #}	7
	Melatonin	6	26	6
	PMF	6	48 ^{*, #}	8
	Melatonin plus PMF	6	30 [*]	5
	Total	30	36	6

Testis torsion is known as ischemia-reperfusion damage in clinical practice. The diagnosis and treatment of testis torsion is critical for the maintaining of fertility since inappropriate treatments could lead to male infertility. Experimental testis torsion lowers blood flow without causing a significant change in central blood pressure, and it results in impairment of apoptosis, testicular atrophy and spermatogenesis in germ cells.⁽¹³⁾ Following a torsion of more than four hours, blood flow in ipsilateral testis could not be completely restored even 24 hours after detorsion.⁽¹⁴⁾ During ischemia, germ cell death takes place due to low level of oxygen to meet metabolic needs, cellular energy stores are depleted, and toxic metabolites accumulate.⁽¹⁵⁾ Experimental studies revealed that testis necrosis develop within two hours in arterial blocking and within six hours in venous blocking.⁽¹⁶⁾ The testes which are not treated within 12 hours after the development of symptoms could be lost.⁽¹⁷⁾

The aim in the present study was to create an acceptable ischemia in torsioned testes before a treatment. In addition, torsion and the experiment had to be ended before irreversible damage occurred in testes. Therefore, duration of ischemia was two hours. Experimental studies showed that ischemic damage occurred as a result of testis torsion and was associated with number and duration of torsion. In addition, it was also shown that blood flow ceased irreversibly in 720° torsion of testes and a complete ischemia developed. Nevertheless, experimental studies generally use testis torsion angles between 360° and 720°. In addition, left testis torsion is more commonly encountered since left testis has a longer spermatic cord than that of right testis.⁽¹⁸⁾ Therefore, a 720° torsion-detorsion model of left testis was used in the present study.

Oxidant and antioxidant mechanisms are in a balance state in body, and break down of this balance in favor of oxidant mechanisms result in tissue damage.⁽¹⁹⁾ In the case of a torsion, detorsion is classical way of treatment, but detorsion is known to cause a more comprehensive damage in testis through oxidative damage due to reperfusion. As a result of reperfusion of ischemic tissue, toxic free oxygen radicals such as nitric oxide, superoxide anions, hydrogen peroxide and hydroxyl radical form.⁽²⁰⁾ Free oxygen radicals are short half-life chemical compounds and they consist of one or more uncoupled electrons, which render them to be unstable and quite reactive.⁽²¹⁾ In order to be stable, free oxygen radicals attack lipids, amino acids and nucleic acids. Although in normal conditions free oxygen radicals play roles in cell differentiation, sperm capacitation, acrosome reaction and maintaining the fertility, their high levels due to various stresses negatively affect cells. Protein, carbohydrate, nucleic acid and lipid components of cells are potential targets of free oxygen radicals. As a result of their impact on abovementioned cell components, free oxygen radicals that increase as secondary to oxidative damage leads to negative consequences such as inflammation, apoptosis, breakdown of cell membrane integrity, fibrosis and proliferation. It has been reported in literature that oxidative damage play role in pathogenesis of arthritis, cancer, diabetes mellitus, carious infections, central nervous system diseases, cardiac diseases and testis torsion.⁽²²⁻²⁶⁾

Testis torsion model has shown that oxidative damage occurs within hours or even within minutes following the perfusion. It has also been revealed in these models that levels of antioxidant enzymes decreased while

free oxygen radicals increased.⁽²⁷⁾ Free oxygen radicals formed during testicular reperfusion activate leucocytes and cause them to adhere to vein endothelium, consequently impairing blood circulation. Lack of restoration of perfusion in some of capillaries after ischemia/reperfusion is called no-reflow phenomenon.⁽²⁸⁾ Similarly, we established ischemia/reperfusion in the present study and examined testis perfusion and glucose metabolism.

Testicular torsion-detorsion generates ROS that cause apoptosis, resulting in lipid peroxidation and metabolic alterations. It is known that the formation of intracellular ROS or the depletion of cellular antioxidants may result in apoptosis.⁽²⁹⁾ Apoptosis is a form of programmed cell death characterized by DNA fragmentation, cytoplasmic shrinkage, membrane changes, and cell death without damage to neighboring cells. Caspase-3, also known as the primary executioner caspase, is responsible for morphological changes of apoptosis.⁽³⁰⁾ The ischemia/reperfusion (I/R) phenomenon occurs in testicular torsion-detorsion in which torsion comprises the ischemic period, whereas detorsion comprises reperfusion injury.⁽¹⁰⁾ In particular, reperfusion injury results in anoxia, leading to the generation of large quantities of ROS, pro-inflammatory cytokines and lipid peroxidation, followed by activation of the apoptosis pathway which causes even severe ischemic tissue damage.⁽³¹⁾ In our study, it was observed that caspase-3 activities increased significantly in testis of rats subjected to testicular torsion-detorsion. It was found that this increase aggravated testicular damage. It was also noticed that melatonin, PMF and melatonin plus PMF application significantly increased the perfusion compared with that in the torsion group. Therefore, reperfusion injury resulting in an increase in perfusion may be the main reason why melatonin and PMF treatments did not show a significant effect in terms of apoptosis. In addition, it supports our assumption that melatonin is more successful than PMF against apoptosis that occurs in the oxidative damage caused by reperfusion injury. As we have shown in this study, the antioxidant effect of melatonin may have demonstrated a better improvement in apoptosis, possibly by showing more protective efficacy than PMF against increased oxidative damage after reperfusion.

It is well known that the general approach to decrease or eliminate the effects of free oxygen radicals occurring as secondary to oxidative damage is the use of antioxidants. In this context, effects of antioxidants on some pathologies in various tissues such as atherosclerosis, hypertension, diabetes mellitus, renal disease, ulcerative colitis, chronic obstructive pulmonary disease and testis torsion were investigated. For this purpose, vitamin E, melatonin, retinol, β -carotene, omega-3, resveratrol, allopurinol, N-acetylcystein, zinc, caffeic acid, vitamin C, coenzyme Q10 and melatonin were used as antioxidant agents in various studies.⁽³²⁻³⁵⁾

Melatonin is known as the strongest antioxidant agent to reduce testicular damage after testis torsion. Melatonin is produced in pituitary gland with a circadian rhythm. It has been shown to have an antioxidant effect both directly by eliminating free oxygen radicals and indirectly by elevating the level of antioxidant enzymes. In addition, melatonin has an inhibitory effect on nitric oxide synthesis. Melatonin has been reported to prevent lipid peroxidation in many organs and tissues, not only in testes, and to protect against the effect of oxidative

damage.⁽²⁷⁾ In this context, Erdemir et al. studied the effect of melatonin on antioxidants in systemic circulation after one sided testis torsion in rats. They administered 50 mg/kg melatonin to a group rats after 720° of torsion for two hours and measured blood levels of malondialdehyde, superoxide dismutase, protein carbonyl and nitric oxide in rats. Their results showed that melatonin significantly decreased the levels of antioxidant enzyme and lipid peroxidation products of torsion and brought them to levels of control group.⁽³⁶⁾ Similarly, melatonin administration lowered the levels of reactive oxygen radicals and minimized oxidative stress in the present study. Further, efficiency of early and late administration of melatonin was investigated.

The PMF are electromagnetic stimulation which are in 30-300 Hz interval and they are considered not to have any adverse or harmful effects because of their low energy levels. They are assumed to assist therapies through their ionic activities and accelerating blood flow. Effects of electromagnetic fields on living organisms have been investigated since 1950s. Very low level of electricity is conducted to tissues and there are studies reporting its therapeutic and regulatory effects. These effects basically involve cell division rate, mRNA and protein synthesis levels, permeability of cell membranes, changes in transfers of Ca²⁺, Na⁺, K⁺ ions, and as a result, increases in micro blood circulation. These changes affect both electrical and metabolic behaviors of cell. In addition, they directly or indirectly influence melatonin production, and change daily metabolism and hormone production of organism. Electromagnetic fields of certain frequencies and amplitudes change the behaviors of T-lymphocyte cells and affect cytotoxicity.^(37,38) Kumar et al. showed the therapeutic effect of pulsed magnetic field application on testicular function.⁽³⁹⁾ In the present study, whether PMF application would be beneficial in testis torsion was investigated. In addition, early and late period effects of PMF application were studied.

Testicular scintigraphy using 99mTc pertechnetate is a nuclear medicine imaging technique commonly used for especially acute testis torsion. It gives information on perfusion in torsioned testis.⁽⁴⁰⁻⁴²⁾ PET/CT with 18F-FDG are used to evaluate glucose metabolism levels of cells. This technique is frequently used especially in oncology patients for diagnosis, staging, re-staging and evaluation of response to therapy.^(43,44) Testicular scintigraphy using 99mTc pertechnetate and PET/CT with 18F-FDG techniques were used together in the present study, and thus perfusion and glucose metabolism in testis tissue were evaluated simultaneously. Numerous studies that have been conducted so far have shown that damage due to testis torsion cannot be completely resolved and there is not a routinely used therapeutic agent in clinical practice. In addition, although testis is the most easily torsioned organ in body, number of studies in the literature is not satisfactory on this issue. Therefore, experimental and clinical studies about treatment of testis torsion have been going on. Testis torsion-detorsion model was used in the present study. Protective effects of melatonin whose anti-oxidizing therapeutic efficiency is well known and PMF application which, to our best knowledge, has not been so far used for this aim were investigated using testicular scintigraphy with 99mTc pertechnetate, PET/CT with 18F-FDG and histopathological methods. It was

revealed that PMF application alone improved perfusion and glucose use as efficiently as melatonin in one day and in one week treatment groups. Combined use of PMF and melatonin, on the other hand, increased perfusion only in one day treatment group, and increased glucose use only in one week treatment group compared to each of PMF and melatonin. In this study, we investigated the blood supply by testicular scintigraphy using 99mTc pertechnetate and the level of glucose use by 18F-FDG PET/CT in testicular tissue. Glucose use of testicular tissue is an active process. Simply, increasing blood supply in testis may not cause an increase in glucose use. Therefore, the two methods must be evaluated together.

Limitations of the study: Histopathological examinations were not made in one-week treatment groups due to the problems experienced during the fixation of tissue. There is a need for a one-month treatment group work in order to better understand the effectiveness of PMF.

CONCLUSIONS

In conclusion, it was found that PMF application was as effective as melatonin administration both in early and late period after testis torsion. In addition, it was also shown that testicular scintigraphy with 99mTc pertechnetate and PET/CT with 18F-FDG methods could be effectively used both in diagnosis and in determining the efficiency of the therapy in testis torsion. However, randomized, prospective clinical studies are necessary to confirm our results.

Limitations of the study: Histopathological examinations were not made in one-week treatment groups due to the problems experienced during the fixation of tissue. There is a need for a one-month treatment group work in order to better understand the effectiveness of PMF.

CONFLICT ON INTEREST

The authors declare that they have no competing interests.

REFERENCES

1. Gultekin A, Tanrıverdi HI, Inan S, Yılmaz O, Gunsar C, Sencan A. The Effect of Tunica Albuginea Incision on Testicular Tissue After Detorsion in the Experimental Model of Testicular Torsion. *Urol J.* 2018;15(1):32-9.
2. Barada JH, Weingarten JL, Cromie WJ. Testicular salvage and age related delay in the presentation of testicular torsion. *J Urol.* 1989;142:746-8.
3. Akgür FM, Kılınç K, Aktug T. Reperfusion injury after detorsion of unilateral testicular torsion. *Urol Res.* 1993;21:395-9.
4. Menger MD, Rücker M, Vollmar B. Capillary dysfunction in striated muscle ischemia/reperfusion: On the mechanisms of capillary "no-reflow". *Shock.* 1997;8:2-7.
5. Tang D, Kang R, Zeh HJ, Lotze MT. Oxidative Stress, and Disease. *Antioxid Redox Signal.* 2011;14:1315-35.
6. Aktan G, Doğru-Abbasoğlu S, Küçükgergin

- C, Kadıoğlu A, Ozdemirler-Erata G, Koçak-Toker N. Mystery of idiopathic male infertility: is oxidative stress an actual risk? *Fertil Steril*. 2013;99:1211-5.
7. Morielli T, O'Flaherty C. Oxidative stress impairs function and increases redox protein modifications in humanspermatozoa. *Reproduction*. 2015;149:113-23.
 8. Karaguzel E, Kadihasanoglu M, Kutlu O. Mechanisms of testicular torsion and potential protective agents. *Nat Rev Urol*. 2014;11:391-9.
 9. Payabvash S, Salmasi AH, Kiumehr S, et al. Salutary effects of N-acetylcysteine on apoptotic damage in a rat model of testicular torsion. *Urol Int*. 2007;79:248-54.
 10. Parlaktas BS, Atilgan D, Ozyurt H, et al. The biochemical effects of ischemia-reperfusion injury in the ipsilateral and contralateral testes of rats and the protective role of melatonin. *Asian J Androl*. 2014;16:314-8.
 11. Al-Maghrebi M, Kehinde EO, Anim JT. Long term testicular ischemia-reperfusion injury-induced apoptosis: involvement of survi vindow-regulation. *Biochem Biophys Res Commun*. 2010;395:342-7.
 12. Abueid L, Uslu Ü, Cumbul A, Velioglu Ögünç A, Ercan F, Alican I. Inhibition of 5-lipoxygenase by zileuton in a rat model of myocardial infarction. *Anatol J Cardiol*. 2017;17:269-75.
 13. Turner TT, Caplis LA, Rhoades CP. Testicular vascular permeability: effect of lesions associated with impaired testis function. *J Urol*. 1996;155:1078-82.
 14. Tanyel FC, Büyükpamukçu N, Hiçsönmez A. Contralateral testicular blood flow during unilateral testicular torsion. *Br J Urol*. 1989;63:522-4.
 15. Mogilner JG, Lurie M, Coran AG, Nativ O, Shiloni E, Sukhotnik I. Effect of diclofenac on germ cell apoptosis following testicular ischemia-reperfusion injury in a rat. *Pediatr Surg Int*. 2006;22:99-105.
 16. Melekos MD, Asbach HW, Markou SA. Etiology of acute scrotum in 100 boys with regard to age distribution. *J Urol*. 1988;139:1023-5.
 17. Prater JM, Overdorf BS. Testicular torsion: a surgical emergency. *Am Fam Physician*. 1991;44:834-40.
 18. Fonkalsrud EW. Testicular undescend and torsion. *Pediatr Clin North Am*. 1987;34:1305-17.
 19. Halliwell B, Gutteridge JM. The definition and measurement of antioxidants in biological systems. *Free Radic Biol Med*. 1995;18:125-6.
 20. Clark IA. Tissue damage caused by free oxygen radicals. *Pathology*. 1986;18:181-186.
 21. Pham-Huy L, He H, Pham-Huy C. Free Radicals, Antioxidants in Disease and Health. *Int J Biomed Sci*. 2008;4:89-96.
 22. Datta S, Kundu S, Ghosh P, De S, Ghosh A, Chatterjee M. Correlation of oxidant status with oxidative tissue damage in patients with rheumatoid arthritis. *Clin Rheumatol*. 2014;33:1557-64.
 23. Glasauer A, Chandel NS. Targeting antioxidants for cancer therapy. *Biochem Pharmacol*. 2014;92(1):90-101.
 24. Udupa AS, Nahar PS, Shah SH, Kshirsagar MJ, Ghongane BB. Study of comparative effects of antioxidants on insulin sensitivity in type 2 diabetes mellitus. *J Clin Diagn Res*. 2012;6:1469-73.
 25. Ware LB, Fessel JP, May AK, Roberts LJ. Plasma biomarkers of oxidant stress and development of organ failure in severe sepsis. *Shock*. 2011;36:12-7.
 26. Cvetkovic T, Stankovic J, Najman S, et al. Oxidant and antioxidant status in experimental rat testis after testicular torsion/detorsion. *Int J Fertil Steril*. 2015;9:121-8.
 27. Kanter M. Protective effects of melatonin on testicular torsion/detorsion-induced ischemia-reperfusion injury in rats. *Exp Mol Pathol*. 2010;89:314-20.
 28. Orlinsky M, Shoemaker W, Reis ED, Kerstein MD. Current controversies in shock and resuscitation. *Surg Clin North Am*. 2001;81:1217-62.
 29. Ryter SW, Kim HP, Hoetzel A, et al. Mechanisms of cell death in oxidative stress. *Antioxid Redox Signal*. 2007;9:49-89.
 30. Tao W, Kurschner C, Morgan JI. Modulation of cell death in yeast by the Bcl-2 family of proteins. *J Biol Chem*. 1997;272:15547-52.
 31. Shimizu S, Tsounapi P, Dimitriadis F, et al. Testicular torsion-detorsion and potential therapeutic treatments: A possible role for ischemic postconditioning. *Int J Urol*. 2016;23:454-63.
 32. Ribeiro CT, Milhomem R, De Souza DB, Costa WS, Sampaio FJ, Pereira-Sampaio MA. Effect of antioxidants on outcome of testicular torsion in rats of different ages. *J Urol*. 2014;191:1578-84.
 33. Tang F, Wu X, Wang T, et al. Tanshinone II A attenuates atherosclerotic calcification in rat model by inhibition of oxidative stress. *Vascul Pharmacol*. 2007;46:427-38.
 34. Soufi FG, Sheervalilou R, Vardiani M, Khalili M, Alipour MR. Chronic resveratrol administration has beneficial effects in experimental model of type 2 diabetic rats. *Endocr Regul*. 2012;46:83-90.
 35. MacNee W. Oxidants/antioxidants and COPD. *Chest*. 2000;117:303-17.
 36. Erdemir F, Parlaktas BS, Özyurt H, Boztepe Ö, Atıf Ö, Şahin Ş. Antioxidant Effect of

- Melatonin in Systemic Circulation of Rats After Unilateral Testicular Torsion. *Turk J Med Sci.* 2008;38:1-6.
37. Huang J, Wanga D, Chen J, et al. Osteogenic differentiation of bone marrow mesenchymal stem cells by magnetic nanoparticle composite scaffolds under a pulsed electromagnetic field. *Saudi Pharm J.* 2017;25:575-9.
 38. Arjmand M, Ardeshiryajimi A, Maghsoudi H, Azadian E. Osteogenic differentiation potential of mesenchymal stem cells cultured on nanofibrous scaffold improved in the presence of pulsed electromagnetic field. *J Cell Physiol.* 2017;9999:1-10.
 39. Kumar S, Kesari KK, Behari J. The therapeutic effect of a pulsed electromagnetic field on the reproductive patterns of male Wistar rats exposed to a 2.45-GHz microwave field. *Clinics.* 2011;66:1237-45.
 40. Shayegani H, Divband G, Tavakkoli M, Banihasan M, Sadeghi R. Torsion of the undescended testis detected by ^{99m}Tc testicular scintigraphy: a case report. *Nucl Med Rev Cent East Eur.* 2016;19:24-5.
 41. Lavallee ME, Cash J. Testicular torsion: evaluation and management. *Curr Sports Med Rep.* 2005;4:102-4.
 42. Wu HC, Sun SS, Kao A, Chuang FJ, Lin CC, Lee CC. Comparison of radionuclide imaging and ultrasonography in the differentiation of acute testicular torsion and inflammatory testicular disease. *Clin Nucl Med.* 2002;27:490-3.
 43. Börksüz MF, Erselcan T, Hasbek Z, Yücel B, Turgut B. Morphologic and Metabolic Comparison of Treatment Responsiveness with ¹⁸F-fluorodeoxyglucose-Positron Emission Tomography/Computed Tomography According to Lung Cancer Type. *Mol Imaging Radionucl Ther.* 2016;25:63-9.
 44. Hasbek Z, Yucel B, Salk I, et al. Potential impact of atelectasis and primary tumor glycolysis on F-18 FDG PET/CT on survival in lung cancer patients. *Asian Pac J Cancer Prev.* 2014;15:4085-9.