

A New Technique of Scrotoplasty Following Total Scrotal Destruction by Raised Rotated Perineal Flaps With De Epithelialized Borders

Seyyed Mohammad Ghahestani^{1*}, Pooya Hekmati¹, Sara Karimi²

In this article we present a two-year-old male patient who had history of Fournier gangrene of scrotum. Extensive perineal and scrotal debridement with suprapubic cystostomy tube insertion had been done for him in the emergency setting. One year later his parents brought him back for scrotal reconstruction. A novel technique by using rotational perineal flap was used. The cosmetic result of one-month and three-month follow up is presented in the article.

Keywords: scrotoplasty; perineal flap; scrotum; reconstruction

INTRODUCTION

Total scrotoplasty may be needed in congenital scrotal agenesis or cases of scrotal skin loss due to trauma or necrotizing fasciitis (Fournier gangrene)⁽¹⁾. Scrotal agenesis is also an extremely rare anomaly of scrotum in which various grafts and/or flap techniques may be used⁽²⁾. In the cases of scrotal agenesis several reconstructive techniques including use of myocutaneous flaps such as gracilis flap, split thickness free skin graft, and preputial flap have been mentioned⁽¹⁻⁴⁾. Tissue expanders are also suggested⁽⁵⁻⁷⁾. In this article we present a two-year-old male child with history of Fournier gangrene of scrotum. A novel technique by rotational perineal flap is introduced. The cosmetic results during follow-ups till one year are presented.

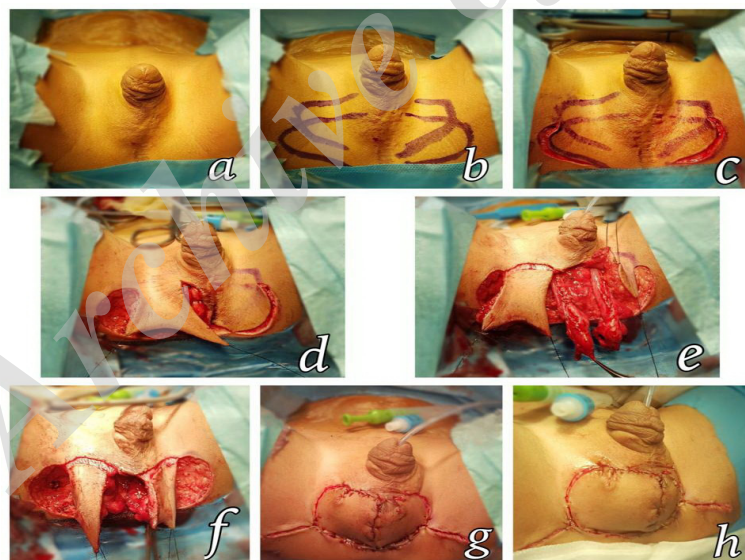


Figure 1. a) Total scrotal destruction; b & c) Marking incision lines of flaps; d) Flaps are raised and anchored by stay sutures; e & f) Upper borders of flaps are de-epithelialized to enhance the eventual cosmetic result; g & h) Lower border of flaps are sutured together by 6-0 PDS sutures producing a protuberant scrotal appearance.

¹Department of pediatric urology, Children Medical Center Hospital, Tehran University of Medical Sciences, Tehran, Iran.

²Department of female urology, Shahid Hasheminejad Hospital, Iran university of medical sciences, Tehran, Iran.

*Correspondence: Department of pediatric urology, Children Medical Center Hospital, Tehran University of Medical Sciences, Tehran, Iran. E mail: mgrosva@gmail.com.

Received September 2017 & Accepted April 2018

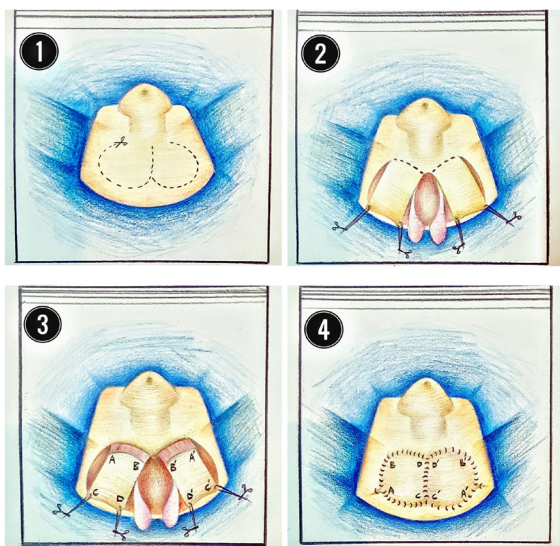


Figure 2. 1) Demarcating incision lines, 2) Raising flaps and releasing the testes to mobilize them down, 3) De-epithelializing upper border to facilitate flap rotation, 4) Rotating flaps and juxtaposing lower border with separate sutures. Upper de-epithelialized border is left un-sutured.

CASE REPORT

A two-year-old boy was referred to the clinic suffering from idiopathic spontaneous necrotizing fasciitis. The infectious process had been started suddenly from an eruption on the groin and progressed to the scrotum within hours. Intravenous antimicrobial agents were instituted and the patient was promptly taken to the operation room. Aggressive debridement preserving the intact testes was done.

Technique

A cystostomy tube was also inserted and fixed in the bladder. The wound was left for secondary healing. One year later the parents brought him back for scrotal reconstruction and orchidopexy. The incision lines were marked. Both testes and cords were freed from their location at distal inguinal canals. The upper borders of the flaps were de-epithelialized. The flaps were freed from downside and lateral aspect but the upper borders were attached. The testes were fixed at midlevel of the

flaps. The lower horizontal sides of the flaps were sutured and attached together with 6-0 PDS sutures. This is an important step in this technique which makes an out-pouching and protruding appearance like a normal scrotum. The other lines of incision were also closed except the de-epithelialized borders which were left for secondary healing as skin folds and borders of scrotum.

Follow-up

After twenty days, three months, and one year follow up, an acceptable scrotal appearance close to the normal shape was achieved.

DISCUSSION

Scrotoplasty may be needed in cases of scrotal agenesis or scrotal loss either due to trauma or necrotizing infection^(1, 2). Various techniques using preputial flap, gracilis flap, split thickness skin graft and use of tissue expanders were explained in the literature⁽¹⁻⁴⁾. Each technique may have a profile of cons and pros. Use of preputial skin has a prerequisite of uncircumcised preputium that may be unavailable in cases of Fournier or trauma that may also be older⁽⁶⁾. On the other hand, the reconstructed small pouch may also be inadequate for large testes⁽⁵⁾. Meshed Split thickness grafts may lack the redundant appearance and the testes may not be mobile⁽⁴⁾. The reconstructed scrotum may also have a skinny appearance. Use of tissue expanders would have multiple sessions of expander and for reconstruction would need minimally two sessions⁽⁵⁻⁷⁾.

An advantage of our technique is its applicability in circumcised patients. It is also single-stage procedure. The testes are relatively mobile inside the neo-scrotum. No implantation of a foreign body is necessary as seen in the cases by tissue expanders. In this case there were some concerns about the implantation of a foreign body that may flare a reaction similar to the first Fournier episode. Because of the thick nature of the flaps, the appearance will not be skinny. Nevertheless the neo-scrotum in patient would lack roagation.

Overall the resultant appearance is acceptable and the parents were satisfied with the outcomes of the surgery. This new technique of scrotoplasty with raised perineal flaps and de-epithelialized border is a good option in cases of scrotal destruction and agenesis and does not require an uncircumcised condition.

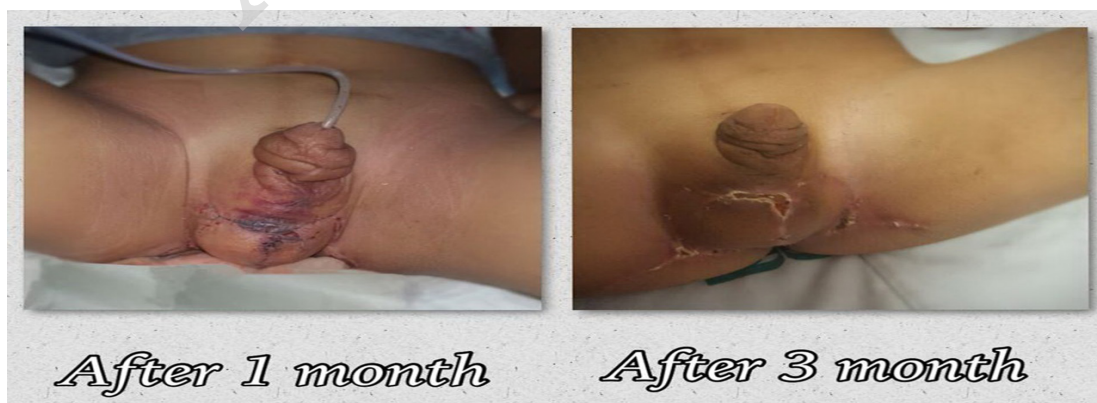

Figure 3. Follow up after twenty days and also after three months

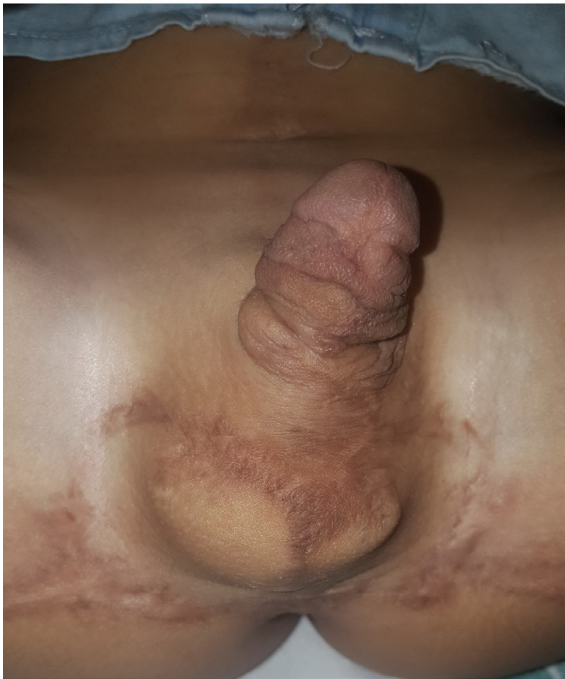

Figure 4. One-year appearance at final follow-up

ACKNOWLEDGEMENT

The authors are indebted to Miss M khalifa for elegant medical illustration and Miss M Pashaii operating room technician in taking and modification of photos.

REFERENCES

1. Lucas JW, Lester KM, Chen A, Simhan J. Scrotal reconstruction and testicular prosthetics. *Transl Androl Urol.* 2017;6:710-21.
2. Lin CT, Chang SC, Chen SG, Tzeng YS. Reconstruction of perineoscrotal defects in Fournier's gangrene with pedicle anterolateral thigh perforator flap. *ANZ J Surg.* 2016;86:1052-5.
3. Wallner C, Behr B, Ring A, Mikhail BD, Lehnhardt M, Daigeler A. Reconstructive methods after Fournier gangrene. *Urologe A.* 2016;55:484-8.
4. Chen SY, Fu JP, Wang CH, Lee TP, Chen SG. Fournier gangrene: a review of 41 patients and strategies for reconstruction. *Ann Plast Surg.* 2010;64:765-9.
5. Bonitz RP, Hanna MK. Correction of congenital penoscrotal webbing in children: A retrospective review of three surgical techniques. *J Pediatr Urol.* 2016;12:161.e1-5.
6. El-Sabbagh AH. Coverage of the scrotum after Fournier's gangrene. *GMS Interdiscip Plast Reconstr Surg DGPW.* 2018;7:Doc01.
7. Kuzaka B, Wróblewska MM, Borkowski T, et al. Fournier's Gangrene: Clinical Presentation of 13 Cases. *Med Sci Monit.* 2018;24:548-55.