

Combination of Thulium Laser Incision and Bipolar Resection Offers Higher Resection Velocity than Bipolar Resection Alone in Large Prostates

Kuan Chun Huang¹, Yung Chiong Chow^{1,2,4*}, Marcelo Chen^{1,2,4}, Allen W. Chiu^{1,2,3}

Purpose: We compared the efficacy and safety of a combined thulium laser incision and bipolar resection of prostate technique (web procedure) with traditional bipolar TURP.

Materials and Methods: We reviewed the medical records of 96 web procedure, 93 traditional bipolar TURP patients between 2013 and 2016. The web procedure consisted of thulium laser incision of the prostate at 3, 5, 7, 9 and 12 o'clock positions up to the resection plane and subsequent bipolar resection of the created prostate blocks. Resected tissue weight, operative time, resection velocity, complications, blood loss, and early operative outcome were compared.

Result: No significant differences were noted among the web procedure (web group) and traditional bipolar TURP in preoperative PSA (6.3 vs 8.7 ng/mL, $P = 0.295$), preoperative postvoid residual urine (55.1 vs 76.4, $P = .056$), modified hemoglobin decrease (defined as total Hb decrease divided by the weight of the resected tissue: 0.060 vs 0.051, $P = .380$), complication rate (5.2% vs 5.3%, $P = .958$), hospitalization (4.0 vs 4.2 days, $P = .120$) and catheterization (2.5 vs 3.4, $P = .066$). The resection velocity was higher in the web group (0.23 vs 0.17 g/min, $P = .001$). In subgroup analysis, the significant difference of resection velocity between two groups was shown in large prostates (> 40 g: 0.25 vs 0.20 g/min, $P = 0.02$) but not in the small prostate group. There was no difference in postoperative postvoid residual urine (21.9 vs 30.3, $P = .231$) and postvoid residual urine decrease (33.1 vs 45.5, $P = .167$) 2 months after surgery.

Conclusion: The combination thulium laser incision and bipolar TURP technique had a higher resection efficiency and comparable efficacy and safety than traditional bipolar TURP.

Keywords: thulium laser; endoscopic prostatectomy; bipolar transurethral resection

INTRODUCTION

Transurethral resection of the prostate (TURP) has been the gold standard for benign prostatic obstruction (BPO) for decades. Compared with traditional monopolar TURP, bipolar TURP has comparable efficacy in improving voiding parameters^(1,2). Bipolar TURP allows for a longer operative time to resect a larger prostate due to the high quality of hemostasis and a low risk of TURP syndrome (TURPS)⁽¹⁻³⁾. The thulium laser is one of the novel technologies used for endoscopic prostatectomy. First used in prostatic surgery in 2005 by Xia et al., the features of continuous and visible release of energy allow for both excellent instant vaporization and precise resection⁽⁴⁾. Various thulium laser techniques have been documented, including thulium laser resection of the prostate (TmLRP) and thulium laser vaporessection of the prostate (TmVRP), referring to elimination of prostatic adenoma by resecting it into small chips. These techniques have been shown to have comparable clinical outcomes and similar improvements in

voiding parameters with a lower transfusion rate and shorter catheter and hospitalization time compared with monopolar TURP⁽⁴⁻⁶⁾. Tm:YAG vapoenucleation (TmVEMP) and Tm:YAG laser enucleation of the prostate (TmLEP) have been shown to be more efficient for large prostates as they can resect the adenoma into large pieces which can then be evacuated with a morcellator^(1,7). Previous studies have compared the different laser technologies as well as TURP, and shown that TmVEMP has better adenoma retrieval volume and efficiency than TmVRP and TURP with similar urodynamic results after surgery⁽³⁻⁵⁾. However, bladder injury due to morcellation can be a serious concern in TmVEMP⁽²⁾. One meta-analysis study also showed that thulium laser technology involves a longer operative time compared with bipolar TURP⁽⁵⁾. Different endoscopic resection technologies have their own advantages. A previous study combining thulium laser and bipolar resection had good outcomes, but the case number was small⁽⁸⁾. Therefore, to investigate the advantages of a thulium laser combined with bipolar TURP (web procedure),

¹Department of Urology, Mackay Memorial Hospital, Taipei, Taiwan.

²Mackay Medical College, New Taipei City, Taiwan.

³School of medicine, National Yang-Ming University, Taiwan.

⁴Mackay junior College of Medicine, Nursing, and Management, New Taipei City.

*Correspondence: No. 92, Section 2, Zhongshan N Rd, Zhongshan District, Taipei City, 10491

Tel: 886 2 2543 3535. Fax: 886 2 25232448. E-mail: edwardhuang322@gmail.com.

Received January 2018 & Accepted July 2018

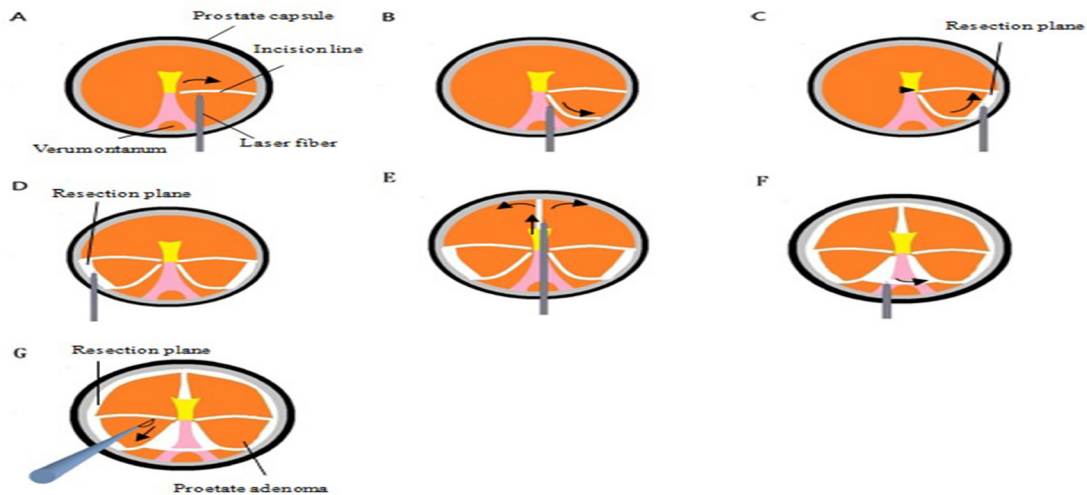


Figure 1. Web procedure. (A) Initial incision line was made at the 3 o'clock position. (B) Another incision line was made at the 5 o'clock position. (C) The 3 and 5 o'clock incisions were joined near the capsule and the block was vaporesected up to the bladder neck without breaking the connection between the adenoma and bladder neck (black arrowhead). (D) The same procedure was repeated on the other side in the 7 and 9 o'clock positions. (E) An incision was made at the 12 o'clock position, and the blocks created between 9 to 3 o'clock were also vaporesected up to the bladder neck. (F) The median lobe was vaporesected in a similar fashion by joining the 5 and 7 o'clock incisions. (G) Bipolar resectoscope was used to resect the blocks into chips

we conducted this study to investigate its efficacy and perioperative outcomes in endoscopic prostatic surgery in our institution.

PATIENTS AND METHODS

Patients

A total of 189 patients who underwent a first endoscopic prostatic surgery were enrolled from 2013 to 2016. Patients who received surgery other than prostate resection at the same time such as transrectal ultrasound-guided biopsy or endoscopic cystolithotripsy were excluded. Ninety-six patients underwent web procedures (web group), and 93 patients underwent traditional bipolar TURP (TURP group). Patients who could afford to pay for the laser procedure out-of-pocket or had private insurance underwent the web procedure, and the rest of the patients underwent bipolar TURP. All of the procedures in both groups were carried out by a single experienced surgeon. All of the patients were candidates for surgery due to BPO with no improvements after treatment with medications. The prostate volume, prostate-specific antigen (PSA), and postvoid residual urine (PVR) were measured in all patients preoperatively. Perioperative outcomes including total operative time, resected prostatic tissue weight, decrease in modified hemoglobin (Hb) (Defined as total Hb decrease per resected tissue weight; total Hb decrease was determined by the differ-

ence of postoperative Hb and preoperative Hb values) after surgery and complications were recorded using Clavien-Dindo classification⁽⁹⁾. The resection velocity (resected prostatic volume/operative time [g/min]) was calculated. The resected prostatic volume was defined as the retrieved prostate chip weight measured by electronic scales. The operative time was defined as the time from start of cystoscopy to Foley insertion after complete resection. The postoperative PVR was also assessed 2 months after surgery as an early outcome to access the efficacy of the procedure.

Ethics

This study was approved by the institutional review board (IRB) of our institution. (IRB number: 17MMHIS174e)

Surgical techniques

Web procedures were carried out using the combination of a thulium laser fiber for incision (mapping) (Vela® XL, Starnedtec, Starnberg, Germany) and a bipolar cutting loop (Olympus TURis system, Olympus America, Melville, NY) for resection (cutting) (Figure 1). This technique involved two steps: mapping and cutting. The initial incision was made from the bladder neck to the front of the verumontanum with the laser fiber at 3 o'clock (Figure 1A). Another incision line was made at 5 o'clock to distally connect with the line at 3 o'clock in front of the verumontanum. The ade-

Table 1. Patients characteristics and preoperative parameters

	Web group (n=96)	TURP group (n=93)	P value
Mean Age (range)	72.1 yrs (50-94 yrs)	71.8 yrs (41-92 yrs)	0.824
Preoperative PSA (ng/ml)	6.3 ± 7.3	8.7 ± 20.7	0.295
Prostate size (g)	56.6 ± 27.6	42.1 ± 16.3	< 0.001
Preoperative PVR (ml)	55.1 ± 40.5	76.4 ± 62.1	0.056

Note. Data presented as mean values ± standard deviation; TURP= Transurethral resection of the prostate; PVR= postvoid residual urine

Table 2. Perioperative outcomes and early postoperative outcomes

	Web group (n = 96)	TURP group (n = 93)	P value
Operative time (min)	67.3 ± 24.4	73.3 ± 25.1	0.094
Resected tissue weight (g)	16.7 ± 14.5	13.2 ± 9.5	0.051
Resection velocity (g/min)	0.23 ± 0.13	0.17 ± 0.08	0.001
Total Hb decrease (g/dl)	0.61 ± 0.59	0.45 ± 0.53	0.049
Modified Hb decrease	0.060 ± 0.078	0.051 ± 0.071	0.380
Catheterization (days)	2.5 ± 2.0	3.4 ± 4.2	0.066
Hospitalization (days)	4.0 ± 0.4	4.2 ± 1.5	0.120
Complication rate	5.2%	5.3 %	0.958
Postoperative PVR(ml)	21.9 ± 21.7	30.3 ± 30.6	0.231
PVR decrease (ml)	33.1 ± 38.2	45.5 ± 60.5	0.167

Note. Data presented as mean values ± standard deviation; Hb=hemoglobin; Modified Hb decrease = total Hb decrease / the resected tissue weight; Resection velocity = resected tissue weight / operative time; PVR= postvoid residual urine; PVR decrease = preoperative PVR-postoperative PVR

noma was detached from the resection plane near the prostatic capsule using vaporesction in a retrograde direction to the bladder neck without breaking the bladder neck connection (**Figure 1C**). We used 80 W for the incision and 20 W for hemostasis. The same surgical mapping was made on the other side from 7 to 9 o'clock (**Figure 1D**). A 12 o'clock incision line was made to separate bilateral lateral lobes (**Figure 1E**). Vaporesction of prostatic tissue at 6 o'clock in front of the verumontanum was then performed to the bladder neck in order to isolate the median lobe (**Figure 1F**). At the end of the mapping, five radial surgical lines were made on the prostate similar to the pattern of a web. Blocks of prostatic adenoma were then lifted between each of the incision lines with each prostate adenoma still attached to the bladder neck so that the circumferential resection plane proximal to the verumontanum could be clearly identified. (**Figure 1G**). The remaining prostate adenoma was then resected with the bipolar cutting loop, and prostatic chips were evacuated using an Ellik bladder evacuator. Compared with the traditional 3 lobe resection technique which starts at 5 and 7 o'clock⁽¹⁰⁾, we chose 3 and 9 o'clock to identify the resection plane rather than 6 o'clock, as this may prevent subtrigonal perforation, especially in prostates with a large median lobe⁽¹¹⁾. Once the resection plane has been identified, resection of the remaining adenoma using the bipolar cutting loop can be performed without concerns of capsular perforation and thus may improve the efficiency of the resection. Bipolar TURP procedures were performed using the bipolar cutting loop (Olympus TURis system, Olympus America, Melville, NY). The cutting power setting was 180 W, and the coagulating setting was 80 W. The adenoma was resected piece by piece according to standard procedures.

Statistical analysis

Independent t-test was used to compare means between two samples, and Chi-square test was used to compare proportions. Data were analyzed using MedCalc Statistical Software version 17.9.5 (MedCalc Software bvba, Ostend, Belgium). A two-sided p value of less than 0.05 was considered to be statistically significant.

RESULTS

The preoperative baseline parameters of the patients are summarized in **Table 1**. The prostate size was significantly larger in the web group, however there were no significant differences in preoperative PSA and preoperative PVR between the two groups. The perioperative and early postoperative outcomes are shown in

Table 2. There were no significant differences in the decrease in modified hemoglobin, overall complication rate, hospitalization, catheterization, postoperative PVR and decrease in PVR between the two groups. The operative time was shorter and the resection tissue weight was larger in the web group compared with the TURP group. As data on postoperative prostate volume were lacking, the amount of vaporized tissue could not be calculated. We also ignored the trivial time of Ellik evacuation. The resection velocity in the web group was significantly higher than in the TURP group despite the lack of data on vaporized tissue volume. To adjust for the effect of prostate size on resection velocity, we used the 40 g of the prostate size as a cutoff for subgroup analysis. Subgroup analysis showed that in smaller prostates (< 40g), resection velocity was 0.18 ± 0.08 g/min in the web group and 0.14 ± 0.06 g/min in the bipolar group (p = .053), and in larger prostates (> 40g), resection velocity was 0.25 ± 0.14 g/min in the web group and 0.20 ± 0.09 g/min in the bipolar group (P = .02). The significantly higher resection velocity was found in web group particularly in the prostate size larger than 40 g. We also analyzed the correlation between resection velocity and prostate volume (**Figure 2**). There was a positive correlation between resection velocity and prostate volume in each group, however the web group had a higher correlation coefficient than the TURP group. This indicated that the web group had a significantly higher efficiency with larger prostates than the TURP group. **Table 3** shows the complications according to the Clavien-Dindo classification system. Eight patients (five in the web group and three in the TURP group) had blood clot retention and required urinary bladder irrigation without anesthesia. None of the patients required a blood transfusion after surgery. One patient had a postoperative urinary tract infection and one patient suffered from pneumonia in the TURP group. None of the patients had Clavien grade IIIb, IV or V complications. There was no significant difference in complications between the two groups.

DISCUSSION

Monopolar TURP is still the gold standard for BPO, however it is associated with a high immediate morbidity rate of up to 11.1%^(1,12), with the most common complications being bleeding, TURPS, and blood clot retention⁽¹²⁾. Bipolar TURP is an alternative technique which can be performed using normal saline, enabling a longer operative time for resection of larger prostates, and decreasing the risk of TURPS⁽¹²⁾. The latest tech-

Table 3. Complication according to the Clavien-Dindo Classification

	Web procedure (n=96)	TURP Group (n=93)	P value
Overall complications	5 (5.2%)	5 (5.3%)	0.958
Grade II			
-UTI	-	1 (1%)	0.308
-Pneumonia	-	1 (1%)	0.308
Grade IIIa			
-Delayed bleeding with blood clot retention	5 (5.2%)	3 (3.2%)	0.498

niques involve laser technology. Greenlight laser photoselective vaporization (PVP) has been shown to be feasible in small-sized prostates with comparable outcomes with regards to urodynamic improvement, with a higher quality of hemostasis but higher retreatment rate in patients with larger prostates compared with TURP⁽¹³⁻¹⁶⁾. Holmium laser enucleation of the prostate (HoLEP) was first described by Gillig et al. in 1998 and was a breakthrough in laser technology⁽¹⁷⁾. As it involves the use of a morcellator, it has high efficiency for large-volume prostates. A previous meta-analysis reported that HoLEP had favorable outcomes with regards to improvements in urodynamic parameters, shorter catheterization time and hospital stay compared with TURP^(13,18). Thulium lasers were first introduced in 2005 for BPO surgery⁽⁴⁾. Similar to holmium lasers, thulium lasers have comparable energy absorption in soft tissue and water, allowing for excellent tissue vaporization with minimal thermal injury to the surrounding tissue⁽⁵⁾. The wavelength of a thulium laser is between 1.75 and 2.22 μm with a penetration depth of 0.25 mm, with the characteristics of continuous-wave output allowing for precise incision and resection of tissue^(1,19). TmVRP has been used in the endoscopic treatment of BPH, and shown similar clinical outcomes and improvements with regards to urodynamic parameters with reduced morbidity compared with monopolar TURP^(13,20). TmVEP and TmLEP have been increasingly used for BPH endoscopic surgery due to the benefits of efficient tissue reduction and low morbidity rate, particularly with larger prostates^(7,14). TmVRP is performed in a similar manner to TURP, in which the adenoma is resected into strips. Compared with TmVEP, a previous non-randomized controlled trial reported that TmVRP had lower efficiency in reducing tissue⁽²¹⁾. Although TmVEP has been reported to have a higher resection efficiency compared with TmVRP, the complications of morcellation and enucleation including bladder wall injury and capsular perforation have also been reported^(11,22-25). To combine the advantages of TURP and TmVEP and to eliminate the drawbacks of both, we introduced this technique using a thulium laser for incision combined with a bipolar TURP cutting loop for resection in BPH endoscopic surgery. Our data showed a higher resection velocity compared with bipolar TURP with equivalent early postoperative outcomes. Making an incision using the laser fiber to identify the resection plane was safe and efficient. Intraoperative bleeding may interfere with the efficiency of endoscopic prostatectomy due to the poor visualization under endoscope. The preoperative use of 5 alpha reductase inhibitor may decrease the intraoperative bleeding of prostate and facilitate the operation⁽²⁶⁾. Laser technology is another method with the potential advantage in decreasing intraoperative bleeding. Concentrating energy on the

prostate tissue surface not only allows for instant vaporization but also coagulation of the microvessels of the prostate leading to excellent hemostasis⁽¹⁹⁾. Laser mapping of the resection plane also has the potential benefit of blocking the main branches of blood supply to the prostate, namely the anterior lateral branches at 2 and 10 o'clock and posterior lateral branches at 5 and 7 o'clock⁽¹¹⁾. At the end of mapping, almost complete devascularization of the adenoma can be achieved for resection⁽¹¹⁾. Due to the relatively small size of the prostate volume in the TURP group, we used modified Hb decrease to evaluate perioperative blood loss rather than absolute Hb decrease to adjust for the effect of the prostate size. However, compared with the web group, the TURP group showed no increased risk of bleeding based on no significant difference in modified Hb decrease and postoperative bladder irrigation. None of our patients required a blood transfusion after surgery. This may be due to improvements in video equipment for endoscopic surgery which provides a clear visual field for instant hemostasis. However, coagulation for hemostasis increases the operative time which may decrease the resection velocity. We believe that the lower coagulation time in the web group compared with the TURP group improved the efficiency of the resection. In this study, the mean of resection velocity in web group was 0.23 g/min, which was significantly higher than in the TURP group. In subgroup analysis, the resection velocity in web group was even higher in large prostates (0.25 g/min). However, our method for calculating the tissue resection velocity is different from some previous studies. We used the resected tissue/total operative time to assess resection efficiency instead of (resected tissue + vaporized tissue)/laser time⁽²¹⁾. Therefore, our resection velocity was generally lower than that reported in previous studies. In subgroup analysis, the significant difference of resection velocity between two groups was showed in large prostates (> 40 g) but not in the small prostate group. We also analyzed the correlation between resection velocity and prostate volume, and found that the web group had a higher correlation coefficient than the TURP group (0.4978 vs. 0.2392). This results indicates the potential advantage of processing large prostates using the web procedure. Shih et al. reported the oyster method using a diode laser to enucleate adenoma from the prostate capsule (as in detaching an oyster from a shell) and a bipolar cutting loop to resect the remaining adenoma in prostates with a volume larger than 80 ml, and showed the procedure to be effective and safe⁽¹¹⁾. Xie et al. performed a similar technique with bipolar TURP combined with a thulium laser for prostates with a volume larger than 80 ml, and showed better outcomes than TURP alone in surgical duration, hemostasis, resection efficiency and recovery^[8]. TmVEP has been reported to have benefits with

larger prostates due to the larger amount of resected tissue volume in a single operation compared with bipolar TURP^(13,14). TmVEP has also been shown to increase the resection velocity in larger prostates⁽¹⁴⁾. However, due to the steep learning curve of TmVEP, some complications can be expected in at least the first 50 cases⁽²⁷⁾. Instead of an enucleation technique, we used deep vaporesction to create a huge adenoma block. The skill of enucleation involves the use of the beak of a resectoscope to dissect the adenoma from the prostate capsule. The difficult parts of enucleation include identifying the surgical plane between the adenoma and prostate capsule and maintaining one plane without capsular perforation during the whole procedure⁽²⁸⁾. Although this technique allows for maximum adenoma resection, it can result in a prolonged operative time with a single procedure and capsular perforation, particularly with large prostates^(11,28). Furthermore, due to the use of blunt dissection in enucleation, the advantage of instant coagulation of microvessels by a laser may be less effective. In the web procedure, we identified the resection plane near the prostate capsule using vaporesction rather than blunt dissection, which may allow for the preservation of minimal adenoma on the prostate capsule as a "safe margin" without a retrograde "pushing" movement by the beak of the resectoscope. None of our cases had prostate capsule perforation.

Superficial bladder wall injuries caused by a morcellator have been reported in 1.3-6.6% of cases^(5,11,29). To avoid the use of a morcellator, we preserved the connection between the remaining adenoma and bladder neck at the end of mapping rather than resect it as a huge adenoma in order to resect the lifted adenoma using the bipolar cutting loop into TUR-like prostate chips. TmVRP has also been performed to resect the prostate into chips small enough to be evacuated through a resectoscope sheath, which can also avoid the use of a morcellator⁽⁶⁾. However, one previous study reported that TmVRP was significantly less efficient than TmVEP⁽²¹⁾, and a meta-analysis reported that its efficiency was even lower than bipolar TURP⁽³⁰⁾. The web procedure seems to combine the two advantages of high efficiency and avoiding morcellation. Although the web group appeared to have shorter duration of hospitalization and catheterization compared with TURP group, it did not reach statistical significance. This may be because the National Health Insurance program in Taiwan combines all prostate endoscopic surgery into the same package of payment (diagnosis related group), thus the clinical course of each group was similar.

There are several limitations to this study. The non-randomized design may have resulted in selection bias. Although it was not the absolute indications, the patients with larger prostates and those receiving anticoagulants tend to be candidates for laser surgery according to the European Association of Urology guidelines⁽¹³⁾. Second, this study is retrospective. Third, urodynamic evaluations were less comprehensive because we only used post-void residual urine volume as an index of voiding improvement, and we did not evaluate the International Prostate Symptom Score (IPSS) or maximum flow rate (Qmax) postoperatively. Fourth, we only focused on perioperative and early postoperative outcomes due to the limited duration of follow-up. Future studies should focus on comprehensive urodynamic parameters as well as long-term complications including urethral stricture,

bladder neck contracture, incontinence and erectile dysfunction and retreatment rate.

CONCLUSIONS

The combination of thulium laser incision and bipolar TURP technique had a higher resection efficiency and comparable efficacy and safety than traditional bipolar TURP especially in the patient with large prostate size (> 40 g). Future studies should focus on the details of improving urodynamics and long-term outcomes.

CONFLICT OF INTEREST

The authors report no conflict of interest.

REFERENCES

1. Yang, Z., T. Liu, and X. Wang, Comparison of thulium laser enucleation and plasmakinetic resection of the prostate in a randomized prospective trial with 5-year follow-up. *Lasers Med Sci*, 2016. 31: 1797-1802.
2. Hirik, E., et al., Safety and Efficacy of Bipolar Versus Monopolar Transurethral Resection of the Prostate: A Comparative Study. *Urol J*, 2015. 12: 2452-6.
3. da Silva, R.D., et al., Bipolar energy in the treatment of benign prostatic hyperplasia: a current systematic review of the literature. *Can J Urol*, 2015. 22 Suppl 1: p. 30-44.
4. Xia, S.J., et al., [Thulium laser resection of prostate-tangerine technique in treatment of benign prostate hyperplasia]. *Zhonghua Yi Xue Za Zhi*, 2005. 85: 3225-8.
5. Nair, S.M., M.A. Pimentel, and P.J. Gilling, A Review of Laser Treatment for Symptomatic BPH (Benign Prostatic Hyperplasia). *Curr Urol Rep*, 2016. 17: 45.
6. Bach, T., et al., RevoLix vaporesction of the prostate: initial results of 54 patients with a 1-year follow-up. *World J Urol*, 2007. 25: 257-62.
7. Bach, T., et al., Feasibility and efficacy of Thulium:YAG laser enucleation (VapoEnucleation) of the prostate. *World J Urol*, 2009. 27: 541-5.
8. Xie, T., et al., The Effectiveness and Safety of Transurethral (Bipolar) Plasmakinetic Resection of Prostate Combined with Thulium Laser for Large Benign Prostatic Hyperplasia (>80ml). *Urol J*, 2016. 13:2889-92.
9. Dindo, D., N. Demartines, and P.A. Clavien, Classification of surgical complications: a new proposal with evaluation in a cohort of 6336 patients and results of a survey. *Ann Surg*, 2004. 240: 205-13.
10. Gilling, P., Holmium laser enucleation of the prostate (HoLEP). *BJU Int*, 2008. 101: 131-42.
11. Shih, H.J., et al., Laser-assisted bipolar transurethral resection of the prostate with the oyster procedure for patients with prostate glands larger than 80 mL. *Urology*, 2013. 81:

- 1315-9.
12. Reich, O., et al., Morbidity, mortality and early outcome of transurethral resection of the prostate: a prospective multicenter evaluation of 10,654 patients. *J Urol*, 2008. 180: 246-9.
 13. Herrmann, T.R., et al., EAU guidelines on laser technologies. *Eur Urol*, 2012. 61: 783-95.
 14. Bach, T., et al., Prospective assessment of perioperative course in 2648 patients after surgical treatment of benign prostatic obstruction. *World J Urol*, 2017. 35: 285-92.
 15. Bouchier-Hayes, D.M., et al., KTP laser versus transurethral resection: early results of a randomized trial. *J Endourol*, 2006. 20: 580-5.
 16. Al-Ansari, A., et al., GreenLight HPS 120-W laser vaporization versus transurethral resection of the prostate for treatment of benign prostatic hyperplasia: a randomized clinical trial with midterm follow-up. *Eur Urol*, 2010. 58: 349-55.
 17. Fraundorfer, M.R. and P.J. Gilling, Holmium:YAG laser enucleation of the prostate combined with mechanical morcellation: preliminary results. *Eur Urol*, 1998. 33: 69-72.
 18. Lourenco, T., et al., Alternative approaches to endoscopic ablation for benign enlargement of the prostate: systematic review of randomised controlled trials. *BMJ*, 2008. 337: a449.
 19. Huang, X., et al., Comparison of the microvessel diameter of hyperplastic prostate and the coagulation depth achieved with mono- and bipolar transurethral resection of the prostate. A pilot study on hemostatic capability. *Scand J Urol Nephrol*, 2008. 42: 265-8.
 20. Fu, W.J., et al., Comparison of 2-microm continuous wave laser vaporessection of the prostate and transurethral resection of the prostate: a prospective nonrandomized trial with 1-year follow-up. *Urology*, 2010. 75: 194-9.
 21. Chung, J.S., et al., Thulium laser (RevoLix) vaporessection versus vapoenucleation with morcellator (Piranha) for the treatment of benign prostatic obstruction: a propensity-matched multicenter analysis. *Int J Urol*, 2014. 21: 1156-61.
 22. Iacono, F., et al., Efficacy and safety profile of a novel technique, ThuLEP (Thulium laser enucleation of the prostate) for the treatment of benign prostate hypertrophy. Our experience on 148 patients. *BMC Surg*, 2012. 12 Suppl 1: S21.
 23. Barbalat, Y., et al., Evidence of the efficacy and safety of the thulium laser in the treatment of men with benign prostatic obstruction. *Ther Adv Urol*, 2016. 8: 181-91.
 24. Kim, S.H., et al., Severe postoperative dyspnea caused by neglected massive intraperitoneal fluid collection during laser enucleation and morcellation of the prostate: a case report. *Korean J Anesthesiol*, 2016. 69: 185-8.
 25. Netsch, C., et al., A prospective, randomized trial comparing thulium vapoenucleation with holmium laser enucleation of the prostate for the treatment of symptomatic benign prostatic obstruction: perioperative safety and efficacy. *World J Urol*, 2017. 35: 1913-21.
 26. Aminsharifi, A., et al., Effect of Preoperative Finasteride on the Volume or Length Density of Prostate Vessels, Intraoperative, Postoperative Blood Loss during and after Monopolar Transurethral Resection of Prostate: A Dose Escalation Randomized Clinical Trial Using Stereolog Methods. *Urol J*, 2016. 13: 2562-8.
 27. Seki, N., et al., Holmium laser enucleation for prostatic adenoma: analysis of learning curve over the course of 70 consecutive cases. *J Urol*, 2003. 170: 1847-50.
 28. Elshal, A.M., et al., Prospective Assessment of Learning Curve of Holmium Laser Enucleation of the Prostate for Treatment of Benign Prostatic Hyperplasia Using a Multidimensional Approach. *J Urol*, 2017. 197: 1099-1107.
 29. Kyriazis, I., et al., Transurethral anatomical enucleation of the prostate with Tm:YAG support (ThuLEP): review of the literature on a novel surgical approach in the management of benign prostatic enlargement. *World J Urol*, 2015. 33: 525-30.
 30. Zhao, C., et al., Thulium Laser Resection Versus Plasmakinetic Resection of Prostates in the Treatment of Benign Prostate Hyperplasia: A Meta-Analysis. *J Laparoendosc Adv Surg Tech A*, 2016. 26: 789-98.