

The use of Indirect Immunoperoxidase Assay in Diagnosis of Type A (H9N2) Avian Influenza Virus Antigen on Frozen Tissue Sections

Shamseddini,*^{1§}M., Vasfi Marandi, M.,² Pourbakhsh, S.A.,³ Gharagozlo, M.,²
Bahmani-Nejad, M.³ and Khazraee-Nia, P.²

§: *mshdin@hotmail.com*

1. Razi Vaccine & Serum Research Institute, P.O.Box 76175-359, Kerman Branch, Iran

2. Faculty of Veterinary Medicine, University of Tehran, Tehran, Iran

3. Avian Diseases Research & Diagnosis Dept., Razi Institute, P.O.Box 11365-1558, Tehran, Iran

Received 29 Dec 2002; accepted 26 Mar 2002

Summary

Avian influenza (AI) is a viral disease of poultry worldwide and earlier diagnosis of the disease is very important in control programs. Among immunohistochemical staining techniques, the poultry laboratory diagnosticians have used indirect immunoperoxidase (IIP) assay for rapid diagnosis of avian viral diseases. In this study the IIP assay was optimized, then compared with the standard AI virus (AIV) isolation procedure on trachea, lung and kidney tissue samples. The samples were prepared from broiler chicken experimentally infected with the reference H9N2 subtype of AIV as well as clinical specimens. For preparation of frozen tissue sections samples were embedded in OCT compound and put rapidly in liquid nitrogen and kept at -70°C. The tissue sections were fixed and subjected to IIP assay by using a type A specific polyclonal and goat anti-chicken peroxidase conjugated antibodies. The sensitivity, specificity, positive and negative predication values IIP assay were 78, 90, 80 and 88%, respectively.

Key words: avian influenza, diagnosis, immunohistochemical, staining, techniques, immunoperoxidase assay

Introduction

The avian influenza viruses (AIVs) are members of the *Orthomyxovirus* genus and usually diagnosed by the isolation and subsequent typing of the virus from suspected tissue samples or cloacal swabs. Several other diagnosis techniques including virological, serological, molecular and immunohistochemical staining (IHS) have been used for diagnosis of the virus. (Chauhan 1995, Esterday *et al* 1997, Fitzgerald *et al* 1994, Smyth *et al* 1993, Swayne *et al* 1998). The IHS techniques, as compared to conventional virological and serological tests are efficient in surveillance programs for detection of circulating AIVs among chicken flocks. These techniques facilitated rapid isolation and further characterization. The immunoperoxidase (IP) assay has several advantages than the other IHS techniques because it does not require the expensive equipment like a fluorescent microscope. This assay has a clear non-fading permanent preparation and color production, which is visualized under optical microscope. The stained slides can be stored for long period. The other advantage of IP assay is its application in retrospective studies using previous paraffin blocks (Van Dam Miers *et al* 1994). The IP assay commonly used to detect virus antigens in tissue samples for rapid and early detection of them such as infectious bursal (Swayne *et al* 1998), Newcastle disease (Lockaby *et al* 1993), reticuloendotheliosis (Calvert *et al* 1994) and AI viruses (Esterday *et al* 1997, Swayne *et al* 1995). Both direct (DIP) and indirect immunoperoxidase (IIP) assays are used. The DIP assay uses labeled antibodies directed against type or subtype specific AI antigens, allowing the staining to be one step with fewer nonspecific reactions occur. The IIP assay uses unlabelled type or subtype specific antibodies to bind to the viral antigens and conjugated antibodies directed to the IgG antibodies to detect the virus and antibody complex. The main advantage of the IIP assay is that any antiserum can be used, and that only one conjugate is necessary for the serum of each species (Swayne *et al* 1998).

The AIV of the H9N2 subtype were isolated from chickens in Iran, 1998 and different virological and serological tests were used for diagnosis of the AI (Pourbakhsh *et al* 2000, Vasfi Marandi *et al* 1999, 2001). However, IIP assay has not been previously used in Iran. The aim of the study was optimize and evaluate an IIP

assay for diagnosis of AIV antigen on frozen trachea, lung and kidney tissue samples from experimentally and clinical chickens.

Materials and Methods

Virus propagation for experimental infections. The AIVs strains designated as A/chicken/Iran/ZMT-1003/1999 (H9N2) and A/chicken/Iran/259/1998 (H9N2) were subtype in International Reference Laboratory at the United Kingdom (Central Veterinary Laboratory). These viruses were propagated in 9 to 11-day-old specific pathogen free (SPF) embryonated chicken eggs (ECEs). The eggs were incubated at 37°C for 48-72 h, and infectious allantoic fluids were harvested. The fluid was clarified by centrifugation at 8000g for 20min at 4°C for removing particulate host debris. The supernatant was collected and the ELD₅₀ was calculated.

Preparation of type A (H9N2) polyclonal antibody. The polyclonal antibody against type specific antigen of 259 strain of H9N2 subtype was prepared in chickens as described by Pourbakhsh *et al* 1999.

Experimental infection. Sixteen 6-week-old Aryan broiler chickens were distributed in two groups. The chickens were negative for antibodies of AIV nucleoprotein as determined by ELISA. The birds inoculated with ZMT-101 strain of H9N2 subtype were housed in a limited acceded laboratory chicken room. Eight chickens inoculated intratracheally and intravenously with infectious allantoic fluid containing 10^{8.5} ELD₅₀ and eight chickens inoculated via the same route with sterile phosphate buffered saline (PBS). Two chickens from each groups were euthanatized on 2, 3, 4, and 10 days postinoculation (PI) by intravenous sodium pentobarbital (100mg/kg) injection. At necropsy, tracheae, lungs and kidneys tissue samples were taken and each tissue divided to two speared parts. One part kept in Cryotube at -70°C for virus isolation and the other embedded in OCT compound (Tissue-Take) and put rapidly at -196°C for 10min. The frozen tissue samples were transferred at -70°C until use.

Clinical tissue sampling. The clinical and postmortem investigations of suspected AI infected chickens were done in Avian Diseases Research & Diagnosis department of Razi Institute (Karaj, Iran) and Poultry Diseases Clinic, faculty of

Veterinary Medicine (University of Tehran, Iran). A total number of 108 tissue samples including 36 tracheae, 36 lungs and 36 kidneys were used in this study. These samples belonged to four suspected AI infection flocks and four apparently healthy flocks. The tissue samples from live or dead birds were aseptically taken for both virus isolation and tissue frozen section preparation.

Virus isolation. Isolation of virus from tissue samples collected from experimentally infected and clinical tissue specimens was carried out according to the guidelines indicated in European Union Council Directive (EUCD) (Esterday *et al* 1997). Briefly, lung, trachea and kidney tissue samples were homogenized in 10% in PBS antibiotic solution and clarified by centrifugation at 8000g. The supernatant was inoculated to the allantoic cavity of five 9-11 day-old SPF-ECEs. After 48-72h incubation at 37°C, allantoic fluids were harvested from the dead or chilled embryos. These fluids tested for hemagglutination activity with a 0.75% suspension of chicken red blood cells. Three serial blind passages were performed for each sample. The presence of AIV in allantoic fluids was confirmed using NDV and H9N2 specific antiserum in HI test.

Preparation of frozen tissue sections. The tissue samples cut by a Cryostat instrument (Cry-cut II) with 4-5µm thickness. The slides were dried in room temperature for 20min and fixed with the cooled acetone (Sigma) for 20min. The dried slides were protected individually within aluminum foil and put at -70°C until application in IHS techniques.

IIP assay on tissue samples prepared from experimentally infected and clinical chickens. The IIP assay was carried out according to the procedure described by Naqi (1990) by slight modifications. Slides kept in -70°C were removed and allowed to equilibrate in room temperature RT at least 1h before using the IIP assay. The slides were blocked by blocking solution contain H₂O₂. After blocking, the slides rinsed first in deionized water and placed in Tris-HCL solution (0.1mol/L, pH7.6) for 5min. A volume about 30µl of 1/100 dilution of type A specific polyclonal antibodies was added on tissue sections and incubated at 37°C for 1h. After incubation, the slides rinsed three time in Tris-HCL solution for 5min. A volume about 30µl of 1/70 dilution of goat anti-chicken horseradish peroxidase (HRP) conjugate antibodies

(KPL) was added, and incubated at 37°C for 45min. Then the slides rinsed in Tris-HCL solution as above. The Histomark orange substrate solution (KPL) containing enhancer orange buffer, 3,3,diaminobenzidine (DAB) and peroxide solutions in deionized water was used as IIP substrate. The slides covered with substrate solution were rinsed in deionized water. Thereafter, the contrast staining green solution was added on sections and rinsed completely with isopropyl alcohol (Sigma) for removing excess stains of the slides. The slides were dried and mounted in xylene based mounting medium (Sigma). The presence of the complex of AIV antigen, polyclonal and goat anti-chicken HRP conjugate antibodies on slides were examined under ordinary light microscope (Ziss,Germany).

Results

IIP assay and virus isolation on tissue samples prepared from experimentally infected chickens. The results of virus isolation and IIP assay on trachea, lung and kidney tissue samples showed in table 1.

Table 1. Comparison of virus isolation (VI) and indirect immunoperoxidase assay (IIP) on tissue samples prepared from experimentally infected (Inf) and uninfected (Uninf) chickens at days of postinoculation (PI)

Group	2 days PI						3 days PI						4 days PI						10 days PI					
	VI			IIP			VI			IIP			VI			IIP			VI			IIP		
	T	L	K	T	L	K	T	L	K	T	L	K	T	L	K	T	L	K	T	L	K	T	L	K
Inf.1	+	+	+	3	2	1	+	+	+	3	3	1	+	+	+	2	2	1	-	-	-	0	1	0
				+	+	+				+	+	+				+	+	+					+	
Inf.2	+	+	+	2	1	1	+	+	+	3	3	1	+	+	-	2	3	1	-	-	-	0	1	0
				+	+	+				+	+	+				+	+	+					+	
Uninf .1	-	-	-	1	0	0	-	-	-	0	0	0	-	-	-	0	0	0	-	-	-	0	0	0
				+																				
Uninf .2	-	-	-	0	0	0	-	-	-	0	0	0	-	-	-	0	0	0	-	-	-	0	0	0

T: trachea, L: lung, K: kidney, 3+: more than 5 positive stained cells, 2+: 1-5 positive stained cells, 1+: less than one positive stained cell and 0: no positive-stained cell per the high-power field (HPF).

Despite entire staining of affected cells, a distinct green stain concentration in host cell nuclei on immediately adjacent to nuclei and the cell surfaces was observed (Figure 1). The presence of AIV antigens on tissue samples appeared red-orange. The intensity of reaction of type A specific polyclonal antibody and antigen observed in optical microscopic examinations were recorded as 0-3 according to the positive

stained cell per HPF. Because, 1+ reaction was also observed rarely occasionally among samples prepared from control chickens, the 1+ record was considered as suspected sample in this study. The reaction of type A specific polyclonal antibody in IIP assay on the frozen tissue sections of trachea, lung and kidney was showed in figures 1, 2 and 3 respectively.

Figure 1. *The indirect immunoperoxidase (3+) reaction on frozen trachea tissue section was shown. The primary antibody is a type A specific polyclonal antibody and second antibody is goat anti-chicken HRP conjugated ($\times 400$)*

Figure 2. *The immunoperoxidase (3+) reaction on frozen lung tissue section was shown. The primary antibody is a type A specific polyclonal antibody and second antibody is goat anti-chicken HRP conjugated ($\times 400$)*

Figure 3. *The indirect immunoperoxidase (3+) reaction on frozen kidney tissue section was shown. The primary antibody is a type A specific polyclonal antibody and second antibody is goat anti-chicken HRP conjugated ($\times 400$)*

The AIVs were not isolated from all tissues samples prepared from non inoculated chickens euthanatized at 2, 3, 4 and 10 days PI. Besides, no AIV antigens were detected on the same tissue samples in IIP assay (Table 1). The best dilution of the

type A specific polyclonal and goat anti-chicken HRP conjugated antibodies were 1/100 and 1/70, respectively.

IIP assay and virus isolation on tissue samples prepared from clinical specimens. The distribution and intensity of reaction of type A specific polyclonal antibody on the frozen tissue of trachea, lung and kidney samples prepared from clinical specimens and its correlation with virus isolation has been shown in table 2. The 0 and 1+ reactions in IIP assay and the 2 and 3+ reactions are considered as negative and positive, respectively. The percentages of positive reactions in IIP assay among trachea, lung and kidney were 39, 44 and 17% respectively. Whereas, the percentage of negative reactions among these tissue samples were 61, 56, and 83% respectively. All tissue samples belong to four apparently healthy flocks were negative in both IIP assay and virus isolation.

Table 2. *The intensity of reaction of type specific polyclonal antibody in indirect immunoperoxidase (IIP) assay and virus isolation (VI) in clinical specimens*

Tests Tissue.(No)	IIP (0) (a)	VI	IIP(1+) (b)	VI	IIP (2+) (c)	VI	IIP (3+) (d)	VI
Trachea (36)	19	2	3	3	6	5	8	8
Lung (36)	15	1	5	2	9	6	7	6
Kidney (36)	25	-	5	-	3	1	3	3

In the HPF, a: 0 (no positive-stained cell), b: 1+ (less than one positive stained cell), c: 2+ (1-5 positive stained cells) and d: 3+ (more than 5 positive stained cells). The (0) and (1+) reactions and the (2) and (3+) reactions are considered as negative and positive, respectively.

Analyses of positive and negative results by 2×2 k-square statistic method in IIP assay and virus isolation obtained among clinical specimens. The results of virus isolation into SPF-ECE were considered as reference test for percentage calculation. Of 37 influenza positive samples by virus isolation 29 (78%) were positive and 8 (22%) were negative by IIP assay. Of the 71 original negative specimens tested by virus isolation, 7 (10%) were positive and 64 (90%) were negative by IIP assay. The sensitivity and specificity were 78 and 90% for IIP assay, respectively against the reference test. Also, the positive and negative predication values were 80 and 88%, respectively.

Discussion

The severe disease can be prevented by timely administered control measures. Effective use of control programs is dependent of early diagnosis by rapid diagnosis methods (Esterday *et al* 1997). The IHS techniques are the method that used most widely for the rapid detection of avian viral disease antigens because of its sensitivity, simplicity and availability of instrumentation (Swayne *et al* 1998). The IP assay has been made for detection of H4, H5 and H7 (Capua *et al* 1999, Swayne 1995) subtypes of type A AIV. To our knowledge such IIP assay has not yet been reported for H9N2 subtype of AIV. The aim of this study was to compare routine virus isolation with an IIP assay for detection of H9N2 subtype of AIV antigen in frozen tissue sections of prepared from experimentally infected chickens and clinical specimens.

Although, the sensitivity and specificity of IP assays is directly dependent on the choice of reagents and procedures, but IIP assay is a reliable and rapid diagnosis test (Esterday *et al* 1997, Swayne *et al* 1998). The kind of the fixative compounds is very important in IIP assay. Smyth *et al* (1993) obtained the best result with fixation in neutral buffered formalin for 6h. Application of decalcifying fluid containing formic acid eliminated immunoreactivity of the antibodies (Smyth *et al* 1993). The OCT is a new fixation compounds that maintenance the surface antigen non-changeable on tissue section (Brandtzaey *et al* 1999, Ormerod *et al* 1999, Van Der Loos 1999). Therefore in this study, the samples kept in OCT compound. In order to optimizing an IIP assay for application on clinical specimens an experimentally infection was carried out in 6-week-old Aryen broiler chickens. There was a good relationship between virus isolation and IIP assay among specimens. The tracheae, lungs and kidneys sampled at 3 days PI showed better reaction (3+) as compared to samples prepared at 2, 4 and 10 days PI. Whereas, control non-inoculated chickens were not showed any reaction in IIP assay (Table 1). In conscience, to optimize an IIP assay for testing clinical specimens the tissue sections prepared at 3 days PI was used. Since the number of positive reactions of IIP assay on trachea, lung and kidney section of prepared from clinical specimens were 14 (39%), 16 (44%) and 6 (17%),

respectively, so it seems that trachea and lung tissue samples could be the choice tissue for diagnosis of AIV antigens on clinical specimens.

The detection of type A specific antigen in kidney tissue prepared from chickens infected with H9N2 subtype is surprising, because Iranian subtypes strains not highly pathogenic AIV. It seems that H9N2 AIV may be persisted in kidney tissue. Hooper *et al* (1995) believed that the IIP assay could be an important confirmation test for low pathogenicity AIVs in kidney tissue. Swayne and Selmons (1995) also reported that the kidney lesions were more severe in chickens inoculated with low pathogenicity AIVs. They (1995) explained that a significant difference existed between the frequencies of virus recovery from kidney tissues and cloacal swabs, and marked differences between virus titers in kidney tissue. Wood *et al* (1996) concluded that pathogenicity of AIV might have been associated with replication in the kidney.

In this study sensitivity, specificity, positive and negative predication values for testing clinical tissue samples were very good in IIP assay by using polyclonal antibodies as compared by reference virus isolation test. The utilization of monoclonal antibodies against nucleoprotein of AIV may increase both sensitivity and specificity of IIP assay for detection of AIV antigen on frozen tissue section.

Acknowledgements

The authors wish to express their gratitude to Dr. R. Momayez, Dr. MR. Gholami and Dr. M. Banani.

References

Calvert, J.G., Nazerian, K. (1994). An immunoperoxidase plaque assay reticuloendotheliosis virus and its application to a sensitive serum neutralization assay. *Avian Diseases* 38:165-171.

Capua, I., Marangon, S., Selli, L., Alexander, D. J., Swayne, D.E., Pozza, M. D., Parenti, E. and Cancellotti, F. M. (1999). Outbreaks of highly pathogenic avian influenza (H5N2) in Italy during October 1997 to January 1998. *Avian Pathology* 28:455-460.

Chauhan, R.S. (1995). *Textbook of Veterinary Clinical and Laboratory Diagnosis* (1st edn.). Pp:205-250. Jaypee Brothers Medical Publishers Ltd.

Cruz-Coy, J.S., Giambrone, J.J. and Hoerr, F.J. (1993). Immunohistochemical detection of infectious bursal disease virus in formalin-fixed, paraffin-embedded chicken tissues using monoclonal antibody. *Avian Diseases* 37:577-581.

Esterday, B.C., Hinshaw, V.S. and Halvorson, A. (1997). Influenza. In: B.W.Calnek, Barnes, J., Reid, W.M. and Yoder, H.W. (Eds.), *Diseases of Poultry* (10th edn.). Pp:563-603. Iowa State University, Ames.

Fitzgerald, S.D., Reed, W.M., Langheinrich, K.A., Porter, A.S. and Lumberr, L.A. (1994). A retrospective immunohistochemical study of type II avian adenoviral infection in turkey, pheasant and chicken tissues. *Avian Diseases* 38:78-85.

Hooper, P.T., Russell, P.W., Selleck, P.W. and Stanislawek W.I. (1995). Observation on the relationship in chickens between the virulence of some avian influenza viruses and their pathogenicity for various organs. *Avian Diseases* 39:458-465.

Lockaby, S.B., Hoerr, A.C., Ellis, A.C. and Yu, M.S. (1993). Immunohistochemical detection of Newcastle disease virus in chickens. *Avian Diseases* 37:433-437.

Naqi, S.A. (1990). A monoclonal antibody-based immunoperoxidase procedure for rapid detection of infectious bronchitis virus infected tissues. *Avian Diseases* 34:893-898.

Pourbakhsh, S.A., Khodashenas, M., Kianizadeh, M. and Goodarzi, H. (2000). Isolation and identification of avian influenza virus H9N2 subtype. *Archives of Razi Institute* 51:27-38.

Pourbakhsh, S.A., Moosakhani, F. and Kianizadeh, M. (1999). Standardization of ELISA for detection of avian influenza virus antibodies. *Archives of Razi Institute* 50:19-28.

Selmons, R.D., Swayne, D.E. (1995). Tissue tropism and replicative properties of Waterfowl-origin influenza viruses in chickens. *Avian Diseases* 39:521-527.

Smyth, J.A., Moffett, D.A., McNulty, M.S., Todd, D. and Mackie, D.P. (1993). A sequential histopathologic and immunocytochemical study of chicken anemia virus infection at one day of age. *Avian Diseases* 37:324-338.

Swayne, D.E., Selmons, R.D. (1995). Comparative pathology of intravenously inoculated wild duck and turkey-origin type A influenza viruses in chickens. *Avian Diseases* 39:74-84.

Swayne, D.E., Glisson, J.R., Jackwood, M.W., Pearson, J.E. and Reed, W.M. (1998). *A Laboratory Manual for the Isolation and Identification of Avian Pathogens* (4th edn.). Pp:150-155, 233-277. American Association of Avian Pathologists, Inc, Kennett square, Pennsylvania.

Van Dam Miers, M.C.E., Leach, C.K. (1994). *Technological Applications of Immunochemicals*. Butter Worth-Heinemann Ltd.

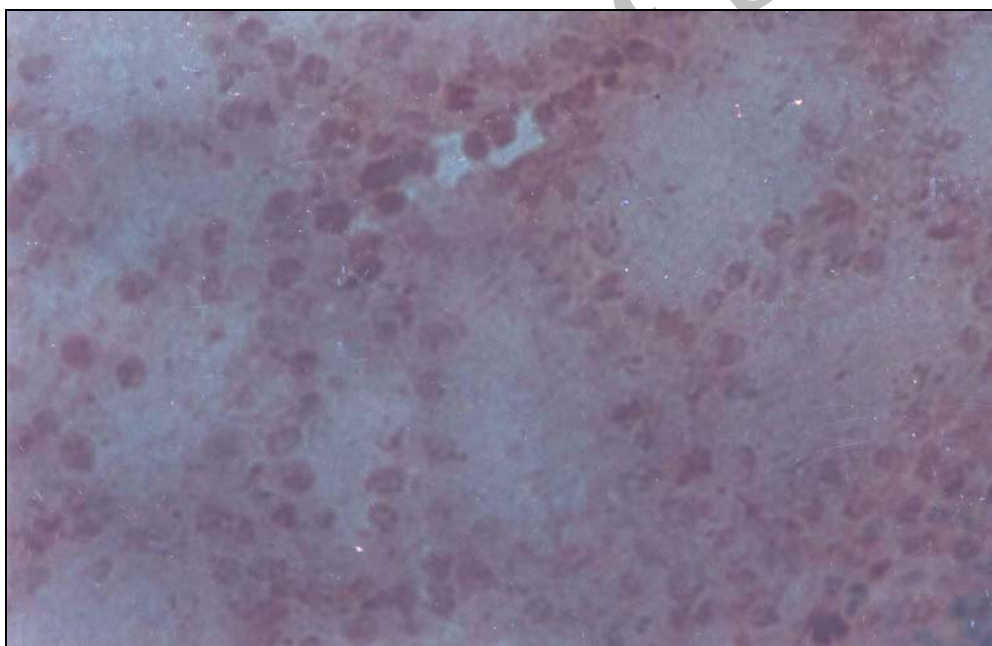
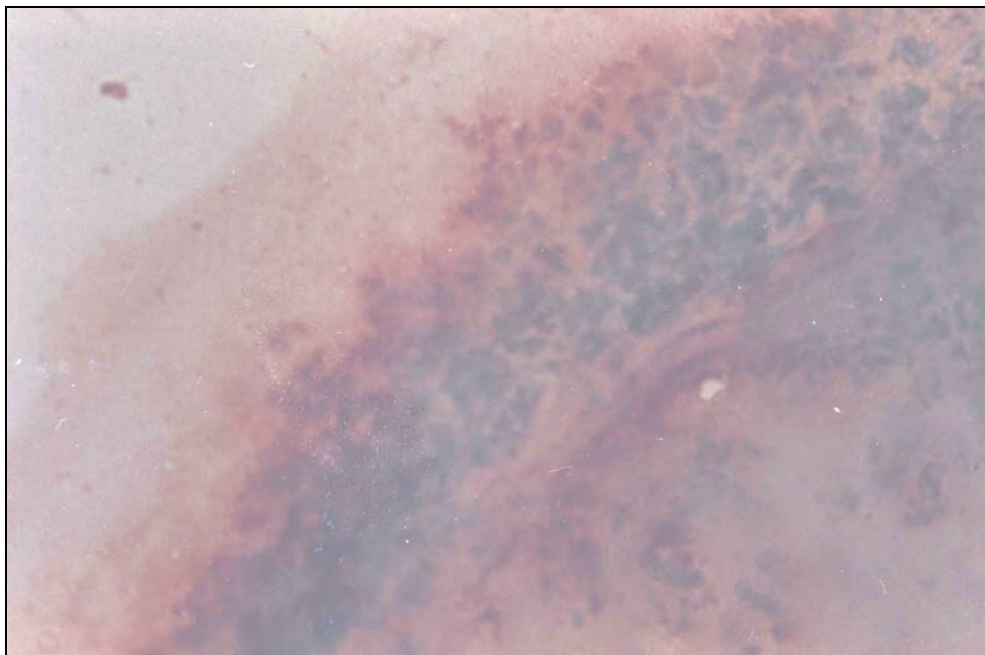
Van Der Loos, C.M. (1999). *Immuno Enzyme Multiple Staining Methods*. Pp:1-6. Bios Scientific Publishers Ltd.

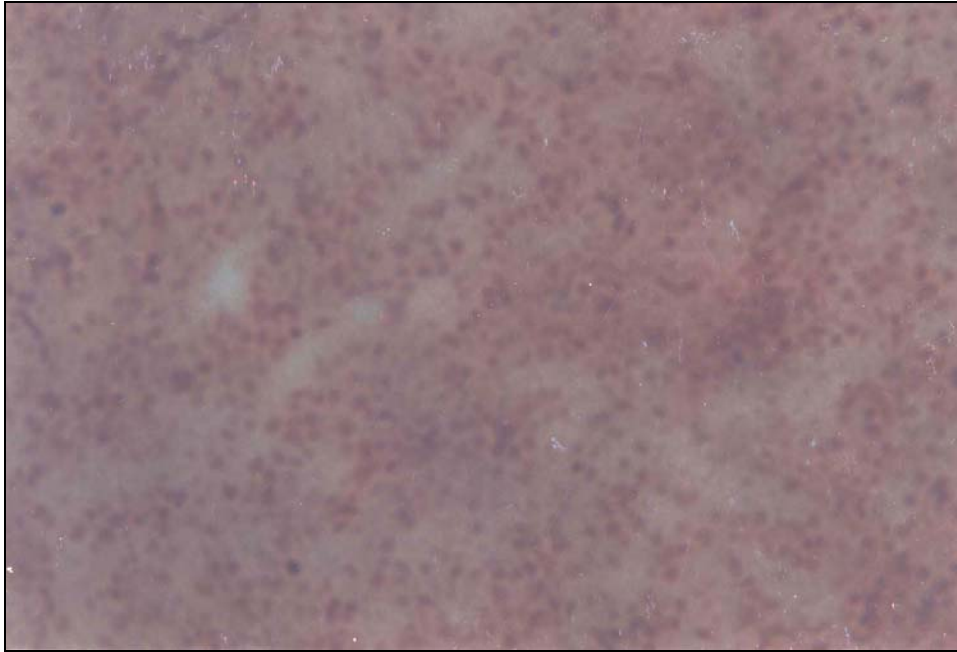
Vasfi Marandi, M., Bozorgmehri Fard, M.H. (1999). An outbreak of non-highly pathogenic avian influenza in chicken in Iran. *Proceeding of 6th Meeting of World Veterinary Association. Mondial Vet. Lyon, France*.

Vasfi Marandi, M. and Bozorgmehri Fard, M.H. (2001). Preparation and evaluation of H9N2 subtype specific antigen for using in HI test. *Iranian Journal of Veterinary Research* (2):174-181.

Wood, G.W., Banks, J., Strong, I., Parsons, G. and Alexander, D.J. (1996). An avian influenza virus of H10 subtype that is highly pathogenic for chickens, but lacks multiple basic amino acids at the haemagglutinin cleavage site. *Avian Pathology* 25:799-806.

Archive of SID





Archive of SID