



## Inhibitory effects of Clindamycin on shedding of *Toxoplasma gondii* oocyst and its comparison with Monensin in kitten

Mosallanejad<sup>\*1</sup>, B., Malmasi<sup>2</sup>, A., Mohebbali<sup>3</sup>, M., Tabatabayi<sup>4</sup>, M., Bahonar<sup>4</sup>, A.,  
Sasani<sup>5</sup>, F.

1. Department of clinical sciences, Faculty of Veterinary Medicine, University of Shahid Chamran, Ahwaz, Iran

2. Department of clinical sciences, Faculty of Veterinary Medicine, University of Tehran, Tehran, Iran

3. Department of parasitology, Faculty of Hygiene, University of Tehran, Tehran, Iran

4. Department of Food Hygiene, Faculty of Veterinary Medicine, University of Tehran, Tehran, Iran

5. Department of pathobiology, Faculty of Veterinary Medicine, University of Tehran, Tehran, Iran

Received 25 July 2005; accepted 19 Jan 2006

---

### ABSTRACT

The efficacy of Clindamycin and Monensin were evaluated in the prevention of oocyst shedding of kittens with *Toxoplasma gondii* (Tehran strain). In this study, 28 healthy kittens aged 1.5 – 2 months old divided randomly into 4 groups of seven. In group 1, Kittens were fed with the infected brain tissues of mice, all of seven kittens (100 %), shed oocyst, nearly 1 week after infection, which lasted for 8 to 9 days. In group 2, kittens were fed with infected brain tissues of mice and Clindamycin at dose of 20 mg/kg from day -3 to + 21 after infections, none of seven kittens, shed any oocyst. In group 3, kittens were fed with Clindamycin at dose of 10 mg/kg, same as group 2, two of 7 kittens (28.6%), began to shed oocyst from day 11 to 18 after infection. Kittens of group 4 that were fed with Monensin at dose of 0.02 % incorporated in dry food did not shed any oocyst. Data analysis revealed that Clindamycin 20 mg/kg and Monensin 0.02% had a 100% inhibitory effect against *Toxoplasma gondii* (Tehran strain). No adverse reactions were observed during the experimental period.

**Keywords:** Clindamycin, Monensin, *Toxoplasma gondii*, Oocyst shedding, kitten, Tehran strain

---

### INTRODUCTION

Clindamycin is the drug of choice for treating clinical toxoplasmosis in cats. Because of its good intestinal absorption, oral and parenteral dosages are similar. Clindamycin dosages for treating toxoplasmosis are greater than those for treating anaerobic infections for which the drug is marketed.

Oral Clindamycin may be cause anorexia, vomiting, and diarrhea in cats, especially at higher dosages. These side effects appear to be related to local GI irritation (Dubey 2002). This drug had paradoxical effect in the treatment of ocular toxoplasmosis. Experimental studies with high dosages of Clindamycin have demonstrated that it has a beneficial effect in reducing *T. gondii* cyst numbers in the tissues of mice and rabbits and in altering the

---

\* Author for correspondence. E-mail: bmosalla940@yahoo.com

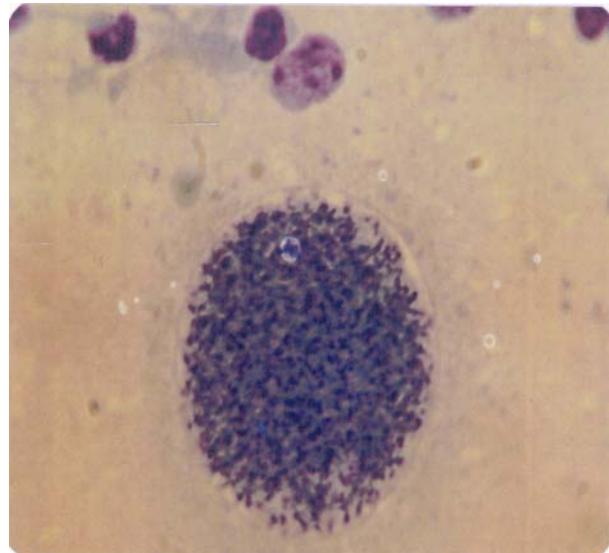
severity of Toxoplasmic encephalitis in mice (Davidson *et al* 1996, Hill *et al* 2002). Oocyst excretion has been reduced by the dosage of injected Clindamycin recommended for systemic chemotherapy (Dubey *et al* 1977). Also, Monensin with dosage 0.02 % in dry food had good inhibitory effects on toxoplasmosis (Frenkel *et al* 1982). Several reports on the use of anticoccidial drugs against toxoplasmosis in cats have reported in the literature (Melton *et al* 1975). Available drugs such as Sulfadiazine, Pyrimethamine, Monensin, Clindamycin and Toltrazuril usually suppress replication of *Toxoplasma gondii* (Dubey *et al* 1977, Rommel *et al* 1988). Due to public health significance of *Toxoplasma gondii* oocysts there is a need for drugs that will prevent the shedding of oocysts by cats. In this study, Clindamycin was used due to having high potency against *Toxoplasma gondii* and it had not been tested in kittens for preventive purposes with such strain (Tehran strain). The object of this work was to follow up the preventative effects of oral Clindamycin hydrochloride with two dosages (10 and 20 mg/kg) against intestinal stages of *Toxoplasma gondii* and it was compared with Monensin 0.02%, at non-toxic doses incorporated into food.

## MATERIALS AND METHODS

**Study animals.** 60 Syrian mice weighing about 35 grams were obtained from Karaj Razi Institute. They were kept in Makrolon cages and received maintenance diet and water ad libitum. All mice were inoculated intraperitoneally with *Toxoplasma gondii* bradyzoites of Tehran strain (Figure 1).

This strain obtained from faculty of hygiene of Tehran University and inoculated to mice. Tehran strain of *Toxoplasma gondii* infects mice chronically and lacks the acute infectivity of other strains. Mice were killed 30 days after inoculation and their brains homogenized in normal saline. Cerebral infection of mice was verified by observation of bradyzoites of

*Toxoplasma gondii* (Tehran strain) in tissue smears under light microscopy. Then, kittens were fed an equal amount (2 ml) of homogenized suspension of mice infected brain tissues on day one only once through a syringe.



**Figure 1.** Photomicrograph showing bradyzoites of *Toxoplasma gondii*, Tehran strain (magnification  $\times 100$ )

**Animal grouping.** Before the experiment, kittens were examined clinically and paraclinically. All of them were healthy. Tri-cat vaccine (Calicivirus + Herpesvirus 1 + Panleukopenia) and antiparasite drugs (Mebendazole + Praziquantel) were administered to them before challenge. Also, body weights of kittens obtained daily and continued till day 30 after infection. In this study, 28 healthy kittens aged 1/5- 2 months old with body weight of 650-900 grams of both sexes were divided randomly into 4 groups of seven: Group 1 was fed brain tissues of infected mice (Positive control). Group 2 was fed brain tissues of infected mice and Clindamycin 20 mg/kg from day -3 to +21 after infection. Group 3 was same as group 2 they were fed Clindamycin 10 mg/kg. Group 4 =Seven kittens that were fed both brain tissues of infected mice and Monensin 0.02% from day -3 to +21 after infection. Clindamycin hydrochloride as gelatin capsules, equivalent to 150

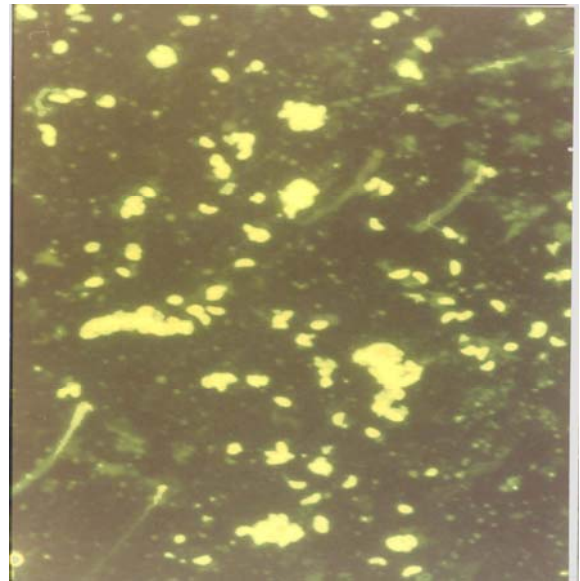
mg Clindamycin was used. Also, Monensin was mixed at concentration of 200 mg/kg in dry foods of kittens. Between 60 and 80 grams food was consumed daily by kittens weighing approximately 800 grams or 12 to 16 mg of Monensin per kitten per day. Finally all kittens were euthanized with an overdose of intravenous Ketamin hydrochloride and Magnesium sulfate. Postmortem studies were then immediately performed, and selected tissues were fixed in 10 % buffered neutral formalin and later processed for light microscopy with paraffin embedding and hematoxylin-eosin staining.

**Hematological analysis.** Blood samples were collected from the jugular vein of each animal using 2 ml Syringes and 25 – gauge needles into appropriately labeled EDTA tubes. Before and after each challenge, antibody titers serum chemistry (BUN, Scr, ALT, AST, and ALP) and certain hematologic values were determined before treatment and on the 30<sup>th</sup> days after infection.

**IFA test.** Serum samples were taken in day 1 (before inoculation) and day 30 (post-inoculation) in order to determine the antibody level of the sera using IFA. The processes of IFA test were as follow: 5 µl of a whole tachyzoite preparation (Pasteur Institute) added to 5 µl of the kitten serum that diluted in PBS and 5 µl of an appropriate dilution of rabbit anti-feline IgG conjugated to fluorescein isothiocyanate and finally examination by using a fluorescence microscope (Lappin 1996). Antibody titers were determined at days 1 and 30 after challenge. The parasites were seen as green fluorescence in a positive test serum. Serum dilutions were in range between 1/10 and 1/2560 (Figure2).

**Fecal examination and oocyst determination.** Feces were collected from kittens daily for 30 days after the initial exposure to toxoplasma and seven times weekly after challenge. The feces were examined for the appearance of oocysts through flotation technique. Then, 1 gram feces were mixed with 7 ml formalin 10 % to a liquid consistency, and

the mixture was strained with gauze. Thereafter 3 ml ether was added to fecal suspension and centrifuged at 3000 g for 10 minutes. The precipitation of the tube base, examined at low-power (40) magnification (Burney *et al* 1999).



**Figure 2.** Photomicrograph showing positive sample of IFA (magnification × 40)

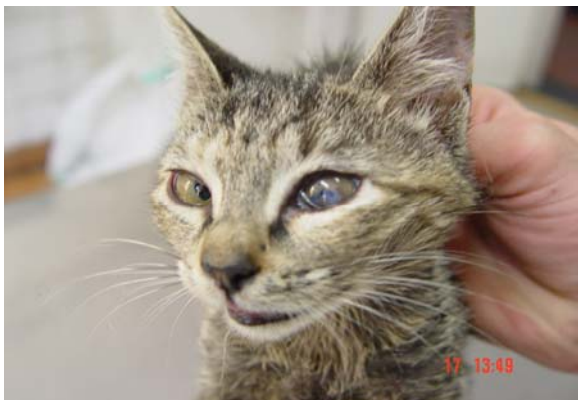Shedding intensity was graded on a scale of 1 to 4; 1+ = < 500 oocysts per gram feces, 2+ = 500 – 2000 oocysts per gram feces 3+ = 2000 – 3500 oocysts per gram feces, 4+ = > 3500 oocysts per gram feces.

**Statistical analysis.** Results of oocyst shedding, IFA titers and Hematological values were evaluated by Exact Fishers statistic test. Body weight changes of kittens were studied by ANOVA and Paired t test.

## RESULTS

In group 1 (positive control), all of kittens (100 %) shed oocysts nearly 1 week after feeding with infected mouse brain tissues, and this shedding lasted for 8 to 9 days. One kittens of this group developed unilateral anterior uveitis in day 16 after infection which remained to the end of trial (Figure 3). In group 2, none of kittens shed any

oocysts till day 30 after infection. In group 3, two of 7 kittens (28/6 %) shed oocyst on day 11 to 18 after infection. In this group number and duration of oocyst shedding, were lower compared with group 1. In group 4, Monensin 0.02% in food prevented oocyst shedding in all of seven kittens (100%). Based on Fishers statistic test, oocyst shedding in group 1 compared with other groups was significant ( $p = 0.0005$ ), but obtained results did not show any significant difference between kittens in groups 2, 3 and 4 ( $p > 0.05$ ), Although 2 kittens of group 3 shed oocyst. Hematological values in 28 kittens were normal before examination but final results showed Leucocytosis, Neutrophilia, Lymphocytosis and Eosinophilia in 4, 3, 2 and 3 kittens of group 1 respectively.



**Figure 3.** Unilateral anterior uveitis in infected kitten with *Toxoplasma gondii*.

Leucocytosis in kittens of group 1 was very high compared with other groups. It was significant ( $p=0.04$ ). Neutrophilia, Lymphocytosis and Eosinophilia had no significant differences between all of groups. Also, there was no significant difference in the values of BUN, Serum Creatinine, ALT, ALP, AST, RBC count, hemoglobin, hematocrit, index of red cell width or platelets between groups and within groups ( $p > 0.05$ ). Body weight changes of groups 1, 2, 3 and 4 presented as a mean value  $\pm$  standard deviation ( $M \pm SD$ ) (Table 1).

At the beginning of trial, the body weights of all kittens were in a same range. Kittens of group 1 had

lower weight gain compared with other groups in day 30. Mean body weight gain in kittens of group 1 (214.3 grams) compared with group 2 (285.7 grams), group 3 (307.2 grams) and groups 4 (350 grams) which studied by paired t-test was significant ( $p = 0.02$ ).

**Table 1.** The body weight changes in kittens of different groups.

Weight (Mean $\pm$ SD)							
Group 1		Group 2		Group 3		Group 4	
1 <sup>st</sup> day	30 <sup>th</sup> day	1 <sup>st</sup> day	30 <sup>th</sup> day	1 <sup>st</sup> day	30 <sup>th</sup> day	1 <sup>st</sup> day	30 <sup>th</sup> day
764.3	978.6	778.6	1064.3	757.1	1064.3	757.1	1107.1
$\pm$	$\pm$	$\pm$	$\pm$	$\pm$	$\pm$	$\pm$	$\pm$
74.8	80.9	99.4	80.2	105.8	102.9	83.8	105.8

**Table 2.** Effects of Clindamycin and Monensin on shedding intensity of kittens.

Groups	Period of drug administration (day)	Duration of shedding (day)	Mean shedding intensity	The first day of oocyst shedding
1	ud*	7 to 8	3+(in 7 kittens)	7+
2	-3 to +21	All negative	ud*	ud*
3	-3 to +21	7	3+(in 7 kittens)	11+
4	-3 to +21	All negative	ud*	ud*

\* ud = undetectable

Body weight differences of kittens, between groups 2, 3 and 4 had no significant difference at the end of trial (Table 2).

Before each trial all kittens were tested for presence of antibody titers against *Toxoplasma gondii* by IFA technique. None of them had any detectable titers in day 1. Results of IFA test in kittens of groups 1, 2, 3 and 4 on day 30 after infection were as follow (Table 3). Increase of antibody titers was very high in kittens of group 1. As can be seen from Table 4, the highest antibody titers were in kittens No. 2 (1/640), 3 (1/1280), 5

(1/1280) and 6 (1/640) of group 1 (Fourfold the first titer). In groups 2, 3 and 4 increase of antibody titers was low. Only antibody titers were high in kitten's No. 3 (1/320) and No. 5 (1/640) of group 3, which shed oocysts on day +11 after infection. Increase of antibody titers in kittens of group 1, compared with

**Table 3.** Results of IFA test in kittens of group 1 to 4

Group 1		Group 2		Group 3		Group 4	
Positive control		Clindamycin 20 mg/kg		Clindamycin 10 mg/kg		Monensin 0.02%	
First titer	Last titer	First titer	Last titer	First titer	Last titer	First titer	Last titer
ud*	1/320	ud*	1/20	ud*	1/10	ud*	1/10
ud*	1/640	ud*	1/20	ud*	1/20	ud*	-
ud*	1/1280	ud*	1/10	ud*	1/320	ud*	1/40
ud*	1/80	ud*	1/80	ud*	1/40	ud*	1/10
ud*	1/1280	ud*	1/20	ud*	1/640	ud*	1/80
ud*	1/640	ud*	1/20	ud*	1/20	ud*	1/40
ud*	1/160	ud*	-	ud*	1/10	ud*	1/20

\* ud = undetectable

groups 2, 3 and 4 which analyzed by Fischer exact test, showed significant difference ( $p = 0.01$ ). Also increase of antibody titers between kittens of group 2, 3 and 4 were non significant ( $p > 0.05$ ).

## DISCUSSION

In this study, were shown that Clindamycin 20 mg/kg and Monensin 0.02% had a 100 % inhibitory effect on shedding of oocyst in all kittens infected with bradyzoites of *Toxoplasma gondii*. These results showed that effects of Clindamycin is related to dosage and by decrease of dosage from 20 mg/kg to 10 mg/kg, 2 of 7 kittens (28/6 %) shed oocyst. Clindamycin 10 mg/kg only delayed the period and markedly diminished oocyst shedding in 5 of 7 kittens, but not suppressed it completely. The first report of injected Clindamycin (intramuscular) and its effect on oocyst shedding was made by (Dubey

1977). It was administrated twice daily from third to ninth day's post-inoculation with dosage 100 mg/kg and caused two cats shed two and five times fewer oocysts than the control cats. We tested the safety of the effective drug dose by giving Clindamycin 20 mg/kg for an extended period of time. The medicated food was well accepted and tolerated for 4 week as indicated by the kitten's weight gain, by similar hematologic and serum chemistry values, and by the absence of dehydration, colitis, diarrhea or vomiting. We didn't any adverse reactions during the experimental period. Efficacy of drugs against feline toxoplasmosis were judged by (i) Comparing the duration of oocyst shedding and the number of oocysts shed, (ii) Hematological and clinical data, (iii) determination of antibody titers to *Toxoplasma gondii* in cats. In this study, one of kittens of group 1 showed unilateral anterior uveitis on day 16 after infection which is quite common in cats infected with *Toxoplasma* infection. Diagnosis was based on detection of a high serum antibody titer (1/1280) to *Toxoplasma* (which had no titer before the trial), exclusion of other causes of uveitis, deliberately infection with *Toxoplasma gondii* (Tehran strain), oocyst shedding (Mean = 3+) and other clinical signs (weight loss).

It is mentioned that hematologic parameters may be abnormal in cats with toxoplasmosis. (For example Nonregenerative anemia, neutrophilic leukocytosis, lymphocytosis, monocytosis, and eosinophilia) (Green 1998). In this study, among the hematologic parameters studied, we saw only leukocytosis that was significant by statistical analysis ( $p = 0.04$ ). Neutrophilia, Lymphocytosis and Eosinophilia were not significant. Also, all biochemical values (BUN, Scr, ALP, ALT and AST) were normal on day 1 and 30 after infection. Results of table 2 showed that although duration of shedding in 7 kittens of group 1 and 2 kittens of group 3 were nearly similar, but intensity (3+ against 1+) and beginning of oocyst shedding (day +7 against day +11) were different and significant by statistical

analysis ( $p=0.02$ ). Clindamycin 10 mg/kg had an inhibitory effect of 71/43% in prevention of oocyst shedding. Results of IFA tests were consistent with shedding of oocysts, i.e., kittens that shed oocysts, had higher titers of antibody. The highest rates of antibody titers were in kittens No. 2 (1/640), 3 (1/1280), 5 (1/1280) and 6 (1/640) of group 1. Also the highest rates of oocyst shedding were in kittens No. 3, 5, 6 and 7 of group 1. Having low antibody titers, none of kittens of groups 2 and 4 that fed Clindamycin 20 mg/kg and Monensin 0.02 % respectively, shed any oocyst (Table 3).

It shows that some stages of oocyst development probably be produced in intestines of kittens, because kittens of these groups had low antibody titers. It may be presumed that some drug effects might have been present on the sporozoites and stages A, B, C, D and E of the parasite. The entire enteroepithelial cycle of *Toxoplasma gondii* can be completed within 3 to 10 days after ingestion of bradyzoites of *Toxoplasma gondii* (Dubey 2002). In the present study, oocyst shedding in kittens of group 1 began nearly 1 week after feeding with infected brain tissues (bradyzoites), and continued for 8 to 9 days after. Two of 7 kittens of group 3 shed oocyst on day 11 after infection which lasted for 1 week (Table 2).

This result is in agreement with that of (Frenkel *et al* 1982) who reported (100%) efficacy of Monensin 0.02% incorporated in dry cat food against *Toxoplasma gondii* (M-7741). Oocyst shedding was completely suppressed when Monensin was given starting -2 to +1 days after infection and continued for from 6 to 15 days. whereas at 0.01% , three out of four kittens shed oocysts. It was demonstrated that body weights of 50% of kittens receiving 0.02 % Monensin increased during *toxoplasma* infection, whereas all kittens on drug-free food lost weight (Frenkel *et al* 1982). In the present study, all kittens of group 1 had low weight compared with other groups. Kittens on drug food had gain weight (Frenkel *et al* 1982). The results from studies on the

preventative effects of Clindamycin and Monensin in kittens with *Toxoplasma gondii* (Tehran strain) revealed that continuous medication of the cat foods with these drugs daily can reduce the risk of infection with *Toxoplasma gondii*. This suggests the possible use of medicated food in cats that hunt intermittently but obtain a substantial part of their food at home. Inhibitory effects of these drugs, in this study are a positive and welcome development in prevention of Toxoplasmosis, because Clindamycin and Monensin are available all – year round of world. Use of such medicated food can minimize risks of infection for pregnant women and small children from a pet cat defecating in soil near home. For greater safety, stray cats should be controlled. To achieve maximal protection, the risk from raw meat must also be minimized by cooking it adequately, and by washing ones hands after handling it.

#### Acknowledgements

We thank Mr. Taheri for excellent technical assistance in IFA test and Mr. Kanani for his technical assistance.

#### References

- Burney, D.P., Lappin, M.R., Spiker, M. and McReynolds, L. (1999). Detection of *Toxoplasma gondii* parasitemia in experimentally inoculated cats. *Journal of Parasitology* 85 (5): 947- 951.
- Cook, A.J.C., Gilbert, R.E. and Buffolano, W. (2000). Sources of *Toxoplasma* infection in pregnant women: European multi centre case-control study. *British Medical Journal* 321: 142-147.
- Davidson, M.G., Lappin, M.R., Rottman, J.R., Tompkins, M.B., English, R.V., Bruce, A.T. and Jayawickrama, J. (1996). Paradoxical effect of Clindamycin in experimental, acute toxoplasmosis in cats. *Antimicrobial Agents and Chemotherapy* 40 (6): 1352-1359.
- Dubey, J.P. and Yeary, R.A. (1977). Anticoccidial Activity of 2-Sulfamoyl-4, 4-Diamino diphenyl

- sulfone, Sulfadiazine, Pyrimethamine and Clindamycin in cats infected with *Toxoplasma gondii*. *The Canadian Veterinary Journal* 3: 51-58.
- Dubey, J.P. (1996). Strategies to reduce transmission of *Toxoplasma gondii* to animals and humans. *Veterinary Parasitology* 64 (1- 2): 65- 70.
- Dubey, J.P. (2001). Oocyst shedding by cats fed isolated bradyzoites and comparison of infectivity of bradyzoites of the VEG strain *Toxoplasma gondii* to cats and mice. *Journal of Parasitology* 87 (1): 215-219.
- Dubey, J.P. (2002). Tachyzoite – induced life cycle of *Toxoplasma gondii* in cats. *Journal of Parasitology* 84: 713-717.
- Frenkel, J.K. and Smith, D.D. (1982). Immunization of cats against shedding of *Toxoplasma* oocysts. *Journal of Parasitology* 68 (5): 744- 748.
- Fernkel, J.K. and Smith D.D. (1982). Inhibitory effects of Monensin on shedding of *Toxoplasma* oocysts by cats. *Journal of Parasitology* 68 (5): 851-855.
- Green, C.E. (1998). *Infectious diseases of the dog and cat* (2<sup>nd</sup> edn.). Pp: 493-503. Elsevier Science Health Publication Ltd.
- Hill, D. and Dubey, J.P. (2002). *Toxoplasma gondii*: transmission diagnosis and prevention. *Parasite Biology, Epidemiology, and Systematic Laboratory*. Pp: 2075-2350. Animal and Natural Resources Institute, Agricultural Research Service, U.S. Department of Agriculture, Beltsville, Maryland, USA.
- Lappin M.R. (1996). Feline toxoplasmosis: interpretation of diagnostic test results. *Seminars Veterinary Medicine and Surgery (small animal)* Pp: 11.
- Melton, M.L. and Sheffield, H.G. (1975). Activity of the anticoccidial compound, asalocid against *Toxoplasma gondii* in cultured cells. *Journal of Parasitology* 61: 713-717.
- Rommel, M.T., Schnieder, H.D. and Krause, J. (1988). Trials to Suppress the Formation of Oocysts and Cysts of *Toxoplasma gondii* in cats by Medication of the Feed with Toltrazuril. *Veterinary Parasitology* 22: 21- 35.