

Studies on incidence and pathology of neoplasms of reproductive system of cull laying

Mahjoor*¹, A.A., Nili², H.

1. Pathobiology Department, School of Veterinary Medicine, Islamic Azad University, Kazeroon Branch, Kazeroon, Iran

2. Clinical Sciences Department, School of Veterinary Medicine, Shiraz University, Shiraz, Iran

Received 11 Mar 2006; accepted 03 Aug 2006

ABSTRACT

This study was performed to determine the incidence and anatomo-pathological aspects of the reproductive system tumors in commercial laying hens. Post mortem examination of 1041 laying hens revealed neoplasms of the ovaries and the oviduct in 52 (4.99%) cases. From these, ovarian adenocarcinoma was found in 14 cases, granulosa cell tumor in 7 cases, theca cell tumor in 1 case and Marek's disease in 3 cases. Oviductal adenocarcinoma was observed in 17 cases, adenomatosis in 2 cases and leiomyoma in 8 cases. The macroscopic and light microscopic characteristics of these tumors were reported in details.

Keywords: Neoplasm, Cull laying hens, Reproductive system

INTRODUCTION

Neoplasms involving the Reproductive tract are common in fowl (Campbell 1969). In one study, these lesions accounted for up to 4.3% of all reproductive disorders (Keymer 1980). These tumors have been reported from various avian species including Budgerigar (Reece 1992), Duck (Rigdon 1972) and turkeys (Beasley *et al* 1986). Egg retention, concurrent cysts, ascites and herniation are common sequelae to reproductive tract neoplasia (Ritche *et al* 1994). The classification of gonadal tumors of birds according to the system commonly used in

mammalian pathology can be difficult, so some authors prefer not to define them further than gonadal tumors (Blackmore 1966). Comprehensive descriptions of these tumors which are more prevalent in domestic fowls are available (Fredrikson & Helmbodt 1991, Reece *et al* 1996). Some investigator revealed significant association between the presence of magnum tumors and rate of laying, these interesting findings suggest that regression of the oviduct is accompanied by tumors regression (Fathalla 1971, Anjum *et al* 1989b). A survey of the literature indicates an increasing occurrence of the magnum tumors of the domestic fowls since 1960s. The increase in the prevalence of the tumor coincides with continued selection of fowl

* Author for correspondence E-mail: mahjoor@shirazu.ac.ir

for high egg production (Anjum *et al* 1989a, Goodchild & Cooper 1968). There is a general trend for relatively low, moderate and high prevalence of the oviduct tumor in specific pathogen free (SPF) hens, layer breeder and commercial layer hens, respectively. It seems that as laying is under the influence of steroid sex hormones, the prolonged exposure of the oviduct to these hormones could contribute to the development and growth of magnum tumors (Anjum *et al* 1989a).

There are some similarities between ovarian cancer in birds and human. These include age dependent occurrence, gross and microscopic features, models of spread, and sharing similar antigens between human & hen ovarian cancers. The following antigens are reported to have cross-reaction: cytokeratin AE1/AE3, Panc/ tokeratin, Lewis Y, CEA, Tay 72, diffuse antigen like CEGFR and erb2. Immunohistochemical analysis of spontaneously arising ovarian tumours in hens revealed that PCNA, p27 and TGF-alpha, surrogate endpoint's in ovarian chemoprevention trials in humans, are also cross-reactive with the chicken carcinomas. Additionally, ovarian cycles takes only 28 hours in chickens, so 24 ovarian cycles can occur during one human ovarian cycle. The main problem of studying ovarian cancer in medical research is lack of a proper animal model (Barnes *et al* 2002). All of the advantages and similarities mentioned above, hens could be a suitable and relatively inexpensive for ovarian cancer research. Furthermore, identification of a spontaneously-arising adenocarcinoma model of ovarian cancer will be extremely useful for studying both chemopreventive and chemotherapeutic agents used in human cancer therapy (Rodriguez-Burford *et al* 2001).

The aim of this study was to determine the incidence and anatomic-pathologic aspects of reproductive organ tumours in laying chickens.

MATERIALS AND METHODS

1041 cull laying birds were collected from commercial flocks in Fars province of Iran. The study was performed in a period from November 2002 to March 2004. All birds were given a throughout necropsy examination. The gross status of the ovary, oviduct, peritoneal cavity and the pathological findings were recorded. Appropriate samples were preserved in 10% buffered formalin solution for histopathological examination. The suspected oviducts were removed and opened at selected intervals along their lengths to allow proper penetration of the fixative. Routine histological techniques were used for tissue section preparation. Sections were stained with haematoxylin and eosin, periodic acid schiff, Van Gieson and Masson's trichrome using standard techniques. The neoplasms were classified according to a histogenic system similar to that used by Campbell 1969 and Reece 1992.

RESULTS

Out of 1041 laying hens examined at post mortem, 52 (4.99%) cases exhibited gross lesions of reproductive tumors (Table 1).

Adenocarcinoma of the ovary. Fourteen cases of ovarian adenocarcinoma were observed. Multiple pedunculated, white or creamy, firm lobulated tumors with cauliflower-like structures were observed in these cases (Figure 1). In 2 cases a large solid white mass was observed on the ovarian serosal surface.

Histopathological features of the neoplasms were not consistent. The most common arrangement was the acinar pattern formed by a single layer of low columnar or cuboidal nonciliated epithelium (figure 2), but solid and scirrhous patterns were present to some extent in most cases. Epithelial cells were arranged in a variety of patterns including sheets, nests, tubules and acini. The density of the stroma

varied greatly from small amounts of collagen and smooth muscle to prominent fibro-muscular tissue.

Table 1. Incidence of reproductive tract tumors found in 1041 cull laying hens.

Type of the tumor	Number	Tumors %
Adenocarcinoma of the ovary	14	26.92
Granulosa- cell tumor	7	13.46
Theca cell tumor	1	1.92
Marek's disease	3	5.76
Adenocarcinoma of the oviduct	17	33.69
Adenomatosis	2	3.84
Leiomyoma	8	15.38
Total	52	100

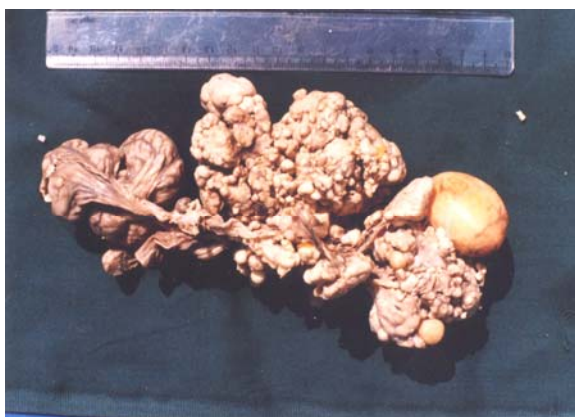

Figure 1. Ovarian adenocarcinoma: White and creamy firm lobulated tumors having a cauliflower like structure could be seen.

In 5 cases massive invasive implants on the surface of the intestine, mesentery, pancreas and the liver were recorded. In these cases the condition was accompanied by severe ascites. These tumors consisted of small granular or nodular tumors up to 1 cm in diameter scattered on the visceral organs and the mesentery (Figure 3). In one case a large neoplasm was found in the abdominal cavity. The ovaries were affected and were generally white or

grayish-white and hard, that in some cases normal ova had developed beside the tumor. Histologically, gland like tubular structures were seen embedded within a fibrous and leiomyomatous stroma. The cells of the tumor were arranged in an alveolar or duct like structure with a large nuclei and sometimes a vacuolated cytoplasm. Mitotic index was moderate.

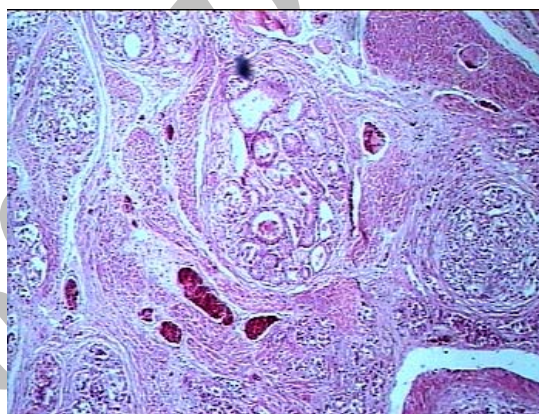


Figure 2. Histopathological view of ovarian adenocarcinoma: Acinar structures that consist of nonciliated cuboidal cells. Lumen of the tubules becomes more obvious towards center of the tumor. (H&E, x120).

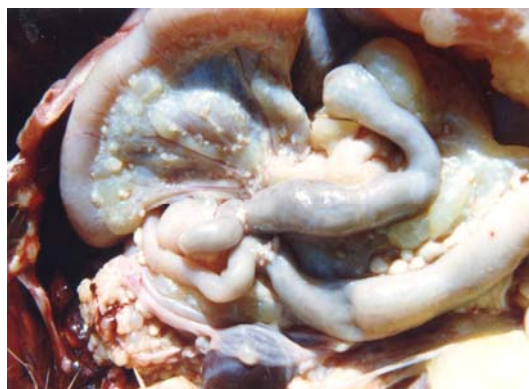

Figure 3. Pearly seeding tumors on the intestinal wall. The ovary is transformed to an irregularly shaped solid neoplasm.

Granulosa-cell tumor. Seven cases had granulosa-cell tumor. In gross appearance, the tumors were yellowish, solid, round multiple

growths with a friable to firm consistency (Figure 4). Haemorrhage and small cysts were occasionally seen. Metastase was not observed. Histologically different structures were recorded. The neoplastic cells were cuboidal to polyhedral with central dark nucleus and granular acidophilic cytoplasm. Mitotic figures were low (0-1 in high power field). Islands of undifferentiated cells with variable sized nuclei embedded in a hyalinized stroma, trabeculated masses of granulosa cells showing rosette formation and aggregation of granulosa cell in a clump pattern were seen to various extent. Gyriform arrangement of the epithelial cells was seen in one case (Figure 5). Alveolar arrangement around small cavity was seen in one case. The stroma varied from fine to dense collagenous bands.

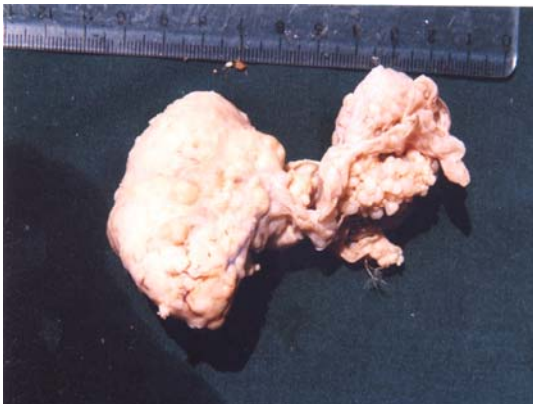


Figure 4: Granulosa cell tumor: Firm solid nodules on the surface of the ovary.

In one case, theca cells were abundant. Grossly, the tumor was a yellowish-pink nodule. Histologically, theca cells were abundant with a vacuolated cytoplasm that seemed to be leuteinized. Eosinophilic polyhedral granulosa cells were seen too, so the tumor was recorded as granulosa-theca cell tumour.

Theca cell tumor: One case was diagnosed as theca cell tumor. Grossly the tumor was a cream-yellowish colored mass that was trabeculated in

cross section. Histologically, tumor cells were fusiform and fibroblast like, with a round to oval nuclei. Fibrous tissue bands were seen scattered in the section (Figure 6).

Marek's disease: Marek's disease involving the ovary was recorded in three ovaries in addition to invariable involvement of the liver, kidney and the spleen. The ovary was enlarged with a grayish discoloration. Histologically, infiltration of lymphoid cells with different size was seen.

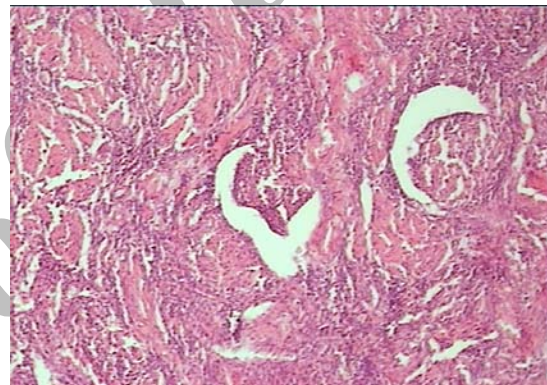


Figure 5: Granulosa cell tumor: Note the gyriform (arrows) arrangement of the epithelium. (H&E, X120).

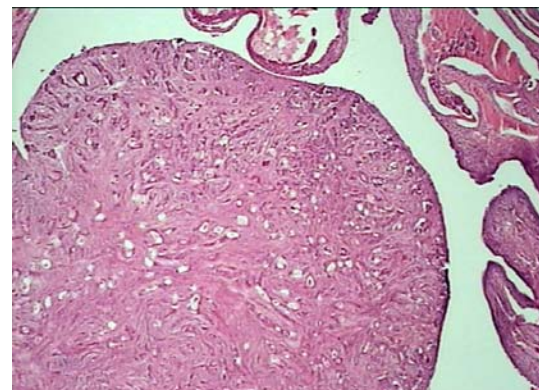


Figure 6: Theca cell tumor: The cells are plump, fibroblastic, that in some part are almost epithelial like. (H&E, X120).

Adenocarcinoma of the oviduct: Seventen cases had adenocarcinoma of the oviduct. The gross macroscopic finding consisted of nodular, firm,

pinkish-white tumors growing in the mucosa measuring between a few millimeters to several centimeters that in some cases were visible from the serosal surface. Individual or clustered sessile adenocarcinomas were seen in 11 cases. Most of the cases had invaded the muscular wall of the oviduct and were visible through the serosal surface and secondary growth was recorded in some cases. Histologically, acinar structures and compact nests of cells were present. The cells were cuboidal to columnar in single row arranged in an acinar and tubular pattern over delicate connective tissue. Mitotic figures were prominent.

Adenomatosis : Adenomatosis of the oviduct were seen in 2 cases. The gross appearance of the tumor was multiple polyps protruded into the oviduct lumen. In the microscopic view the mucosa contained foci of dysplastic glands and compact mass of proliferating epithelial cells protruding in the oviductal lumen were recorded.

Leiomyoma : Leiomyoma was observed in 8 cases. All of these tumors had occurred in the ventral ligament of the oviduct. The tumors were very firm, greyish-white, round to oval circumscribed mass that made the ventral ligament of the oviduct much thicker than normal. The size of the tumor varied from 2 to 10 centimeter. Congestion of the vessels was seen in 3 cases. Histologically, interlocking whorls and bundles of smooth muscle fibers which were separated by fibrous tissue were observed. The tumor cells had an elongated, centrally located nucleus. The amount of fibrous tissue varied from one tumor to another and in different parts of one tumor.

DISCUSSION

This study was designed to identify and to the overall incidence of tumors in the present study was found to be 4.99% Fredrickson (1987) has reported a 32.4% incidence of ovarian and oviductal tumors. Postmortem examination of 5700 carcasses by Gill

and Iyer (1973) revealed 10 cases with primary adenocarcinoma, 1 case with thecoma, 5 cases with granulosa cell tumor, 1 case with granulosa -thecal cell tumor and 14 cases with metastatic growth in mesentery. Leiomyoma of the oviduct and mesosalpinx were recorded in 136 cases. Keymer (1980) had accounted a 4.3% incidence of neoplasia in 1666 adult female birds of 650 different species, belonging to 27 avian orders. Goswami *et al* (1988) in necropsy examination of 412 carcasses found a 4.91% incidence of ovarian and oviductal tumors. Over a ten-year period (1971-81) among 6760 fowls sent for post mortem examination in India, the most common non-leukotic tumours were adenocarcinoma of the ovary (49.3%) (Sriaman 1981). Somnez *et al* (2002) examined 10,475 (16-18-month-old) commercial laying hens from four flocks right after slaughtering in Turkey, and found reproductive organ tumours in 804 (7.67%) of them.

In a study on pathology of the female reproductive tract of domestic fowls in India, the incidence of lymphoid leucosis was 17.4% in the ovary and 5.22% in the oviduct, and that of adenocarcinoma 2.62 and 8.7%, respectively. The other neoplastic conditions observed in the ovary were granulosa cell tumours (1.74%); Marek's disease, papillary adenocarcinoma, papillary cystadenocarcinoma and fibrosarcoma (all 0.87%).cystadenocarcinoma (1.74%) and multiple neoplasias (0.87%) were also recorded in the oviduct (Pradham & Nayak, 1972). Neoplasms were found in 64 of 16000 fowls submitted to routine PM examination between 1962 and 1972 in Iran. The most common neoplasms were fibroma of various organs (12 cases), leiomyoma of ovary and oviduct (17 cases), and adenocarcinoma of the abdominal cavity (13 cases) (Naghshineh & Afnan 1973).

In human medical pathology, changes described as atypical endometrial hyperplasia, adenocarcinoma "in situ" and invasive carcinoma tend to merge into each other. Studies on the domestic fowl and turkeys revealed a similar progression of changes affecting

the magnum of the oviduct (Reece 1992). Goodchild and Cooper (1968) and Campbell (1966) have noted that the incidence of adenocarcinoma of the oviduct was insignificant and the incidence of the tumor in birds kept under modern condition has been low, this is likely due to the discarding hens after their first, or at most during their second year of reproductive cycle. But Anjum *et al* (1989b) indicates an increasing occurrence of magnum tumors of the domestic fowl since 1960 and suggests that increase in the prevalence of the tumor coincides with continued selection of fowl for high production. The hypothesis is supported by a recent study in which administration of medroxy progesterone acetate reduced ovulation as well as the frequency of ovarian adenocarcinoma in the avian model (Barnes *et al* 2002).

Goodchild and Cooper (1968) found 84 (37/7%) of oviducts with macroscopic tumor in a laying hen flock that 65 cases were confirmed histologically as adenocarcinoma. Ilchman and Bergman (1975) in histological examination of 187 tumors from 98 hens (laying birds of various lines) found that highly differentiated tubulo-alveolar adenocarcinoma was present in 95% of the birds, that in 20% it had a scirrhous structure. Adenocarcinoma is reported in different species of birds including Budgerigar, Radjahshel duct (Reece, 1992), Racing pigeon (Chalmers 1986), Domestic turkey (Wasler and Paul 1979), Mauritius kestrel (Cooper 1979), Cockatiel (Stauber 1990), Military macaw (Stoica *et al* 1989), Flamingo (Wadsworth & Jones 1981) and Australian thicknee (Keymer 1980). The macroscopic and microscopic findings of oviductal adenocarcinoma are similar to those reported by Reece (1996) and Anjum *et al* (1989).

Metastatic abdominal adenocarcinoma (peritoneal carcinomatosis) have been reported as common tumors in most surveys of laying hens (Reece 1996, Nobel *et al* 1964). Joest and Ernesti (1915) were the first to state that these types of tumors were metastases of a primary ovarian neoplasm. In all of

the peritoneal carcinomatosis involvement of the ovary was observed that favours the view of Nobel *et al* (1964) who using morphological criteria, reported that 86% of peritoneal carcinomas in the hen originates from the ovary.

However, Haritani *et al* (1985) by indirect immunofluorescence methods showed that all tissue from the peritoneal cavity of hens suffering from adenocarcinoma appeared to contain ovalbumin. Their finding was supported by Kajigaya *et al* (1986) that by assay for oestrogen receptors and ovalbumin, demonstrated that 9 of 10 unknown peritoneal adenocarcinomas originate from the glands of the oviduct (Kajigaya *et al* 1986). Nili (1995) has reported involvement of oviduct in only 3 cases of 15 cases of disseminated peritoneal adenocarcinoma, and suggests that the oviduct was the origin of other cases. In all of our cases, a concomitant of pancreas with peritoneal carcinomatosis was recorded that supports Sahota and Singh (1977) suggestion that considered peritoneal carcinomatosis to be of ovarian origin and stated that because of gravity, the intestinal peristalsis and the inferior most location of the pancreas in the abdominal cavity, the downward spread of implants from the ovary to the pancreas is usual. The macroscopic and histological appearance of adenocarcinoma in this study is similar to that described by Reece (1996) and Randall and Reece (1996). Reece (1996) noted that the cystic acini in some ovarian adenocarcinoma and infundibular adenocarcinoma were lined by flattened adenocarcinoma cells with stretching and flattening of the overlying ciliated epithelium that was similar to one of the cases observed in this study but any type of neoplastic features was not found, so the lesion was considered as cystic hyperplasia.

Granulosa cell tumor is reported in different avian species like Budgerigar (Petraik and Gillmore 1982), Pigeon (Chalmers 1986), Military macaw (Stoica *et al* 1989) and Quail (Griner 1983). Campbell and Appleby (1966) reported four ovarian granulosa cell

tumors out of 351 cases of Neoplasia studied. Metastases of the tumor was not found in this study that supports the study of Fredrickson and Hemboldt (1991), but is opposite to the survey done by Reece (1996) that has reported 18% metastases to the adjacent viscera and Sharma and Kuppusswamy (1974) whom reported metastases of the tumor to the mesentery and small intestine. The macroscopic and microscopic finding of the tumor was similar to that described by Reece (1996) and Fredrickson (1987). Campbell (1969) has described thecal cell tumor as a separate ovarian cell tumor. But Reece (1997) suggests that the existence of separate ovarian thecal cell tumor needs more research. Sahota and Singh (1977) considered thecal cell and granulosa cell tumors as unripe and ripe tumors of mesenchymal cells respectively. Fredrickson and Helmboldt (1991) have reported that high plasma levels of oestrogen occur in hens with large granulosa cell tumors. Normal granulosa cells produce progesterone (Hohnson 1986), whereas theca externa cells normally produce oestrogen (Porter *et al* 1989). This, coupled with the observation of numerous theca glands in "granulosa cell tumors" justifies the binomial descriptor of granulosa theca cell tumor (Reece 1997, Fredrickson 1987). Intracytoplasmic fat vacuulations of theca cell reported by Reece (1996) and Willis (1967) were detected in the present study.

Leiomyoma of the ventral ligament of the oviduct is a common tumor found in most surveys of tumors in laying hen and is also reported from the oviduct in budgerigars. In laying hens an incidence of up to 20% has been recorded in some flocks at slaughter (Riddel 1987). Anjum *et al* (1989a) have reported that the prevalence of leiomyoma in different lines of domestic fowls at the end of their first year of lay varies from 0-60%.

Keymer (1980) has reported a 3.9% incidence of leiomyoma in different avian species. Naghsineh and Afnan (1974) found 17 cases of leiomyoma of ovary and oviduct in 16000 fowls submitted to PM

examination between 1962 and 1972 in Iran. Somnez *et al* (2002) have reported a 7.28% (760 out of 10475) incidence of leiomyoma in laying hen in Turkey. The prevalence of leiomyoma in this study was 0.76%. This discrepancy could be due to different strain susceptibilities and this fact that the tumor does not have any significant effect on normal reproductive function of laying hens unless it becomes large enough to mechanically interfere with egg laying as such the tumor is an incidental finding. As the birds in this study were cull laying hens and the birds in other researches were at slaughter this can be one of the causes of this discrepancy. Otherwise a difference in the prevalence of the leiomyomas has been reported between lines and within families in a line and from this it has been suggested that a hereditary influence is involved. Variation in the prevalence of the leiomyoma between various breeds but consistent prevalence over the years within a line/breed suggest age predisposition (Anjum & Paynel 1988). The macroscopic and microscopic findings of leiomyoma in this study is similar to that has been reported by other researchers (Campbell 1969, Anjum & Paynel 1988). These tumors were not invasive or destructive in nature as recorded by other researchers. (Anjum & Paynel 1988 and Sahota & Singh 1977).

Sahota and Singh (1977) have reported the coincidence of haemangioma with most of the leiomyoma cases and have used the term leiomyoma-haemangiomas. They have noted a large number of blood vessels of different size with slit like lumina among haphazardly arranged muscles. This discrepancy seems to be same as hyperplastic and neoplastic leiomyoma and presence of haemangioma seems doubtful.

References

- Anjum, A.D. and Paynel, N. (1988). Concentration of steroid sex hormones in the plasma of hens in relation

- to oviduct tumors. *British Poultry Science*. 29: 729-734.
- Anjum, A.B., Payne, L.N. and Appleby, E.C. (1989a). Oviduct Magnum tumors in the domestic fowl and their association with laying. *Veterinary Records* 125: 42-43.
- Anjum, A.B., Payne, L.N. and Appleby E.C. (1989b). Oestrogen and progesterone receptors and their relationship to histological grades of epithelial tumors of the magnum region of the oviduct of the domestic fowl. *Journal of Comparative Pathology* 100: 275-286.
- Barnes, M.N., Berry W.D., Straughn, J.M. and Kirby, T.O. (2002). A pilot study of ovarian cancer chemoprevention using medroxyprogesterone acetate in an avian model of spontaneous ovarian carcinogenesis. *Gynecology Oncology* 87:57-63.
- Beasley, J.N., Kloops, A. and Terry, B. (1986). Neoplasms in the oviduct of turkeys. *Avian Disease* 30:433-437.
- Blackmore, D.K. (1966). The clinical approach to tumors in cage birds-I, the pathology and incidence of neoplasia in cage birds. *Journal of Small Animal Practice* 7: 217-223.
- Campbell, J.G. and Appleby E.C. (1966). Tumors in young chicken breed for rapid body growths. *Journal of Pathology and Bacteriology* 92: 77-90.
- Campbell, J.G. (1969). *Tumor of the fowls*, London; William Heinman Medical Book limited. P: 169-212.
- Chalmers, G.A. (1986). Neoplasm in two Racing pigeons. *Avian Diseases* 30: 241-244.
- Cooper, J.F. (1979). An Oviduct Adenocarcinoma in a Mauritius Kestrel (*Falco Punctatus*). *Avian Pathology* 8: 187-191.
- Fathalla, M.F. (1971). Indecent ovulation a factor in ovarian neoplasia. *Lancet* 2(77) 17: 163.
- Fredrikson, T.N. (1987). Ovarian tumors of the hen. *Environmental health perspectives*. 73: 35-51.
- Fredrikson, T.N. and Helmboldt, C.F. (1991). Tumors of Unknown etiology In: Calnek BW, Barnes CW, Beard WM., McDougald LR, Saif Y.M. *Disease of poultry* (10th edn.). Pp:459-470. Iowa state University press, Ames.
- Fredrikson, T.N. (1987). Ovarian tumors of the hen. *Environmental health perspectives*. 73: 35-51.
- Gill, B.S. and Iyer, P.K.R. (1973). Neoplastic disease in poultry, a pathological study. *Indian Vet. J.* 50(2): 129-135.
- Goodchild, W.M. and Cooper, D.M. (1968). Oviduct adenocarcinoma in laying hen. *Veterinary Records*. 82: 389-390.
- Goswami, S., Chaudhury, M. and Matti, A. (1988). Reproductive disorders of domestic hen Indian. *Veterinary Science* 65: 747-749.
- Griner, L.A. (1983). *Pathology of Zoo animaly*. Pp:..... Zoological Society of Sandiege, USA.
- Haritani, M.H., Kajigaya, T., Akashi, M., Kamemura, M., Isoda, M. and Katoc, J. (1985). A study on the origin of adenocarcinoma in fowls using immunohistological technique. *Avian Dis.* 28: 1130-1134.
- Hohnson, A.L. (1986). Reproduction in the female. In: Sturkie, P.N. *Avian Physiology* (4th ed) . Pp: 403-431.....
- Ileham, G. and Bergman, V. (1975). Histological and electron microscopical studies on adenocarcinoma of hens. *Arch. Exp. Veterinaer. Med.* 29:897-907.
- Joest, E., Ernesti, S. (1915). Untersuchunge uber spontane. *Universital Zu Berlin* 5(1): 29-63.
- Kajigaya, H., Kamemura, N., Tanahara, N., Ohta, A. and Isoda, M. (1986). The influence of celomic Membrances and a tunnel between Celomic Cavitis on Cancer Metastases in Poultry. *Avian Dis* 31 (1): 176-186.
- Keymer, I.F. (1980). Disorders of the avian female reproductive system. *Avian Patho* 9 (3) :405-419.
- Naghshineh, R. and Afnan, M. (1973). Incidence of neoplastic diseases other than leukosis complex in domestic fowl in Iran. *World's Poultry Science Journal* 30(3):217-219.
- Nili, H. (1997). Follicular atresia and ovarian diseases in the domestic chicken. *PHD Thesis*, Queensland university, Australia.
- Nobel, R.A., Neuman, F. and Dison, M.S. (1964). A Histological study of peritoneal carcinomatosis in the laying hen. *Avian Dis* 8: 513-522.
- Petrak, M.L. and Gilmore, C.L. (1982). *Neoplasms in Disease of cage and Aviary birds* (2nd edn.). Pp: 606-637. Philadelphia, Lea & Febiger.
- Porter, T.E., Hargis, B.M., Silsby, J.L and El- Halawani M.E. (1989). Differential steroid production between theca interna and theca externa cells. *Endocrinology* 125: 109-116.
- Pradham, H.K. and Nayak, B.C. (1972). Studies on pathology of the female reproduction tract of domestic

- fowls. 1. Naturally occurring oophoritis and salpingitis. *Indian J. Poultry Sci.* 7: 45-49.
- Randal ,C.J. and Reece R. (1996). *A color atlas of Avian histopathology* London ;Mosby wolf Pp: 204-210.
- Reece, R.L. (1992). Observation on naturally occurring neoplasms in birds in the state of Victoria, Australia. *Avian Pathology* 21: 3-38.
- Reece, R.L. (1996). Some observations on naturally occurring neoplasms of domestic fowls in the state of Victoria, Australia. *Avian Pathology*. 25: 407-443.
- Reece R.L. (1997). Neoplastic disease Tumors of unknown etiology. In:Calnek BW,Barnes CW,Beard WM,,McDougald LR,Saif Y.M. *Disease of poultry* (10th edn.). Pp.489-510. Iowa state University press, Ames.
- Ridell, C. (1987). *Avian Histopathology*. American Association of Avian Pathologists, Kennett Square, Pennsylvania. Pp 83-87.
- Rigdon, R.H. (1972). Tumors in the duck, Family Anatidae: a review. *Journal of the National Cancer Institute*. 49 (2): p467-476.
- Ritchie, B.W., Harrison, G.J. and Harrison, L.R. (1994). *Avian Medicine, principles and application*, Pp: 758-774. Wingers Publishing Inc:.
- Rodriguez-Burford C., Barnes M.N. and Berry, W. (2001). Immunohistochemical expression of molecular markers in an avian model: a potential model for preclinical evaluation of agents for ovarian cancer chemoprevention. *Gynecology Oncology* 81:373-379
- Sharma S.H. and Kuppuswany P.B. (1974). Granulosa-cell tumor in Poultry the *Indian Vet. J.* Pp:30.
- Sahota, P.S. and Singh, B. (1977). A note on neoplasms involving the female genital system of domestic fowl. *Indian J. Anim. Sci.* 47(11): 761-765.
- Somnez, G., Ozyigit, M.O. and Kahraman, M.M. (2002). The incidence and pathology of reproductive organ tumors in chickens. *Turk Veterinerlik ve Hayvancilik Dergisi* 26 (1): 27-33.
- Sriaman, P.K., Ahmed, S.K., Nalin, N.R.G. and Ruo P.R. (1981). Neoplasia in chickens and ducks. *Indian J. Poul. Sci.* 16: 400-436
- Stauber, E. (1990). Polyostotic hyperostosis associated with a oviductal tumor in a Cockatiel. *JAVMA* 196: 934-940
- Stoica, G., Russo, E. and Hoffman, J.R. (1989). Abdominal tumor in a military macaw. *Laboratory Animals* 18 (5): 17-20.
- Walser, M.M. and Paul, P.S. (1979). Ovarian adenocarcinomas in domestic turkeys. *Avian Pathology* 8 (4): 335-339.
- Willis, R.A. (1967): *Pathology of tumors*. (4th edn.). Pp: 507. Butterworths, London.
- Williamson, M.E., Leestma, J.E., Black, W.C. and King, D.W. (1968). *Histologic patterns in tumor pathology*. (1st edn.). Pp: 52, Hober medical division, Harper and Row , New york.
- Wodsworth P.F. and Jones D.M. (1981). An ovarian adenocarcinoma in a greater Flamingo. *Avian Pathology* 10: 95-99.