



## Ultrastructural and molecular studies on fat and thin macrocysts of *Sarcocystis* spp. isolated from naturally infected goats

Motamedi<sup>1,2</sup>, Gh.R., Dalimi<sup>\*1</sup>, A., Aghaeipour<sup>3</sup>, K., Nouri<sup>4</sup>, A.

1. Department of Parasitology, Faculty of Medical Sciences, University of Tarbiat Modares, Tehran, Iran.

2. Department of Parasitology, Razi Vaccine & Serum Research Institute, Karaj, Iran

3. Department of Biotechnology, Razi Vaccine & Serum Research Institute, Karaj, Iran

4. Department of Electron Microscopy, Razi Vaccine & Serum Research Institute, Karaj, Iran

Received 05 Aug 2010; accepted 10 Oct 2010

---

### ABSTRACT

There is considerable confusion concerning the structure and synonymy of macroscopic sarcocysts in goats. In the present work, ultrastructural and molecular study on fat and thin macrocysts of *Sarcocystis* isolated from naturally infected goats were investigated. Two forms of macrocystic sarcocysts were collected from fresh oesophagus, diaphragm, skeletal muscles and heart of slaughtered goats in abattoirs of Tehran and Ghazvin provinces of Iran. Then ultrastructural and molecular studies were carried out contemporaneous using PCR technique and transmission electron microscope respectively. Based on morphological examinations both cysts differ in shape with naked eye but they had the same wall structure with electron microscopy study. The 18S rRNA amplification by PCR showed a 637-bp band for both forms. The results of sequencing of PCR product of the cysts indicated these two kinds of cysts were identical to each other and also to *Sarcocystis moulei*. The present result, suggests that fat and thin cysts are the same and identical species.

**Keywords:** *Sarcocystis moulei*, goat, fat and thin sarcocyst, ultrastructure, PCR, Iran

---

### INTRODUCTION

*Sarcocystis* is a worldwide distributed apicomplexan parasite. It is found in many domestic and wildlife species. It has an obligatory two-host life-cycle. An intermediate (herbivore) and a definitive (carnivore) host must be present for the completion of the life cycle. Omnivores, such as humans serve as both intermediate and definitive

hosts. It is considerable veterinary, economic and public health importance (Dubey *et al* 1989). It is composed of about 130 species and causes a zoonotic disease (Li *et al* 2002). Mature sarcocysts of each species vary in size from microscopic to macroscopic, however these features vary with the age of the sarcocyst and the host cell type (Fayer *et al* 2004, Yang *et al* 2002, Barham *et al* 2005). In goats three species named; *Sarcocystis capracanis* (Fisher, 1979), *Sarcocystis hircicanis* (Heydron & Unterholzner 1983), both cause microcyst and transmitted by dogs as final hosts and *Sarcocystis*

---

\*Author for correspondence. Email: dalimi\_a@modares.ac.ir

*moulei* (Neveu-Lemaire 1912), that produce macrocyst have been reported. Two distinct forms of macrocysts of *Sarcocystis moulei* were reported as fat cysts appeared large, thick, ovoid and round in shape and thin cysts were small and slender. In the past *Sarcocystis* species have been distinguished on the basis of the structure of the wall of the cyst that typically develops in the striated muscle of the intermediate hosts. The conventional methods of distinguishing the different *Sarcocystis* species are by observing the structure of the cyst wall under light and electron microscopy. However these methods are not suitable, sensitive and reliable for routine identification. There is considerable confusion concerning the structure and the synonymy of the macroscopic sarcocysts in goats and problems in *Sarcocystis* diagnosis and distinctive physical features such as overall size, presence or absence of septa. These features vary with the age of the sarcocyst, the host cell type and the method of fixation. So, in recent years molecular techniques were applied as an epidemiological and diagnosis tool to determine species of the agents involved in the infection (Costa da Silva *et al* 2009). On the other hand the information on the details of cysts wall and molecular study for goat sarcocysts are scarce and only few details of their ultrastructure were known yet. In addition, there is no report concerning combine use of E.M and molecular techniques for comparison of macroscopic cysts in goat. So, the present study was designed, based on ultrastructure of cyst wall and molecular characters of fat and thin macrocysts of *Sarcocystis* isolates from naturally infected goat. The main aim of the present study was to determine genetic variation among fat and thin macrocysts by analysis of their DNA sequences and to develop a routine method for identification *Sarcocystis* species.

## MATERIALS AND METHODS

**Animals.** In Iran the domestic goat, *Caprahircus*, in both milk and wool producing varieties, was

probably domesticated from the wild goat (*Caprahircus aegagrus*). The caprid population has been estimated around 12.5-22 millions head. There are 7 breeds of domestic goats, which are: Adany, Arab, Morghoz (kurdi), Lori, Raini, Najdi, Tali (Sahely). The main breeding area of Arab goat in Iran is Tehran. It comes in black and dark brown colors. Both males and females have 2 long twisted horns. The main use of this breed is for milk.

**Sample collecting.** The muscle samples were taken from the fresh oesophagus, diaphragm, skeletal muscles and heart of slaughtered goats in abattoirs of Tehran and Ghazvin provinces, Iran. The samples were tagged according to each organ. Collected samples of each organ were examined by naked eye for macrocyst. Specimens containing cysts were separated, the cysts excised from the tissue and collected in a petri dish containing 0.9% NaCl. The cyst wall disrupted for releasing the bradyzoites from the sarcocysts. Then one drop of solution poured on a slide and examined by light microscope to demonstrate the bradyzoites. For detection of microcystic sarcocysts in muscles, small pieces of muscle was divided into a smaller portion for the squash and pepsin digestion for the detection and verification of bradyzoites (Odening 1996).

**Squash technique.** Squash technique was used for detection of bradizoites, briefly, pieces of sample and some isolated cysts were squashed between a cover-glass and slide, then examined unstained specimens using a light microscope (Odening 1996).

**Pepsin-hydrochloric acid digestion.** 20g of infected organs were incubated (20 min at 40 °C) in 50ml of acid-pepsin solution (2.6g pepsin, 5g NaCl, 7ml HCl 1M, 993ml distilled water). This suspension was filtered through a 53µm sieve, then centrifuged at 2000g for 5min and sediment suspended in 0.5ml of distilled water. A drop of this solution was examined for the presence of

bradyzoites under a light microscope (Fischer *et al* 1998).

**Electron Microscopy.** Small pieces of infected muscles were washed in 0.9% NaCl, then fixed in the buffered glutaraldehyde (4%) and prepared to examine with transmission electron microscope. The samples were washed in phosphate buffer (0.2M, PH=7.2) three times. Then post fixed in Osmium tetra-oxide (2% w/v, for 2hours), dehydrated in ethanol (30% - 100%), transferred to propylene oxide (one hour) and embedded in Epoxi Resin (EPON812). After polymerization (72hours at 60 °C), semi-thin and ultra-thin sections were cut with a Om U3 (C.Reichert, Austeria) microtome. Semi-thin sections were stained with toluidine blue and examined with light microscope. Ultra-thin sections were stained with uranyl acetate and lead citrate, and then examined with (PhilipsTEM400) transmission electron microscope.

**Molecular study.** Macrocysts were minced or disrupted for releasing the bradyzoites from the cysts. The bradyzoites were separated from host debris by filter and centrifugation. Cleaned zoites were pelleted in small conical tubes and held frozen at -20 °C until usage (Costa da Silva *et al* 2009, Dalimi *et al* 2008). Total DNA was extracted from positive samples using DNA Purification Kit (DNP<sup>TM</sup>KIT, CinnaGen Inc., Iran) according to the manufacturer's instruction. The DNA concentration and purity was measured with a Nano drop (ND 1000) spectrophotometer. The extracted DNA was kept at -20 °C until usage. Polymerase chain reaction (PCR) was used to amplify partial sequence of small subunit ribosomal RNA (18S rRNA) gene sequences of goat *Sarcocystis*. Forward and reverse primers were selected from data on domestic animals *Sarcocystis* published sequences in Gene bank. The nucleotides of primers are as follow:

F-5' GCA CTT GAT GAA TTC TGG CA 3'

R-5' CAC CAC CCA TAG AAT CAA G 3'

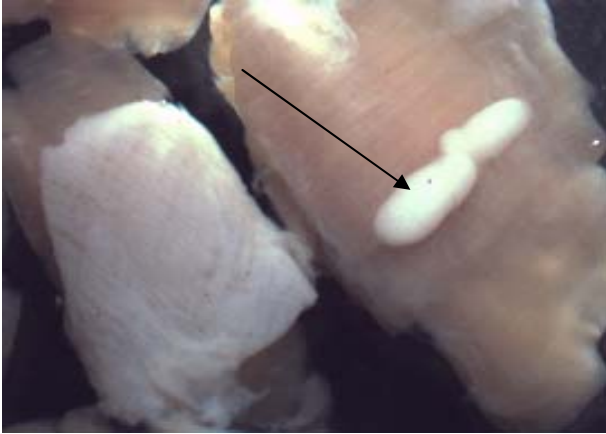
The PCR was performed (30µl reaction volume) using 1µl (10 pM) of each primer, 0.5µl *Taq*

polymerase, 0.5µl dNTP, 2µl MgCl<sub>2</sub>, 10µl (0.1 dilution) DNA, 3µl buffer 10x and 12µl distilled water. Reactions were carried out on an Eppendorf Master Cycler Gradient (Germany) thermal cycler. A preliminary denaturation at 94 °C for 5 min. and the remaining PCR steps were 35 cycles at 94 °C (2 min), 57 °C (30 sec.), 72 °C (2 min), with a single terminal step at 72 °C (5 min). The PCR products were analyzed using agarose gel electrophoresis and purified by the PCR Purification Kit (Roche), following the manufacturer's instructions. The PCR products were transmitted into a pTZ57R/T plasmid. Extraction of plasmid and cloning were carried out by Plasmid Mini Extractin Kit (Bioneer<sup>®</sup>, Republic of Korea) and Ins TAclone<sup>TM</sup> PCR Cloning Kit (Fermentas<sup>®</sup>) respectively following the manufacturer's instructions. The comparison of the obtained sequences with the GenBank was performed using Blast program and DNAMAN software.

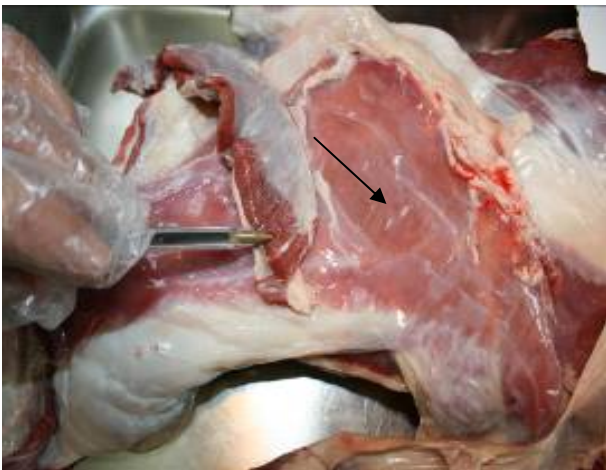## RESULTS

No microcysts were found in any of the samples obtained from goats. But two types of macrocysts of *Sarcocystis* were isolated from them. The macrocysts were milky-white in appearance and round to ovoid with a length of about 3-12 mm. Two distinct forms of macrocysts were identified as fat and thin. The fat cysts were large, thick, ovoid and round 12 x 5.7mm (Figure 1). Thin cysts were small, slender and more frequent than the fat cysts 3 x 1.3mm (Figure 2). In squash preparations the bradyzoites were ovoid with size of 12 x 4 µm. The ultrastructure of primary wall in fat cyst was folded and giving rise to many cauliflower-like protrusions. The dense ground substance within the cauliflower-like protrusions contained numerous solid filaments. Just below the primary cyst wall the ground substance was very broad containing numerous spherical, dense particles (Figure 3). The structure

of thin cyst was slim and slender and appeared to grow mainly longitudinally.



**Figure 1.** Fat macrocyst of *Sarcocystis* isolated from goats (arrow)



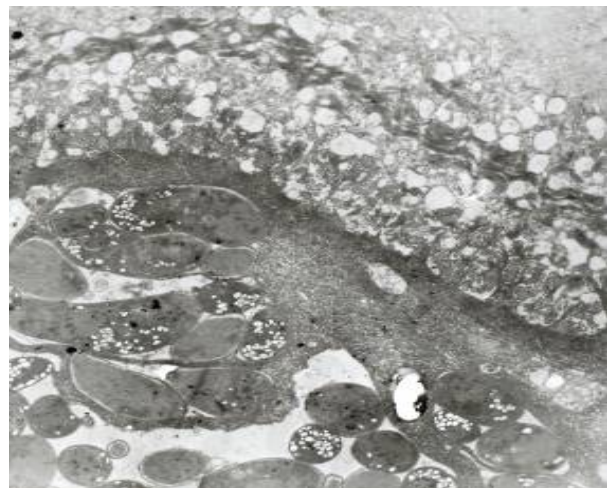
**Figure 2.** Thin macrocyst of *Sarcocystis* isolated from goats (arrow)

On the basis of morphological examination thin cysts were differed in shape, but according to wall thickness and structure, it is similar to fat cysts (Figure 4). The PCR products expected band length were 637 bp for all samples (Figures 5 & 6). The PCR products were cloned in a pTZ57R/T successfully and sequenced. Sequences of cloned PCR products of thin and fat cysts were shown in (Figures 7 & 8). The genetic sequencing of the cloned PCR products of two forms sarcocysts were identical. The comparison of the obtained sequences with those in the GenBank using blast program were

showed to be identical to *Sarcocystis moulei* (relativity ~ 98%).



**Figure 3.** Cell wall of fat macrocyst in goat

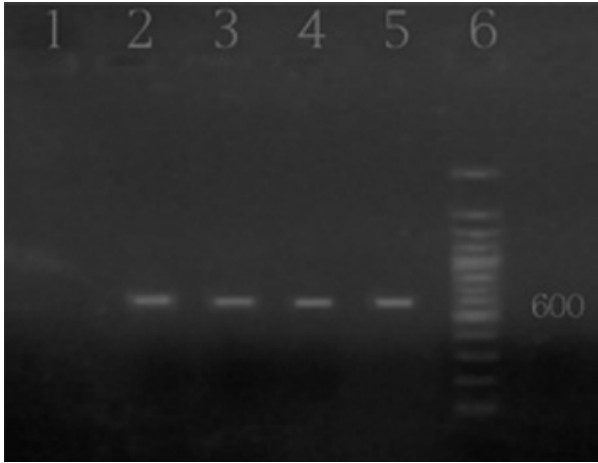


**Figure 4.** Cell wall of thin macrocyst in goat

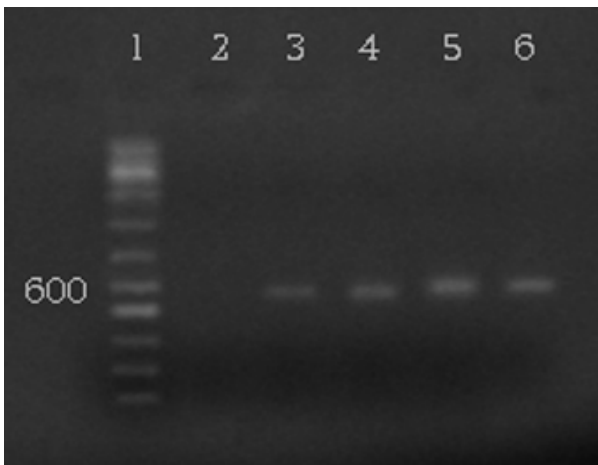
## DISCUSSION

Three *Sarcocystis* species have been reported in goats, *Sarcocystis capracanis*, *Sarcocystis hircicanis*, that both cause microcyst and *Sarcocystis moulei* that produce macrocyst. In the present study no microcysts were found in any of the samples obtained but only macrocyst found in the goats of cyst has been reported in some countries including Swiss, Siberia, Egypt, India and Iraq (Dubey *et al*

1989, Niederhausern 1873, Moule 1888, Rafaii et al 1980, Ghaffar et al 1989, Braham et al 2005).



**Figure 5.** PCR- Products for fat macrocyst isolated from goat. 1-Uninfected tissue (Negative control). 2-Goat Fat macrocyst. 3-Goat Fat macrocyst. 4- Goat Fat macrocyst. 5- Goat Fat macrocyst. 6- DNA size marker (100 bp Ladder).



**Figure 6.** PCR- Products for thin macrocyst isolated from goat. 1- DNA size marker (100 bp Ladder). 2- Uninfected tissue (Negative control). 3- Goat thin macrocyst. 4- Goat thin macrocyst. 5- Goat thin macrocyst. 6- Goat thin macrocyst.

Generally, all sarcocysts with field origin were reported as macrocysts (Tenter 1995), i.e. in water buffalo *S. fusiformis* (up to 32 mm long), in cattle *S. hirsuta* (up to 8 mm long), in sheep *S. gigantea* (up to 10 mm long). The macrocysts in domestic goats are also transmitted by cats. There is considerable confusion concerning the structure and the synonymy of macroscopic sarcocysts in goats (Dubey et al 1989). The first description of

macrocyts measuring up to 14 mm long and up to 7 mm wide in a Swiss domestic goat have been reported by Niederhausern (1873). Then, *S. moulei* was reported by Moule (1888), but his description of sarcocysts is too vague for identification. Matschulski & Miskaryan (1958) reported sarcocysts up to 7.5 mm long and up to 2.5 mm wide (*S. orientalis*) only in wild mountain goats of Siberia (*Capra sibirica*), and not in domestic goats (*Capra hircus*) (Dubey et al 1989). *S. caprifelis* was described by El-Rafaii et al (1980) in domestic goats of Egypt. According to his brief note, the sarcocysts had a thin or smooth wall with many fibrils, and the infection was successfully transmitted to cats. Braham et al (2005) reported the macrocysts up to 17 mm long from domestic goats in Iraq. They observed two forms of macrocysts of *Sarcocystis* in goat muscle. Firstly, fat cysts were thick, round in shape and seemed to grow in length and width with a round ovoid shape, up to 14 mm long and up to 7 mm wide and were exclusively found in the oesophagus. Secondly, thin cysts those were less frequent than the fat cysts, slim, slender and appeared to grow mainly in length, were commonly seen in the oesophagus, diaphragm and skeletal muscles. They were somewhat smaller than fat cysts with a mean length of 3.6 mm and width of 1.1 mm. They have proposed that, fat and thin macrocysts may represent different species or subspecies. Morphologically we observed two forms of macrocysts of *Sarcocystis* in goat muscle samples. The fat cysts were large, thick, ovoid and round 12 x 5.7mm and thin cysts were small, slender and more frequent than the fat cysts 3 x 1.3mm. This finding is nearly similar to the report of Braham et al (2005). Based on morphological examination both cysts differ in shape with naked eye but ultra structure of their primary cyst wall was identical. In addition, the 18S rRNA PCR products (637 bp) were sequenced and blasted to GenBank database at NCBI. Both thin and fat cysts data and pattern of RFLP were identical and they showed the

GCACCTTGATGAATTCTGGCATGATTTTCATCCTAATAATAATATATTATTATATTAGGTTGATTCTAGTATAATAAT  
 ATTTATTATTATGGGGATGACAGTTACTTTGAGAAAATTAGAGTGTGGTGAAGCAGGCTTTTGTTCCTTGAATACTG  
 CAGCATGGAATAACAATATAGGATTTTCGGTCTATTATTTTGTGGTTTTTCTGTAGGA<sup>T</sup>TGAAATAATGATTAAT  
 AGGGACAGTTGGGGGCATTCGTATTTAACTGTCAGAGGTGAAATTCCTTAGATTTGTTAAAGACGAACTACTGCGAAA  
 GCATTTGCCAAAGATGTTTTTCAATTAATCAAGAACGAAAGTTAGGGGCTCGAAGACGATCAGATAACCGTCGTAGTCTT  
 AACCATAAACTATGCCGACTAGAGATAGGAAAATGTCACATTGTTGACTTCTCCTGCACCTTATGAGAAATCAAAGT  
 CTTTGGGTTCTGGGGGGAGTATGGTCGCAAGGCTGAAACTTAAAGGAATTGACGGAAGGGCACCACCAGGCGTGGAG  
 CCTGCGGCTTAATTTGACTCAACACGGGGAACTCACCAGGTCCAGACATGGGAAGGATTGACAGATTGATAGCTCT  
 TTCTTGATTCTATGGGTGGTG

**Figure 7.** Partial sequence of small subunit ribosomal RNA (18S rRNA) gene of fat cyst isolated from goats

GCACCTTGATGAATTCTGGCATGATTTTCATCCTAATAATAATATATTATTATATTAGGTTGATTCTAGTATAATAAT  
 ATTTATTATTATGGGGATGACAGTTACTTTGAGAAAATTAGAGTGTGGTGAAGCAGGCTTTTGTTCCTTGAATACTG  
 CAGCATGGAATAACAATATAGGATTTTGGTCTATTATTTTGTGGTTTTTCTGTAGGA<sup>C</sup>TGAAATAATGATTAAT  
 AGGGACAGTTGGGGGCATTCGTATTTAACTGTCAGAGGTGAAATTCCTTAGATTTGTTAAAGACGAACTACTGCGAAA  
 GCATTTGCCAAAGATGTTTTTCAATTAATCAAGAACGAAAGTTAGGGGCTCGAAGACGATCAGATAACCGTCGTAGTCTT  
 AACCATAAACTATGCCGACTAGAGATAGGAAAATGTCACATTGTTGACTTCTCCTGCACCTTATGAGAAATCAAAGT  
 CTTTGGGTTCTGGGGGGAGTATGGTCGCAAGGCTGAAACTTAAAGGAATTGACGGAAGGGCACCACCAGGCGTGGAG  
 CCTGCGGCTTAATTTGACTCAACACGGGGAACTCACCAGGTCCAGACATGGGAAGGATTGACAGATTGATAGCTCT  
 TTCTTGATTCTATGGGTGGTG

**Figure 8.** Partial sequence of small subunit ribosomal RNA (18S rRNA) gene of thin cyst isolated from goats

highest homology for the *Sarcocystis moulei* (relativity~98%) species. Whether there is considerable confusion concerning the structure of macroscopic sarcocysts in goat, but these results suggest that fat and thin cysts more probably are the same and identical species. The morphological differences between them may be due to the other factors like age of cyst. In fact, the effects of aging on the cyst structure have not been properly described. So, it could be a good topic to investigate in the future.

### Acknowledgments

This research has been supported financially by Razi Vaccine and Serum Institute and Tarbiat Modares University. The authors would like to thank staff of Parasitology, Biotechnology, and Electron Microscopy Departments of Razi Institute for kind cooperation.

### References

Barham, M., Stutzer, H., Karanis, P., Latif, B.M. and Neiss, W.F. (2005). Seasonal variation in *Sarcocystis* species infections in goats in northern Iraq.

- Parasitology* 130(2):151-156.
- Costa da Silva, R., Chunlei, Su., Langoni, H. (2009). First identification of *Sarcocystis tenella* (Railliet, 1886), Moule 1886 (Protozoa: Apicomplexa) by PCR in naturally infected sheep from Brasil. *Veterinary Parasitology* 165:332-336.
- Dalimi, A., Payekari, H., Valizadeh, M., Karimi, Gh., Motamedi, Gh., Abdi Ghodarzi, M., Esmaeilzad, M., Meshkat, M., Najari, A. (2008). Detection of *Sarcocystis* spp. of slaughtered sheep in Gazvin Ziaran slaughterhouse by molecular assay. *Modares Journal of Medical Science* 13(1 & 2): 65-72. (In Persian)
- Dubey, J.P., Speer, C.A., Fayer, R. (1989). *Sarcocystosis of Animals and Man*. CRC Press, Boca Raton, Florida, USA, Pp 121-125.
- El Rafaii, A.H., Abdel-Baki, G., Selim, M.K. (1980). Sarcosporidia in goats of Egypt. *Journal of the Egyptian Society of Parasitology* 10: 471-472.
- Fayer, R. (2004). *Sarcocystis* spp in human infection. *Clinical Microbiology* 17(4): 894-902.
- Fischer, S., Odening, K. (1998). Characterization of bovine *Sarcocystis* species by analysis of their 18S ribosomal DNA sequences. *Journal of Parasitology* 84(1):50-54.
- Ghaffar FA, Hydron AO, Mehlhorn H (1989 ). The fine structure of cysts of *Sarcocystis moulei* from goats. *Parasitology Research* 75: 416-418.
- Li, Q.Q., Yang, Z.Q., Zuo, Y.X., Attwood, S.W., Chen,

- X.W., Zhang, Y.P. (2002). A PCR- based RFLP analysis of *Sarcocystis cruzi* (protozoa: sarcocystidae) in Yunnan. Province, PR China, reveals the water buffalo (*Bubalus bubalis*) as a natural intermediate host. *Journal of Parasitology* 88(6):1259-1261.
- Moule, L. (1888). Des Sarcosporidies et leurs frequence, principalement chez les animaux de boucherie. *Societedes Sciences et Arts de Vitry-le-Francois* 14, 3-41.
- Niedeausem, D. V. (1873). Psorospermien bei der Ziege. *Zeitschrift fur praktische Veterinar-Wissenschaften* 1, 79-86.
- Odening, K., Stolte, M., Bockhardt, I. (1996). On the diagnostics of *Sarcocystis* in cattle: sarcocysts of a species unusual for *Bos Taurus* in a dwarf zebu. *Veterinary Parasitology* 66:19-24.
- Tenter, A.M. (1995). Current research on *Sarcocystis* species of domestic animals. *International Journal for Parasitology* 25, 1311-1330.
- Yang, Z.Q., Li, Q.Q., Zuo, Y.X., Chen, X.W., Chen, Y.J., Nie, L., Wei, C.G., Zen, J.S., Attwood, S.W., Zhang, X.Z., Zhang, Y.P. (2002). Characterization of *Sarcocystis* species in domestic animal using a PCR-RFLP analysis of variation in the 18S rRNA gene: a cost effective and simple technique for routine species identification. *Experimental Parasitology* 102: 212-217.