



**Brief Communication**

**An Unusual Occurrence of Actinobacillosis in Heifers and Cows in A Dairy Herd in Tehran suburb-Iran**

**Taghipour Bazargani<sup>\*1</sup>, T., Khodakaram Tafti<sup>2</sup>, A., Atyabi<sup>1</sup>, N., Faghanizadeh<sup>3</sup>, Gh.**

1. Department of clinical sciences, Faculty of Veterinary Medicine, University of Tehran, Tehran, Iran

2. Department of Pathology, Faculty of Veterinary Medicine, Shiraz University, Shiraz, Iran

3. Private Veterinarian, Tehran, Iran

Received 01 Jun 2010; accepted 15 Aug 2010

---

**ABSTRACT**

An unusual occurrence of actinobacillosis was diagnosed in 4 heifers aged 8-15 months and 2 cattle in a dairy herd with 190 Iranian Holstein breed. Anorexia, dysphagia, drooling of normal or foodtinged saliva and presence of warts-like lesions on the dorsal surface of tongue shaft were observed in a 15-month-old heifer without showing protrusion of tongue or presenting woody tongue and no involvement of either sulcus lingualis or tongue base. In addition to tongue, soft tissues of oral cavity and pharyngeal region including lymph nodes, salivary glands and tonsils were contained multiple whitish nodules. Histopathologically, typical pyogranulomas of actinobacillosis contained radiating eosinophilic clubs surrounded by many neutrophils were diagnosed. *Actinobacillus lignieresii* was isolated from the lesions in pure culture. Clinical examination of other animals revealed the presence of different degrees of granulomatous abscesses in soft tissues including skin around mandibles in at least 3 heifers aged 8-11 months and 2 cattle. Due to 4 recent droughty years feeding the heifers, dry cows and low milk producing cattle by cheap oat and wheat straw mixed with plant awns could be the cause of this event.

**Keywords:** Actinobacillosis, Pyogranulomatous lesions, *Actinobacillus lignieresii*, unusual occurrence, Cattle

---

**INTRODUCTION**

Actinobacillosis due to *Actinobacillus lignieresii* has been reported in domestic animals including cattle, sheep, goats, buffalo, horse and dog (Carmalt *et al* 1999, Kennerman *et al* 2006, Muhammad *et al* 2006, Brown *et al* 2007). The causative agent is a gram negative bacillus that is a normal inhabitant of oral cavity and rumen (Radostits *et al* 2007, Smith

2009). In cattle, actinobacillosis as sporadic, insidiously-developing granulomatous infection typically involves soft tissues of oral cavity especially tongue. The involvement of other organs is considered to be atypical (Aslani *et al* 1995, Holzhauser & Roumen 2002). Actinobacillosis outbreaks have been reported as well (Campbell *et al* 1975, Nakazawa & Azuma 1977). The present study describes the clinical manifestations, bacteriologic, gross and histopathologic

---

\*Author for correspondence. E-mail: natyabi@tu.ac.ir

characteristics of an unusual occurrence of actinobacillosis in a dairy herd.

## MATERIAL AND METHODS

From a dairy herd (located around Tehran, Iran) with 190 Iranian Holstein breed, an unusual illness was observed in at least 4 heifers aged 8-15 months and 2 cattle. The first case was a 15-month-old heifer with a history of anorexia, dysphagia, odynophagia, drooling of saliva and progressive emaciation in a period of about 3 weeks. After clinical examination, because of poor prognosis due to advanced lesions, the animal was referred to slaughterhouse. Inspection of the carcass revealed that no other organs except the head were involved. Therefore, the head tissues were examined carefully. In first step, Impression smears were prepared from pus and necrotic materials of the lesions and small granules and studied after Giemsa and Gram staining methods. For bacteriological examination, early, nondischarging lesions of tongue and regional lymph nodes were sampled and cultured on Blood agar, MacConkey and Serum agar under aerobic and anaerobic conditions. Biochemical tests were carried out on isolated bacteria as described by Carter and Wise 2004. For histopathological examination, appropriate specimens from tongue, tonsils, pharyngeal lymph nodes and other soft tissues of oral cavity were fixed in 10% buffered formalin, embedded in paraffin, sectioned at 5  $\mu$ m, stained with hematoxylin and eosin (H&E), Brown-Brenn gram stain and examined by light microscope. Culture of submitted lesion from tissue was performed as recommended by Carter and Wise 2004, using 5% sheep Blood Agar and Mac Conkey Agar medium for 24-48 hours at 37 °C. Small, smooth and translucent colonies were appeared on Blood Agar medium after 24h, without hemolysis. Gram stain revealed gram negative rods and polymorph coccobacilli. Colonies were catalase and oxidase positive with

rapid tests of hydroxyl-peroxide and tetramethyl-paraphenyl-diamine-dihydrochloride reagent, respectively. Growth of bacteria was positive on MacConkey Agar. Other biochemical reactions were as follow: hydrolysis of aesculin was negative, urease was positive, acid from glucose, lactose, mannitol, sucrose and maltose were positive and arabinose & trehalose were negative.

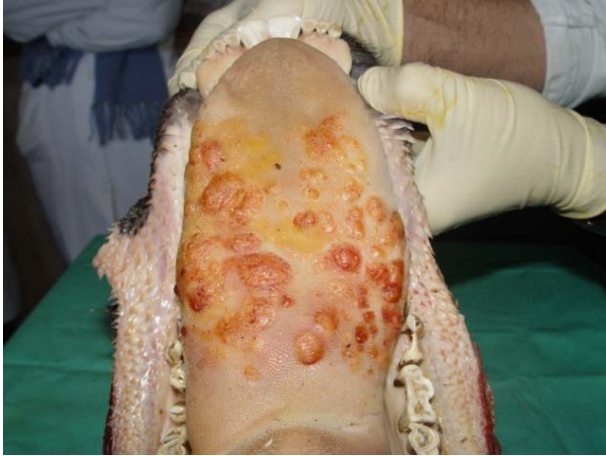Characteristics of Isolated bacteria (*Actinobacillus ligniersii*), Carter, GR. and Wise, DJ (2004)

Hemolysis on 5% sheep Blood Agar	-
Growth on MacConkey Agar	+
Catalase	+
Oxidase	+
Aesculin hydrolysis	-
Urease	+
Glucose	+
Lactose	+
Sucrose	+
Mannitol	+
Maltose	+
Arabinose	-
Trehalose	-

## RESULTS AND DISCUSSION

**Clinical findings.** In physical examination of a 15-month affected heifer cud dropping or bringing back prehended food, normal or foodtinged saliva drooling, low quality and quantity of rumen contraction, poor body condition, swelling of submaxillary, parotid and pharyngolaryngeal lymph nodes, presence of warts-like lesions on the dorsal surface of tongue shaft without remarkable enlargement or hardness were noticed. Close and careful observation made clear that the warts-like lesions were raised spherical button sized nodules. They were firm and non painful on palpation (Figure 1). In the same time, presence of different degrees of granulomatous abscesses in soft tissues including skin around mandibles in at least 3 heifers aged 8-11 months and 2 cattle were noticed. The

disease was clinically diagnosed to be actinobacillosis and treatment with streptomycin (10mg/kg BW, IM, twice daily with the interval of 12 hrs) and potassium iodide (6-10 g., PO daily according the animal BW) was applied for one week.

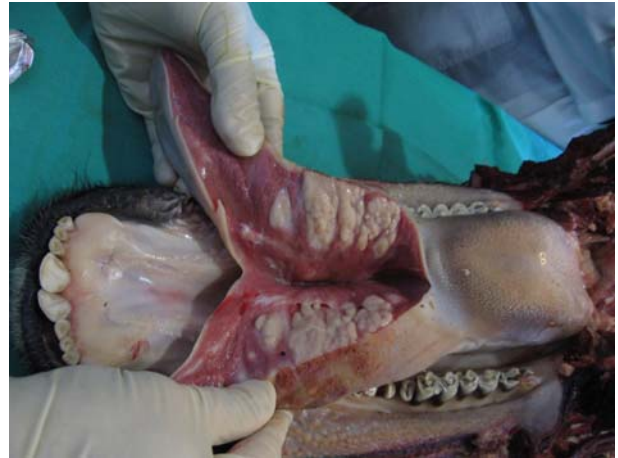

**Figure 1.** Actinobacillosis Variable sized, raised firm nodules and plaques on mid dorsal surface of the tongue.

All the affected animals were recovered except the 15-month heifer with affected tongue that was slaughtered.

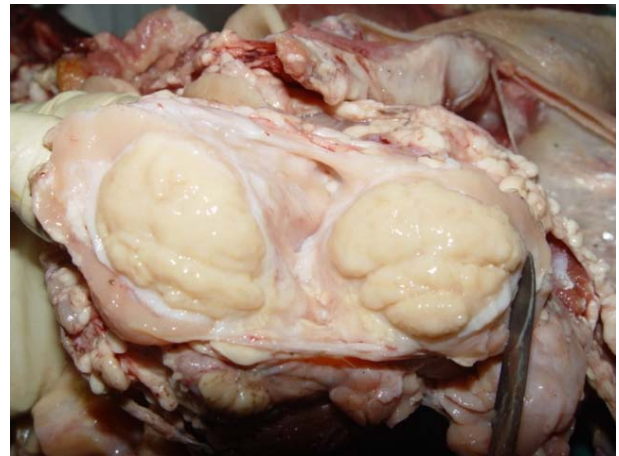
**Bacteriological findings.** Giemsa stained smears of lingual lesions showed a lot of karyorrhectic, degenerated and normal neutrophils, a number of coccobacilli bacteria and also a few reactive macrophages contained hemosiderin pigment and cocci shaped bacteria. Gram stained smears revealed the presence of small gram negative coccobacilli. Bacteriologically, the growth was obtained after incubation under both aerobic and anaerobic conditions and the isolates were based on biochemical reactions identified as *Actinobacillus lignieresii*.

**Pathological findings.** Grossly, on the dorsal surface of tongue shaft, variable sized, between 0.5 to 2 cm in diameter, raised firm nodules and plaques were observed. When incised the affected tongue, iceberg effect as multiple large round whitish nodules about 1- 3 cm in diameter were observed



**Figure 2.** Incised affected tongue. Multiple large whitish nodules are seen within the tissue.

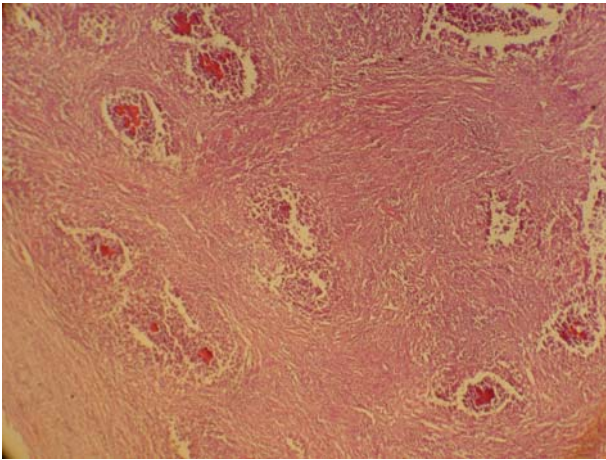
within tongue tissue (Figure 2). Soft tissues of mandible especially pharyngo-laryngeal lymph nodes, salivary glands and tonsils were swelled and contained whitish nodules when incised (Figure 3).



**Figure 3.** Involvement of salivary gland. A large granulomatous whitish nodule is seen in cross section.

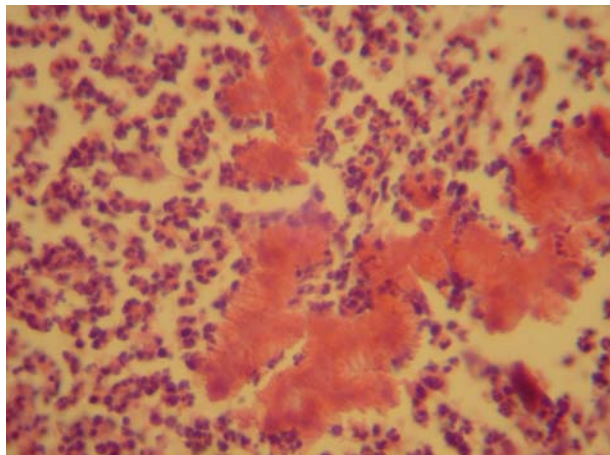
and microabscess formation were diagnosed in all of affected tissues. In the tongue, ulcerative glossitis associated with pyogranulomatous reactions were seen as round masses in both superficial areas beneath the mucosa and deeper parts between striated muscles, adipose tissues and salivary gland acini. These masses were contained a lot of tiny microgranulomas surrounded by a dense fibrous connective tissue layers (Figure 4).





**Figure 4.** Multiple micropyogranulomas including club colonies are surrounded by neutrophils, mononuclear inflammatory cells and dense fibrous tissue. H &E, X 100.

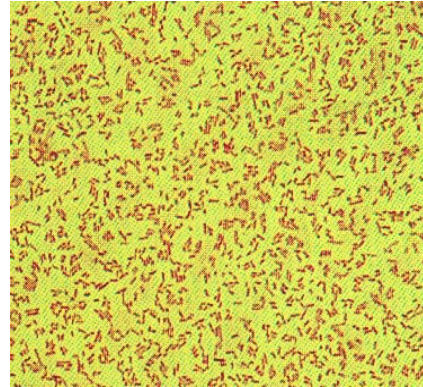
Between these granulomas, chronic active inflammatory lesions containing mixed populations of lymphocytes, plasma cells, macrophages, a few neutrophils in collagenous connective tissue were observed. The granulomas contained centrally located actinobacilli rimmed by radiating eosinophilic club like shapes or splendore-hoepli reaction (Figure 5).



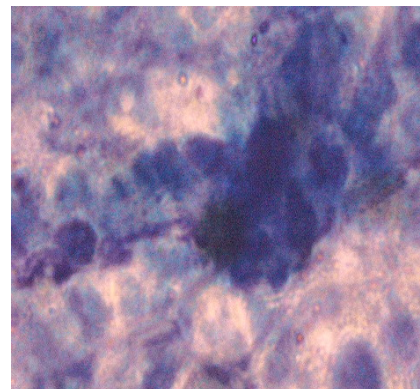
**Figure 5.** Center of a typical pyogranuloma contained radiating eosinophilic clubs surrounded by many neutrophils is observed. H&E, X 720.

These typical club colonies were surrounded by many neutrophils, mixed mononuclear inflammatory cells and dense fibrous tissue. Microscopic examination of affected local lymph nodes, tonsils and salivary glands revealed suppurative inflammation and microabscess

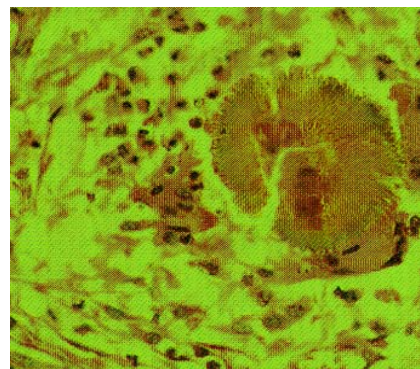
formation associated with characteristic club colonies of actinobacillosis within granulomas. Brown-Brenn gram stain of affected tissues showed gram negative bacilli in the center of granulomas. Gram Stain smear of medium size and gram negative isolated bacteria (*Actinobacillus ligniersii*)



Direct smear from submitted tissue showed the club colonies of isolated bacteria (*Actinobacillus ligniersii*) by Gimsa stain.



Direct smear from submitted tissue showed the club colonies of Isolated bacteria (*Actinobacillus ligniersii*) by Gimsa stain



Actinobacillus species are responsible for several quite distinct disease conditions in animals (Rycroft & Garside 2000). Among those, *Actinobacillus lignieresii* is well recognized as the cause of actinobacillosis or wooden tongue in breeds of cow (Radostits *et al* 2007). Bovine actinobacillosis has usually been identified as a sporadic, insidiously-developing granulomatous condition (Smith 2009). In the farm of this report, actinobacillosis granulomas occurred unusually in tongue shaft of a heifer and soft tissues of oral cavity as well as skin of lower jaw of 3 heifers and 2 cattle in a short period of time. The organism gain entry to deep tissues via traumatic erosions, ulcers and penetrating lesion induced by hard fibrous hays, straw and plant awns (Radostits *et al* 2007, Brown *et al* 2007, Smith 2009). In the dairy of this study, there was a history of feeding heifers, dry cows and cattle with low milk yield mainly by oat and wheat straw having plant awns as well. This low plain nutrition was due to recent 4 droughty years in several provinces of Iran and the resulted expensiveness of good quality hays and grains. Campell *et al.* (1975) reported an unusual outbreak of actinobacillosis in heifers fed on very dry, stemmy and tough haylage. Three collective outbreaks of bovine actinobacillosis during ten years were reported from Japan by Nakazawa and Azuma (1977). *A. lignieresii* is susceptible to ordinary environment influences and it does not survive for more than 5 days (Radostits *et al* 2007). In the farm of this report, crowding facilitated the spread of the infection by way of infected saliva of the first heifer either by contamination of water, food and specially farm building itself. Others indicated that transmission of bovine actinobacillosis may be enhanced by infected discharges contaminating feeds (Radostits *et al* 2007). In addition, it is mentioned that in crowded conditions, infected saliva spread the *A. lignieresii* to other animals, rapidly (Smith 2009). *A. lignieresii* has been reported in infected wounds of human cases who were bitten by horse and sheep

(Dibb *et al* 1981, Peel *et al* 1991). Atypical bovine actinobacillosis including granulomas or abscesses formation in the skin and its associated soft tissues and lymph nodes especially in submaxillary region are reported in cattle (Rebhun *et al* 1988, Anderson *et al* 1990, De Kruif *et al* 1992, Aslani *et al* 1995, Holzhauser & Roumen 2002, Radostits *et al* 2007, Smith 2009). On this basis, six cases of the present report were atypical bovine actinobacillosis. To the authors of this article, skin insults due to skin abrasion with *A. lignieresii* contaminated surface were the most common situation for atypical actinobacillosis development in the small dairy. In apparent contrary to the other reports (Radostits *et al* 2007, Smith 2009), in the heifer with affected tongue neither base nor sulcus lingualis (lingual fossa) were involved and there was not any indication of tongue hardness (woody tongue or wooden tongue). So far, as sulcus lingualis ulcer is concerned, the present findings is quite in accordance with that of Taghipour Bazargani *et al.* (2008) indicating that the lingual fossa ulcer in cattle in Iran is contagious but yet idiopathic.

#### Acknowledgments

The authors are grateful to Dr. Baghban, Dr. Bradran and Dr. Nasiri for their scientific and technical assistance. They are also grateful to Mrs Hashemian, Mr. Porbaha and Mr. Shirvani for their technical assistance.

#### References

- Anderson, K.L., Fairley, R.A., Duncan, D. (1990). Suspected actinobacillosis manifested by facial enlargement in a heifer. *Journal of American Veterinary Medical Association* 197: 1359-1360.
- Aslani, M.R., Khodakaram, A., Rezakhani, A. (1995). An atypical case of actinobacillosis in a cow. *Journal of American Veterinary Medical Association* 42:485-488.
- Brown, C.C., Baker, D.C., Barker, I.K. (2007). Alimentary system In: Maxie MG, Jubb, Kennedy and

- Palmers Pathology of domestic animals. Volume 2, 5th edn, Elsevier Saunders, Pp.20-22.
- Campbell, S.G., Whitlock, T.R.H., Timoney, J.F., Underwood AM (1975). An unusual epizootic of actinobacillosis in dairy heifers. *Journal of American Veterinary Medical Association* 166:604-606.
- Carmalt, J.L., Baptiste, K.E., Chirino-Trejo, J.M. (1999). *Actinobacillus lignieresii* infection in two horses. *Journal of American Veterinary Medical Association* 215:826-828.
- Carter, G.R. and Wise, D.J. (2004). Essentials of veterinary bacteriology and mycology. 6th edn, Iowa State Press, Blackwell Publishing, Pp.143-148.
- De Kruif, A., Mijten, P., Haesebrouck, F., Hoorens, J., Devriese, L. (1992) Actinobacillosis in bovine caesarean section. *Veterinary Record* 131:414-415.
- Dibb, W.L., Digranes, A., Tonjum, S. (1981) *Actinobacillus lignieresii* infection after a horse bite. *British Medical Journal* 283:583-584.
- Holzhauer, M., Roumen, T.P. (2002). Atypical actinobacillosis in a dairy replacement herd. *Veterinary Record* 151:276.
- Kennerman, E., Salci, H., Sevimli, A. (2006). Case of systemic actinobacillosis in a dog-A case report. *Bulletin of the Veterinary Institute in Pulawy* 50:613-617.
- Muhammad, G., Saqib, M., Athar, M. (2006). Fatal actinobacillosis in a dairy Buffalo. *Acta veterinaria BRNO* 75:247-250.
- Nakazawa, M., Azuma, R. (1977). Collective outbreaks of bovine actinobacillosis. *Japanese Journal of Eterinary Science* 39:549-557.
- Peel, M.M., Hornidge, K.A., Luppino, M., Stacpoole, A.M., Weaver, R.E. (1991). *Actinobacillus* spp. And related bacteria in infected wounds of human bitten by horses and sheep. *Journal of Clinical Microbiology* 29:2535-2538.
- Radostits, R.M., Gay, C.C., Hinchcliff, K.W., Constable, P.D. (2007). *Veterinary Medicine*. 10th edn, Pp. 1046-1048.
- Rebhun, W.C., King, J.M., Hillman, R.B. (1988). Atypical actinobacillosis granulomas in cattle. *Cornell Veterinarian* 78:125-130.
- Rycroft, A.N., Garside, L.H. (2000). Actinobacillus species and their role in animal disease. *The Veterinary Journal* 159:18-36.
- Smith, B.P. (2009). *Large Animal Internal Medicine*. 4<sup>th</sup> edn, C.V. Mosby, Philadelphia, Pp. 782-784.
- Taghipour Bazargani, T., Movassaghi, A.R., Bakhtiari, J. (2008) Idiopathic lingual fossa ulcer in cattle in Iran. *Iranian Journal of Veterinary Research* 9: 168-170.