

Short Communication

Vasectomy in Mouse Model Using Electrosurgery Machine

Dadashpour Davachi, N.

Department of Research, Breeding and Production of Laboratory Animals, Razi Vaccine and Serum Research Institute, Agricultural Research, Education and Extension Organization (AREEO), Karaj, Iran

Received 27 March 2019; Accepted 01 June 2019
Corresponding Author: navid.d.davachi@gmail.com

ABSTRACT

Vasectomy in laboratory animals is a crucial step in the production of surrogate female mice. The surrogate mothers play a key role in successful embryo transfer, most important steps for the production of transgenic animal models, investigation of the preimplantation embryo development, and revitalization of cryopreserved strains. Abdominal and scrotal surgeries are common surgical procedures used in routine veterinary practice to produce vasectomized males. Two different surgical practice, namely electrosurgery and cold surgical practice, have been used as common techniques in operating rooms. Based on current knowledge, there is no published “technical note” as a detailed and step by step guideline to describe vasectomy using an electrosurgery machine (i.e., Bovie machine) in laboratory animal research and breeding facilities. The common problem during the laboratory animal surgery would be animal mortalities as a consequence of profound bleeding. The use of Bovie machine leads to the prevention of profound bleeding during the surgical practice.

Keywords: Electrosurgery, Bovie Machine, Vasectomy, Embryo transfer

Vasectomie d'un Modèle de Souris Utilisant un Appareil d'Électrochirurgie

Résumé: La vasectomie chez les animaux de laboratoire est une étape cruciale dans la production de souris femelles de substitution. Les mères porteuses jouent un rôle clé dans la réussite du transfert d'embryons, l'étape la plus importante dans la production de modèles animaux transgéniques, l'étude du développement de l'embryon préimplantatoire et la revitalisation des souches cryoconservées. Les chirurgies abdominales et scrotales sont des procédures chirurgicales courantes utilisées dans la pratique vétérinaire de routine pour produire des males vasectomisés. Deux pratiques chirurgicales différentes, à savoir l'électrochirurgie et la chirurgie à froid représentent les techniques couramment utilisées dans les salles opératoires. Sur la base des connaissances actuelles, il n'existe aucune "note technique" publiée ne constituant une ligne directrice détaillée décrivant pas à pas la vasectomie utilisant un appareil d'électrochirurgie (appareil Bovie) dans des installations de recherche sur les animaux de laboratoire et de reproduction. Le problème le plus courant lors de la chirurgie des animaux de laboratoire serait la mortalité des animaux à la suite de saignements abondants. L'utilisation de l'appareil d'électrochirurgie Bovie permet de limiter les saignements au cours de la pratique chirurgicale.

Mots-clés: Électrochirurgie, Appareil bovie, Vasectomie, Transfert d'embryon

INTRODUCTION

Embryo transfer is the most frequent surgical practice performed in the mouse model. The second place in the field of laboratory animal surgery belongs to vasectomy. According to the literature, vasectomy plays a key role in the production of fostered mothers that serves as a prerequisite to perform embryo transfer (Cheng et al., 2004; Bermejo-Alvarez et al., 2014). The surrogate females, pseudopregnant females, are considered as embryo recipients. These females are mated with vasectomized males a day before natural mating. The seminal secretions produced by a sterile male are required for the uterus to become receptive to the transferred embryos (Bermejo-Alvarez et al., 2014). Therefore, development in vasectomy could be pivotal to reduce animal mortality due to profound bleeding as a consequence of using cold surgical instruments. The use of cold surgical instruments is the most frequent surgical approach for conducting different surgical procedures (**supplementary video 1**) on laboratory animals (Charoenkwan et al., 2017). The application of the cold surgical technique to conduct vasectomy in mice is a routine surgical strategy since there is no need for expensive instruments or electrosurgery machine (i.e., Bovie machine). Moreover, in an equipped laboratory, Bovie machine is one of the customary instruments, which may be used in routine practices. The cold surgical strategy has some complications in laboratory animals, especially for beginners. The use of cold surgical technique may lead to hemorrhage that impairs animal survival following the surgical practice (Kolbe et al., 2012; Scott et al., 2017; Baigrie and Badri, 2019). One of the limitations related to performing surgical practice on laboratory animals would be the failure in blood transfusion. Therefore, profound hemorrhage resulting from the use of cold surgical instruments may lead to animal mortality (Peneva et al., 2018). Applying the electrical flow with the frequencies above 10 kHz leads to heat generation in biological tissues; therefore, this electrical current does not stimulate the neuromuscular system (Aminimoghaddam et al., 2018; Baigrie and Badri,

2019). On the other hand, the skin has poor conductive properties for the electrical flow of energy. Thanks to this exclusive feature of the skin and the benefit of electronic and medical engineering knowledge in the 1920s, a device was designed by the Harvard physicist William Bovie. The above-mentioned device is used to adapt the electrical current above 10 kHz to improve delicate surgery procedures and reduce the post-surgical complications. Superficial or deep coagulation or cutting the skin is the most prominent feature of electrosurgery (Aminimoghaddam et al., 2018; Baigrie and Badri, 2019). The present technical note for the first time described how a researcher can use a Bovie machine in vasectomies in laboratory animals.

MATERIAL AND METHODS

Animal Ethics. The present study was approved by the Institutional Ethics Committee of the Razi Vaccine and Serum Research Institute, Karaj, Iran (license no: 2-18-18-038-960595).

Animal Housing. All the animals (NMRI mice) in this study were bred in the Department of Research, Breeding, and Production of Laboratory Animal in the Razi Vaccine and Serum Research Institute, Karaj, Iran, according to a Robertson system. All the animals were housed under standard laboratory conditions (room temperature: 21 ± 2 °C; relative humidity: 40%-55%; photoperiod of 12L:12D) in Makrolon cages. All the animals were fed with standard breeding diet and tap water ad libitum. Female NMRI mice were also used as embryo donors.

Anesthesia. To induce anesthesia the following doses were used: load 0.2 IU ketamine (0.1 mg/g: 0.01 ml/g of a 10 mg/ml solution), 0.1 IU xylazine (0.01 mg/g: 0.005 ml/g of a 2 mg/ml solution), and 0.7 IU physiological saline solution in 1 ml syringe with 27-gauge needles. The mice were immobilized as described by Bermejo-Alvarez et al., 2014) and then injected with 1.5 IU ketamine-xylazine mixture intraperitoneally. The mouse was left individually in the cage on a warm stage. Once unconscious, they were checked for the absence of rear foot reflex (checked by

toe pinch for more information check the **video file 2**). Eye ointment was applied to avoid eye dryness and check for the absence of palpebral reflex (Bermejo-Alvarez et al., 2014).

Electrosurgery Unit and Animal Preparation. The electrosurgery unit (Bovie machine; Figure 1) used in this study was KLS Martin ME 80 (KLS Martin Group, Germany). This unit has three main parts, including 1) monopolar electrodes (Surgi-pen; Figure 2) attached to a needle electrode with 0.4 mm outer diameter to make an incision in the skin, 2) rubber neutral electrode for children (8×16 cm; Figure 3) with a single contact surface of 120 cm², and 3) monopolar double-pedal footswitch (Figure 4). Several serious precautions should be followed while performing electrosurgery as a preferred surgical method. To avoid animal burning it is necessary to ensure that the animal back skin is fully connected to the rubber neutral electrode; therefore, before putting the mouse on the rubber neutral electrode, it is required to cover the back skin with a water-based lubricant.



Figure 1. Electrosurgery unit (Bovie machine)



Figure 2. Monopolar electrodes (surgi-pen) equipped with cut and coagulation switch




Figure 3. Rubber neutral electrode mounted on warm glass plate




Figure 4. Monopolar double-pedal footswitch; yellow pedal (cut); blue pedal (coagulation)

Vasectomy

Critical Steps. The anesthetized male was placed in the supine position with its tail towards the surgeon on the black rubber neutral electrode to expose the abdomen when deeply narcotized. It is strongly suggested to apply some water-based lubricant on the male back (spin position) before putting the animal on the black rubber neutral electrode (shown in a supplementary **video 2**). The application of the lubricant on the back of the mouse is necessary to prevent severe burning due to disruption in electricity energy flow from the tip of the surgi-pen throughout the animal body to Bovie machine. If this step is skipped the animal suffers from severe and painful burning. Following the proper anesthesia, while keeping the mouse on a warm stage on its back on the rubber electrode, 1 cm above the pines on the abdomen was shaved and the skin was sanitized by sequential wiping using povidone-iodine (shown in a supplementary **video 2**). A critical note during the electrosurgery would be the

limitation of using "70% Ethanol". During the whole electrosurgery, it is prohibited to use this solution because using the 70% ethanol would lead to inflammation.

Electrosurgery. The surgi-pen was plugged into the Bovie machine. Before setting up the electrical flow rate and frequency, the needle electrode was connected to the surgi-pen. Then the device was turned on, and the yellow pedal was pushed on the footswitch. In this step, a close contact is made between the needle electrode and shaved skin in the medial line of the abdomen (for detailed procedure see the supplementary **video 2**). A 10 mm longitudinal skin incision was performed about 1 cm above the penis. After making 1 cm incision in the abdomen skin and body wall, the testicular adipose pad of one side was grabbed with micro-dissecting serrated forceps and pulled to expose testis, then the vas deferens was cut (Figure 5).

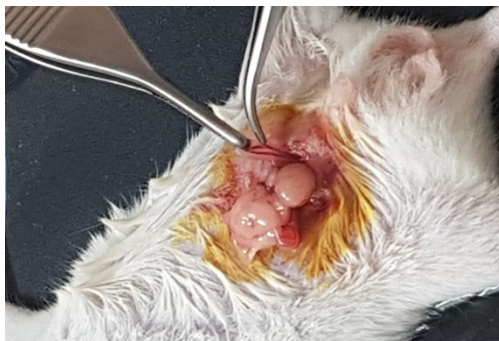

Figure 5. Vas deferens

The vas deferens is located medially toward the testis, and it is a clearly distinguishable free tube with a blood vessel running along one side (shown in a supplementary **video 2**). After cutting vas deferens in both testicles, the testicles were put back to the body cavity and the body wall was sutured then the skin (muscle) with one or two horizontal mattress stitches made with 5/0 absorbable suture (shown in a supplementary **video 2**). Then the animal should be put in an individual cage equipped with a warm plate. For the animal welfare, 4-5 plates should be put in a Petri dish for easy access to the food during the first 24 h after the surgery. Vasectomy should be performed at least 10–14 days before the first mating to allow the

recovery of males from the surgical procedure. It is recommended to determine the sterility of vasectomized mice by breeding them with females. If the mating occurred, and the vaginal plug was formed following the mating while the pregnancy did not happen, it can be ensured that vasectomy was successful (Ittner and Gotz, 2007).

RESULTS AND DISCUSSION

Vasectomy in male mouse using Bovie machine reduce profound bleeding, as well as animal mortality, and prevent some of the complications associated with the cold surgical technique. Table 1 tabulates some representative results obtained from performing vasectomy using a Bovie machine. The recorded data revealed that electrosurgery is a reliable technique to perform vasectomy in male mice, compared to the conventional cold surgical technique.

Table 1. Comparison between Bovie machine efficacy and cold surgical technique

Surgical Technique	Practice (n)	Profound bleeding n (%)	Mortality week after surgery n (%)	1 Successful vasectomy n (%)
Electrosurgery	20	0	1 (5)	19 (95)
Cold surgery	20	6 (30)	8 (40)	6 (30)

In this study, a detailed vasectomy procedure using a Bovie machine was described step by step. The obtained results showed that in case of vasectomy this technique has a great advantage in comparison to the cold surgical practice. As a Bovie machine converts the electricity to heat in contact with the skin we would not see uncontrolled bleeding during the whole surgical practice. Even if a practitioner encounters any minor bleeding, it will be stopped immediately by changing the setting of the Bovie machine and pushing the blue pedal on the footswitch. Therefore, in this method, there is usually no failure or animal mortality due to profound bleeding, while in the conventional surgery using cold instruments profound bleeding was observed in 30% of animals. In case of animal mortality 1 week after the surgery, a great increase was recorded in

animals vasectomized with cold surgical instruments. There are several possibilities for this failure; firstly, it can be affirmed that the minor bleeding, which did not lead to animal death, may result in the weakness of the animal, and consequently lead to animal death in the first week after the surgery. Secondly, due to heat generation in the site of incision, the chance of bacterial infections reduced in the Bovie group, compared to that in the cold surgery group. On the whole, in both groups following vasectomy, the survived animals successfully served as sterile males for mating with fostered mothers to induce pseudopregnancy.

Ethics

I hereby declare all ethical standards have been respected in preparation of the submitted article.

Grant Support

This study was supported by the Razi Vaccine and Serum Research Institute under the grant and project number of 2-18-18-038-960595.

Acknowledgment

The author would like to appreciate Mr. Ebrahim Norouzi for the assistance during the surgery and thank the colleagues from the Audio Visual Productions Unit in Public Relations Department who provided facility and expertise to capture the video files.

References

- Aminimoghaddam, S., Pahlevani, R., Kazemi, M., 2018. Electrosurgery and clinical applications of electrosurgical devices in gynecologic procedures. *Med J Islam Repub Iran* 32, 90.
- Baigrie, D., Badri, T., 2019. Electrosurgery. StatPearls, Treasure Island (FL).
- Bermejo-Alvarez, P., Park, K.E., Telugu, B.P., 2014. Uterotubal embryo transfer and vasectomy in the mouse model. *J Vis Exp*, e51214.
- Charoenkwan, K., Ihezor-Ejiofor, Z., Rerkasem, K., Matovinovic, E., 2017. Scalpel versus electrosurgery for major abdominal incisions. *Cochrane Database Syst Rev* 6, CD005987.

- Cheng, T.C., Huang, C.C., Huang, L.S., Chen, C.I., Lee, M.S., Liu, J.Y., 2004. Evaluation of mouse blastocyst implantation rate by morphology grading. *Chin J Physiol* 47, 43-47.
- Ittner, L.M., Gotz, J., 2007. Pronuclear injection for the production of transgenic mice. *Nat Protoc* 2, 1206-1215.
- Kolbe, T., Palme, R., Touma, C., Rulicke, T., 2012. Repeated use of surrogate mothers for embryo transfer in the mouse. *Biol Reprod* 86, 1-6.
- Peneva, M., Gjorgjeska, A., Gjorgova, S.T., Dzonov, B., Noveski, L., Ginoski, V., *et al.*, 2018. Evaluation of Pain Following the Use of Scalpel Versus Electrosurgery for Skin Incisions in the Facial Regions. *Pril (Makedon Akad Nauk Umet Odd Med Nauki)* 39, 107-112.
- Scott, J.E., Swanson, E.A., Cooley, J., Wills, R.W., Pearce, E.C., 2017. Healing of canine skin incisions made with monopolar electrosurgery versus scalpel blade. *Vet Surg* 46, 520-529.