

Original Article

Effect of Oat (*Avena Sativa L.*) Extract on Experimental Sciatic Nerve Injury in Rats

Darzian Rostami, Z. ¹, Asghari, A. ^{1*}, Jahandideh, A. ¹, Mortazavi, P. ², Akbarzadeh, A. ^{3,4}

1. Department of Clinical Sciences, Science and Research Branch, Islamic Azad University, Tehran, Iran
2. Department of Pathobiology, Science and Research Branch, Islamic Azad University, Tehran, Iran
3. Drug Applied Research Center, Tabriz University of Medical Sciences, Tabriz, Iran
4. Universal Scientific Education and Research Network, Tabriz, Iran

Received 06 January 2019; Accepted 11 March 2019
Corresponding Author: dr.ahmad.asghari@gmail.com

ABSTRACT

Peripheral nerve disorders are the most common neurological problems; therefore, it is important to intervene to treat or stop the resulting side effects. This study aimed to investigate the effect of oat extract on experimental sciatic nerve injury in rats. Totally, 50 adult male rats were divided into five groups (n=10). Group 1 was exposed to sham condition, and group 2 was regarded as the control group (nerve injury without treatment). Moreover, groups 3-5 were subjected to sciatic nerve injury, and they received oral gavages of the oat extract (100, 200, and 400 mg/kg), respectively. Subsequently, 2 and 4 weeks later, the rats were euthanized for pathological evaluation of nerve repair. The results showed an increase in the formation of the perineurium and epineurium dose in the oat-treated groups (100, 200, and 400 mg/kg), compared to the control group after 2 weeks (P<0.05). Furthermore, the presence of inflammatory cells in the oat extract-treated groups (100, 200, and 400 mg/kg) decreased, compared to that in the control group after 2 weeks (P<0.05). In addition, the swelling of the axon significantly decreased in the oat extract-treated groups (200 and 400 mg/kg), compared to the control group (P<0.05). However, the axon dose-dependently increased in oat-treated groups (100, 200, and 400 mg/kg), compared to that in the control group after 4 weeks (P<0.05). These results suggest that oat extract has positive effects on sciatic nerve repair in rats.

Keywords: Oat extract, Rat, Sciatic nerve injury

Effet de l'Extrait d'Avoine (*Avena Sativa L.*) sur des Lésions Expérimentales du Nerf Sciatique chez les Rats

Résumé: Les troubles nerveux périphériques sont parmi les problèmes neurologiques les plus courants. Par conséquent, il est important d'intervenir pour traiter ou arrêter les effets secondaires qui en résultent. Cette étude visait à étudier l'effet de l'extrait d'avoine sur les lésions expérimentales du nerf sciatique chez les rats. Au total, 50 rats mâles adultes ont été divisés en cinq groupes (n = 10). Le groupe 1 a été exposé à des conditions fictives (témoin), et le groupe 2 a été considéré comme le groupe de contrôle (lésion nerveuse sans traitement). Les groupes 3 à 5 ont reçu des gavages oraux d'extrait d'avoine (100, 200 et 400 mg/kg), respectivement. Par la suite, les rats ont été euthanasiés 2 et 4 semaines plus tard, pour l'évaluation pathologique de la réparation nerveuse. Les résultats ont montré une augmentation de la formation des périnèvre et épινèvre dans les groupes traités à l'avoine (100, 200 et 400 mg/kg), par rapport au groupe de contrôle après 2 semaines (P <0,05). En outre, la présence de cellules inflammatoires dans les groupes traités à l'extrait d'avoine (100, 200 et 400 mg / kg) a diminué par rapport à celle du contrôle après 2 semaines (P <0,05). De plus, le gonflement de l'axone a considérablement diminué dans les groupes traités à l'extrait d'avoine (200 et 400 mg / kg), par rapport au groupe de contrôle (P <0,05). Cependant, l'axone a augmenté en fonction de la dose dans les groupes traités par

l'avoine (100, 200 et 400 mg / kg), par rapport à celui du groupe de contrôle après 4 semaines ($P < 0,05$). Ces résultats suggèrent que l'extrait d'avoine a des effets positifs sur la réparation du nerf sciatique chez les rats.

Mots-clés: Extrait d'avoine, Rat, Lésion du nerf sciatique

INTRODUCTION

Peripheral nerve disorders are the most common neurological problems which need immediate treatments (Allan et al., 2000). Despite advances in medical instruments for the repair of nerves, the therapeutic strategy is still a preferred method for peripheral nerves. Treatment and prognosis of the peripheral nerve depends on the nature of neurological damage. The medical treatment is the most common strategy for rehabilitation and surgery of the peripheral nerves (Senger et al., 2018). Nowadays, worldwide interest has increased in folk medicine. Plants are rich sources of a wide variety of secondary metabolites with high antioxidant properties. Medicinal plant-derived pharmaceutical products are being used in medicine because of their beneficial properties and lower complications of surgery and chemical drugs (Güven et al., 2016; Sriraksa et al., 2019). Oat (*Avena sativa L.*) belongs to the grass family (Gramineae) and has a wide range of chemical compounds including carbohydrates, sterols, lipids, proteins, alkaloids, saponins, and flavonoids. Moreover, it has high antioxidant properties due to phenolic compounds and contains β -glucan, starch, and amylase (Aktas-Akyildiz et al., 2018), as well as vitamins, and minerals (He et al., 2018). In addition, its seeds are used in health products. Oat contains (Grunden et al., 2018) esters, phospholipids, triglycerides, and fatty acids (Liu et al., 2018). Due to its medical properties, it is considered a herbal remedy in the treatment and prevention of diseases (Ben Halima et al., 2015). This plant contains selenium, vitamin E, glyceryl esters, and ferulic acids which play

the role of antioxidant activity. Avenanthramide is the main metabolite of the oat which has antioxidant properties. Despite this, scarce information exists on the effect of oat extract on cell injury protection or antioxidative enzymes. Recently, Feng et al. (2013) have reported that oat bran extracts play a protective role in hydrogen peroxide-induced dermal fibroblast injury. Since there has been no report in the literature regarding the effect of oat extract on nerve repair, this study aimed to investigate the effect of oat extract on experimental sciatic nerve injury in rats.

MATERIAL AND METHODS

Animals. In total, 50 healthy adult male Wistar rats (weight range: 300-350 g) were purchased from Pasteur Institute. The animals were kept under constant room temperature at $20 \pm 1^\circ\text{C}$ and relative humidity of $42 \pm 1\%$ on a 12-hour light/dark cycle. Subsequently, the rats were randomly divided into five experimental groups ($n=10$). All animals had *ad libitum* access to chow pellets and freshwater. Furthermore, the animals were acclimatized to laboratory conditions for one week before experiments, and each animal was used only once and killed immediately after the experiment. All experimental procedures were carried out under the Guide for the Care and Use of Laboratory Animals to Investigate Experimental Pain in Animals (Zimmermann, 1983). It should be noted that animal handling and experimental procedures were performed according to the Guide for the Care and Use of Laboratory Animals by the US National Institutes of Health (NIH Publication No. 85-23, revised 1996) and the current laws of the Iranian government. The study

protocol for animal experiments was approved by the Ethics Committee of Islamic Azad University, Science and Research Branch, Tehran, Iran (Ethic code:25895).

Extract Preparation. Oat seeds were ground and subjected to extraction using ethanol-water 80% by maceration method. The prepared extract was filtered using a large Whatman paper No.41, and then another filtration was carried out using a Whatman paper No.42 to remove all the particles. The clear extract was poured on a tray and dried under vacuum at 50° C. The dosage of the oat extract was determined based on previous studies (Ma et al., 2016; Kandhare et al., 2017).

Experimental Protocol. Animals were divided into five groups. Group 1 was kept as sham, and group 2 was regarded as the control group (nerve injury without treatment). Groups 3-5 were subjected to sciatic nerve injury, and the animals received the oral gavage of the oat extract (100, 200, and 400mg/kg), respectively (Kandhare et al., 2017). All surgical procedures were performed under anesthesia by intraperitoneal injection of ketamine hydrochloride (60 mg/kg) and xylazine hydrochloride (10 mg/kg) (Koksal et al., 2012). After initial scrap and preparation, an incision was placed in the posterior skin of the left-footed area. The muscles and fascia were slowly put aside and after exposing the sciatic nerve, small hemostats were applied for 60 seconds. To put pressure on the nerve, the tooth lock was kept on top (Feng and Yuan, 2015). After each crushing site was closed to the nearest suturing muscle using absorbable suture (5-0), subcutaneous and skin tissues were sutured using interrupted (vicryl 0-4) and cutaneous (nylon 0-3) sutures.

Histological Evaluation. Experimental groups were treated with oral gavages of the oat extract and a similar amount of the distilled water for 4 weeks (Zhao and Cui, 2016). After 2 and 4 weeks (Jiang et al., 2016), the rats were euthanized by intravenous injection of thiopental sodium for pathological evaluation of the nerve repair. The tissue of the nerve injury, the distal segment of the sciatic nerve, was

removed and fixed in 10% buffer formaldehyde. The fixation process of the sciatic nerve was initially performed with paraffin. A tissue section (5µm) was obtained, deparaffinized, and stained with Trichrome. Trichrome staining was used to examine the production of perineurium and epineurium connective tissues. Afterward, the tissue samples were examined using a light microscope. The correct formation of the perineurium and epineurium was graded according to the 0-4 scoring system including 0 (none), 1 (less than 25%), 2 (25-50%), 3 (50-75%), and 4 (complete) regarding the formation of the perineurium and epineurium. Furthermore, the presence of inflammatory cells was graded using the scores as 0 (high, >75%), 1 (moderate, 75-50%), 2 (mid, 50-25%), 3 (less, <25%), and 4 (absence of inflammatory cells). In the same line, the swelling of the axon was graded as 0 (obvious, >75% of axon diameter), 1 (moderate, 75-50% of axon diameter), 2 (mid, 25-50% of axon diameter), 3 (less, <25% of axon diameter), and 4 (absence of axon swelling). The axon numbers were graded as 0 (<25% normal nerve), 1 (25% normal nerve), 2 (50% normal nerve), 3 (75% normal nerve), and 4 (similar to normal nerve) (Caner et al., 2012).

Statistical Analysis. Statistical evaluation was performed using SPSS software (version 24). The results were expressed as mean±standard error of the mean. Moreover, non-parametric tests were analyzed using the Kruskal-Wallis test. A p-value less than 0.05 was considered statistically significant.

RESULTS

Based on the histological results, the strings of axon and perineurium were naturally observed in the sham group after 2 and 4 weeks (Figure 1, A1-A2). In addition, there was a swelling of the axons and epineurium in the control group after 2 and 4 weeks (Figure 1, B1-B2). There was a mild infiltration of single-nucleotide inflammatory cells in swelling axons and epineurium of the oat extract-treated groups (Figures 2 and 3).

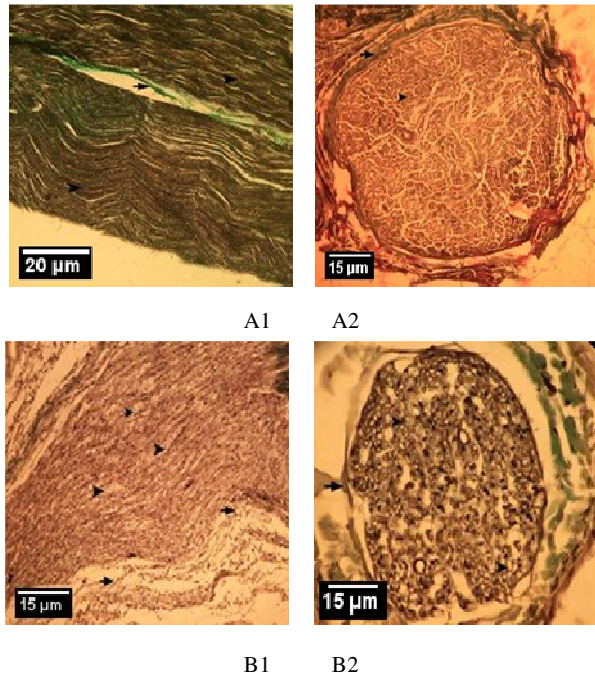


Figure 1. Trichrome staining (Trichromex100) after 2 and 4 weeks. A1-A2: (normal morphology in the sham group) showing the observed natural presence of the axons (the tip of the arrow) and the epineurium. B1-B2: nerve damage without treatment (control group). B1 showing the high swelling of the axons (tip of the arrow) and the infiltration of single nuclei within 2 weeks. B2 showing the swelling of the axons (the tip of the arrow) and the epineurium after 4 weeks.

As can be seen in diagram 1, the formation of the perineurium and epineurium significantly decreased in the control group after 2 weeks ($P < 0.05$). However, the formation of the perineurium and epineurium dose-dependently increased in the oat-treated groups (100, 200, and 400 mg/kg), compared to the control group ($P < 0.05$). Moreover, the presence of inflammatory cells significantly increased in the control group after 2 weeks ($P < 0.05$). Nonetheless, the presence of inflammatory cells in oat extract-treated groups (100, 200, and 400 mg/kg) decreased, compared to the control group ($P < 0.05$). Additionally, the swelling of the exon significantly decreased in the oat extract-treated groups (200 and 400 mg/kg), compared to the control group ($P < 0.05$). The axons dose-dependently increased in oat-treated groups (200 and 400 mg/kg), compared to the control group after 2 weeks ($P < 0.05$) (Diagram 1).

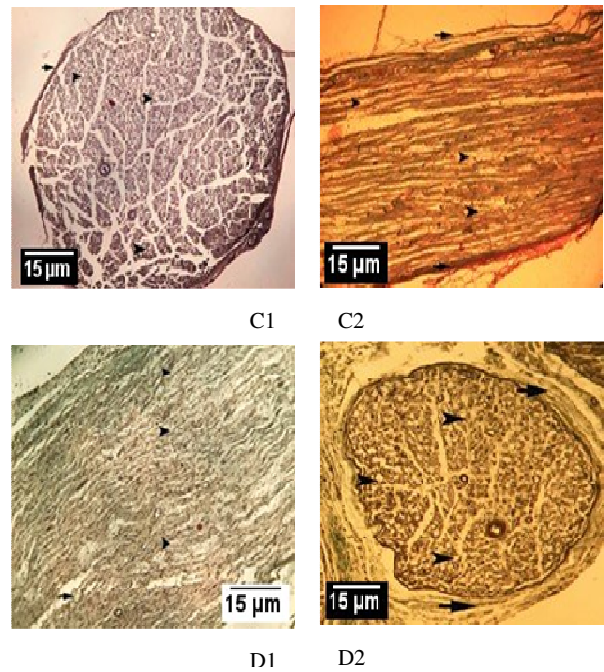


Figure 2. Effect of the oat extract on experimental sciatic nerve injury in rats. Transverse section of the sciatic nerve after 2 weeks and longitudinal section of the sciatic nerve after 4 weeks in oat extract-treated rats (100mg/kg). C1-C2 showing the swelling of the axons (the tip of the arrow) and the epineurium (Trichromex100). D1-D2 showing the longitudinal section of the sciatic nerve after 2 weeks and transverse section sciatic nerve after 4 weeks in oat extract-treated group(200mg/kg) revealed high swelling of the axons (tip of the arrow) and the infiltration of single nuclei (Trichromex100).

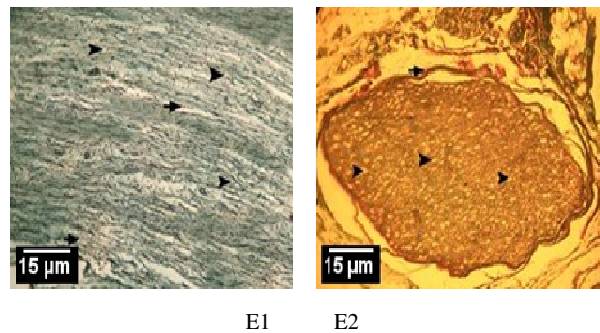


Figure 3. Effect of the oat extract on experimental sciatic nerve injury in rats. Longitudinal section of the sciatic nerve after 2 weeks and Transverse section sciatic nerve after 4 weeks in oat extract-treated rats (400 mg/kg): The swelling of the axons and epineurium was observed as a mild infiltration of single-nucleotide inflammatory cells after 4 weeks (Trichromex100) (E1-E2).

There was no significant difference among the experimental groups in terms of the formation of the

perineurium and epineurium after 4 weeks ($P>0.05$). The presence of inflammatory cells significantly decreased in oat extract-treated groups (100, 200, and 400 mg/kg), compared to the sham group ($P<0.05$). Moreover, the swelling of the exon significantly decreased in oat extract-treated groups (100, 200, and 400 mg/kg), compared to the sham group ($P<0.05$). The axons dose-dependently increased in oat-treated groups (200 and 400 mg/kg), compared to the control group

repair in rats. This study was conducted for the first time to determine the effects of the oat extract on experimental sciatic nerve injury in rats. As observed in the current study, the formation of the perineurium and epineurium significantly increased in the sham group after 2 weeks. Moreover, the formation of the perineurium and epineurium dose-dependently increased in the oat-treated group (100, 200, and 400 mg/kg), compared to the control group. The presence of

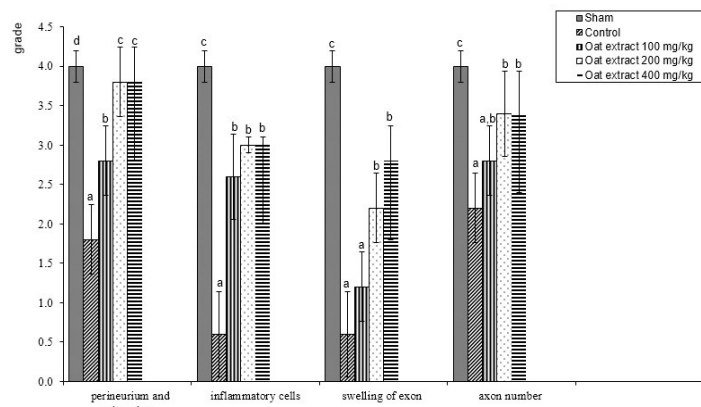


Diagram 1. The effect of the oat extract (100, 200, and 400 mg/kg) on the formation of the perineurium and epineurium, presence of inflammatory cells, swelling of the exon, and axon number on experimental sciatic nerve injury in rats after 2 weeks. Different letters (a-d) indicate significant differences among treatments ($P<0.05$).

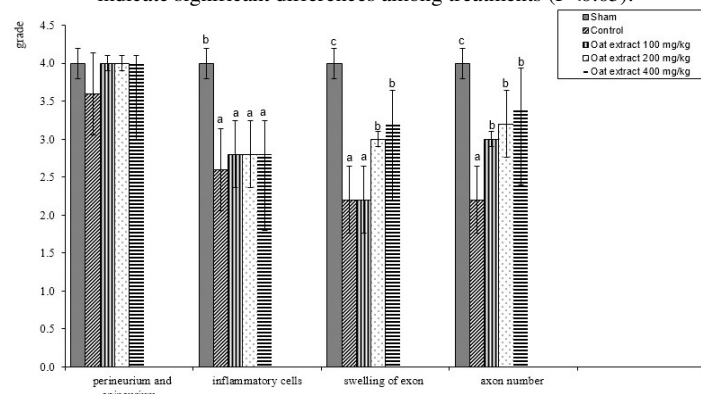


Diagram 2. The effect of the oat extract (100, 200, and 400 mg/kg) on the formation of the perineurium and epineurium, presence of inflammatory cells, swelling of the exon, and axon number on experimental sciatic nerve injury in rats after 4 weeks. Different letters (a-d) indicate significant differences among treatments ($P<0.05$).

after 4 weeks ($P<0.05$) (Diagram 2).

DISCUSSION

To the best of our knowledge, there is no report investigating the effects of oat on experimental nerve

inflammatory cells significantly decreased in oat extract-treated groups (100, 200, and 400 mg/kg). In addition, the swelling of the exon significantly decreased in oat extract-treated groups (100, 200, and 400 mg/kg), and the axon dose-dependently increased

in rats received oat extract (100, 200, and 400 mg/kg) after 4 weeks. Oxidative stress plays an important role in the pathogenesis of peripheral nerve damage. During the nerve damage, oxidation damage affects nerves due to the reactive oxygen species (ROS) production (Asghari et al., 2016). Excessive generation of the ROS interacts with lipids, proteins, and nucleic acids which has adverse effects on cell function and damage (Yulug et al., 2013). The high rate of metabolism in the nerve increases the production of the ROS, thereby decreasing the antioxidant capacity (Tuglu et al., 2015). The stability of the cell is maintained by antioxidant enzymes that remove the ROS (Kulbacka et al., 2009). The application of the oat extract on atopic dry skin of the human for 4 weeks revealed its safety and efficiency in the clinical application (Mizuno, 2005). According to a study, the ethanol extracts of oat have wound healing properties in diabetic rats (Veerasubramanian et al., 2018), and Lanza et al. (2012) showed that antioxidant compounds of flavonoids and glycosides had a positive role in neuromuscular regeneration. Oats contain a variety of phytochemicals possessing a phenolic moiety with free-radical scavenging capability and antioxidant properties (Meydani, 2009). Furthermore, avenanthramides are the main phenolic compounds of oats (Sandhu et al., 2017). The antioxidant activity of avenanthramides is ten times greater than other phenolic antioxidants of the oats (Meydani, 2009). Supplementing the diet of rats with avenanthramide extract of oats (100 mg/kg diet) enhanced superoxide dismutase (SOD) and glutathione peroxidase (GPx) activity in skeletal muscle, liver, kidneys, and heart (Ji et al., 2003). Avenanthramide extract supplementation of oats (100 mg/kg diet) attenuated the exercise-induced ROS production in rats (O'Moore et al., 2005). In a study, the effect of an oat extract was investigated on alcohol-induced acute liver injury in mice, and it was reported effective in preventing acute liver damage (Mir et al., 2018). β -glucan content of the oat has a potent inhibitory effect on microorganisms, such as *Staphylococcus Aureus* and *Eimeria Vermiformis*. Oatmeal has a satisfactory

effect on the treatment of skin lesions (Alexandrescu et al., 2007). Furthermore, Mecocci et al. (2018) revealed that the pretreatment of the human dermal fibroblasts with oat extract 24 h before H₂O₂ injury increased SOD activity in a dose-dependent manner. The SOD serves as a primary gatekeeper in the antioxidant defense system, whereas GPx activates the reaction of lipid hydroperoxides with reduced glutathione to form glutathione disulfide (Feng et al., 2013). It is reported that avenanthramides increase human plasma GPx activity (Chen et al., 2007). Moreover, oat extract can prevent H₂O₂-induced oxidative stress in dermal fibroblasts by improving cellular antioxidant activity (Feng et al., 2013). Regarding the limitation of the current study, there was no possibility to determine MDA, SOD, and GPx levels in oat extract-treated rats following nerve injury. Therefore, further studies are recommended to investigate the effect of antioxidant activity of the oat extract and cellular antioxidant enzyme levels on sciatic nerve repair. Numerous investigations revealed the positive healing effects of ethanol and aqueous extract of the oat which resulted in faster repair and reduction of skin inflammation (Akkol et al., 2011). Regarding the repair of the sciatic nerve, the present study revealed an increase in the formation of perineurium and number of exons, as well as a decrease in the inflammatory cells among the rats treated with oat extract. In this regard, oat extract increases the consciousness, attention, concentration, and ability of the individual (Berry et al., 2011). Moccetti et al. (2006) reported that oat extracts had an inhibitory effect on monoamine oxidase B and phosphodiesterase 4 which improved mental health. In conclusion, these results suggest that oat extract has positive effects on sciatic nerve repair in rats. Since there was no similar study to compare the obtained results on the effect of the oat extract on sciatic nerve repair, further studies are recommended to investigate the direct cellular and molecular effect of oat extract on sciatic nerve repair.

Ethics

We hereby declare all ethical standards have been respected in preparation of the submitted article.

Conflict of Interest

The authors declare that they have no conflict of interest.

Authors' Contribution

Study concept and design: Asghari, A.; Darzian Rostami, Z.

Acquisition of data: Darzian Rostami, Z.

Analysis and interpretation of data: Mortazavi, P.; Jahandideh, A.

Drafting of the manuscript: Asghari, A.; Darzian Rostami, Z.

Critical revision of the manuscript for important intellectual content: Asghari, A.

Statistical analysis: Asghari, A.; Akbarzadeh, A.

Administrative, technical, and material support: Science and Research Branch, Islamic Azad University, Tehran, Iran

References

- Akkol, E.K., Süntar, I., Orhan, I.E., Keles, H., Kan, A., Çoksari, G., 2011. Assessment of dermal wound healing and in vitro antioxidant properties of *Avena sativa* L. *J Cereal Sci* 53, 285-290.
- Aktas-Akyildiz, E., Sibakov, J., Nappa, M., Hytönen, E., Koksels, H., Poutanen, K., 2018. Extraction of soluble β -glucan from oat and barley fractions: Process efficiency and dispersion stability. *J Cereal Sci* 81, 60-68.
- Alexandrescu, D.T., Vaillant, J.G., Dasanu, C.A., 2007. Effect of treatment with a colloidal oatmeal lotion on the acneform eruption induced by epidermal growth factor receptor and multiple tyrosine-kinase inhibitors. *Clin Exp Dermatol* 32, 71-74.
- Allan, G.L., Parkinson, S., Booth, M.A., Stone, D.A., Rowland, S.J., Frances, J., *et al.*, 2000. Replacement of fish meal in diets for Australian silver perch, *Bidyanus bidyanus*: I. Digestibility of alternative ingredients. *Aquaculture* 186, 293-310.
- Asghari, A., Akbari, G., Meghdadi, A., Mortazavi, P., 2016. Protective effect of metformin on testicular ischemia/reperfusion injury in rats. *Acta Cir Bras* 31, 411-416.
- Ben Halima, N., Ben Saad, R., Khemakhem, B., Fendri, I., Abdelkafi, S., 2015. Oat (*Avena sativa* L.): Oil and Nutriment Compounds Valorization for Potential Use in Industrial Applications. *J Oleo Sci* 64, 915-932.
- Berry, N.M., Robinson, M.J., Bryan, J., Buckley, J.D., Murphy, K.J., Howe, P.R., 2011. Acute effects of an *Avena sativa* herb extract on responses to the Stroop Color-Word test. *J Altern Complement Med* 17, 635-637.
- Caner, B., Kafa, M.I., Bekar, A., Kurt, M.A., Karli, N., Cansev, M., *et al.*, 2012. Intraperitoneal administration of CDP-choline or a combination of cytidine plus choline improves nerve regeneration and functional recovery in a rat model of sciatic nerve injury. *Neurol Res* 34, 238-245.
- Chen, C.Y., Milbury, P.E., Collins, F.W., Blumberg, J.B., 2007. Avenanthramides are bioavailable and have antioxidant activity in humans after acute consumption of an enriched mixture from oats. *J Nutr* 137, 1375-1382.
- Feng, B., Ma, L.J., Yao, J.J., Fang, Y., Mei, Y.A., Wei, S.M., 2013. Protective effect of oat bran extracts on human dermal fibroblast injury induced by hydrogen peroxide. *J Zhejiang Univ Sci B* 14, 97-105.
- Feng, X., Yuan, W., 2015. Dexamethasone enhanced functional recovery after sciatic nerve crush injury in rats. *Biomed Res Int* 2015, 627923.
- Grunden, A.M., Sederoff, H., Smith, C.M., Aslett, L.D., 2018. Methods and compositions for enhanced biomass production and increased abiotic stress tolerance, North Carolina State University, North Carolina.
- Güven, M., Golge, U.H., Aslan, E., Sehitoglu, M.H., Aras, A.B., Akman, T., *et al.*, 2016. The effect of aloe vera on ischemia–Reperfusion injury of sciatic nerve in rats. *Biomed Pharmacother* 79, 201-207.
- He, B., Bai, Y., Jiang, L., Wang, W., Li, T., Liu, P., *et al.*, 2018. Effects of Oat Bran on Nutrient Digestibility, Intestinal Microbiota, and Inflammatory Responses in the Hindgut of Growing Pigs. *Int J Mol Sci* 19, 2407.
- Ji, L.L., Lay, D., Chung, E., Fu, Y., Peterson, D.M., 2003. Effects of avenanthramides on oxidant generation and antioxidant enzyme activity in exercised rats. *Nutr Res* 23, 1579-1590.
- Jiang, X., Ma, J., Wei, Q., Feng, X., Qiao, L., Liu, L., *et al.*, 2016. Effect of Frankincense Extract on Nerve Recovery in the Rat Sciatic Nerve Damage Model. *Evid Based Complement Alternat Med* 2016, 3617216.
- Kandhare, A.D., Mukherjee, A.A., Bodhankar, S.L., 2017. Neuroprotective effect of *Azadirachta indica* standardized extract in partial sciatic nerve injury in rats: Evidence from

- anti-inflammatory, antioxidant and anti-apoptotic studies. *Excli J* 16, 546-565.
- Koksal, M., Oguz, E., Baba, F., Eren, M.A., Ciftci, H., Demir, M.E., *et al.*, 2012. Effects of melatonin on testis histology, oxidative stress and spermatogenesis after experimental testis ischemia-reperfusion in rats. *Eur Rev Med Pharmacol Sci* 16, 582-588.
- Kulbacka, J., Saczko, J., Chwilkowska, A., 2009. [Oxidative stress in cells damage processes]. *Pol Merkur Lekarski* 27, 44-47.
- Lanza, C., Raimondo, S., Vergani, L., Catena, N., Senes, F., Tos, P., *et al.*, 2012. Expression of antioxidant molecules after peripheral nerve injury and regeneration. *J Neurosci Res* 90, 842-848.
- Liu, B., Yang, T., Luo, Y., Zeng, L., Shi, L., Wei, C., *et al.*, 2018. Oat β -glucan inhibits adipogenesis and hepatic steatosis in high fat diet-induced hyperlipidemic mice via AMPK signaling. *J Functional Foods* 41, 72-82.
- Ma, J., Yu, H., Liu, J., Chen, Y., Wang, Q., Xiang, L., 2016. Curcumin promotes nerve regeneration and functional recovery after sciatic nerve crush injury in diabetic rats. *Neurosci Lett* 610, 139-143.
- Mecocci, P., Boccardi, V., Cecchetti, R., Bastiani, P., Scamosci, M., Ruggiero, C., *et al.*, 2018. A Long Journey into Aging, Brain Aging, and Alzheimer's Disease Following the Oxidative Stress Tracks. *J Alzheimers Dis* 62, 1319-1335.
- Meydani, M., 2009. Potential health benefits of avenanthramides of oats. *Nutr Rev* 67, 731-735.
- Mir, S.M., Sahu, B.D., Koneru, M., Kuncha, M., Jerald, M.K., Ravuri, H.G., *et al.*, 2018. Supplementation of oat (*Avena sativa* L.) extract abates alcohol-induced acute liver injury in a mouse model. *Nutr Res* 54, 80-92.
- Mizuno, A., 2005. Clinical evaluation of A-Derma Exomega Cream for atopic dry skin. *Skin Res* 4, 581-587.
- Mocchetti, T., Wullschleger, C., Schmidt, A., Aydogan, C., Kreuter, M., 2006. Bioactivity-based development of a wild green oat (*Avena sativa* L.) extract in support of mental health disorders. *Zeitschrift Phytoter* 27, P24.
- O'Moore, K.M., Vanlandschoot, C.M., Dickman, J.R., Figi, A.R., Rothert, A.M., Ji, L.L., 2005. Effect Of Avenanthramide On Rat Skeletal Muscle Injury Induced By Lengthening Contraction: 2435 1: 45 PM-2: 00 PM. *Med Sci Sports Exer* 37, S466.
- Sandhu, K.S., Godara, P., Kaur, M., Punia, S., 2017. Effect of toasting on physical, functional and antioxidant properties of flour from oat (*Avena sativa* L.) cultivars. *J Saudi Soci Agric Sci* 16, 197-203.
- Senger, J.L.B., Verge, V.M.K., Macandili, H.S.J., Olson, J.L., Chan, K.M., Webber, C.A., 2018. Electrical stimulation as a conditioning strategy for promoting and accelerating peripheral nerve regeneration. *Exp Neurol* 302, 75-84.
- Sriraksa, N., Kongsui, R., Thongrong, S., Duangjai, A., Hawiset, T., 2019. Effect of *Azadirachta indica* flower extract on functional recovery of sciatic nerve crush injury in rat models of DM. *Exp Ther Med* 17, 541-550.
- Tuglu, D., Yuvanc, E., Yilmaz, E., Gencay, I.Y., Atasoy, P., Kisa, U., *et al.*, 2015. The antioxidant effect of dexmedetomidine on testicular ischemia-reperfusion injury. *Acta Cir Bras* 30, 414-421.
- Veerasubramanian, P.K., Thangavel, P., Kannan, R., Chakraborty, S., Ramachandran, B., Suguna, L., *et al.*, 2018. An investigation of konjac glucomannan-keratin hydrogel scaffold loaded with *Avena sativa* extracts for diabetic wound healing. *Colloids Surf B Biointerfaces* 165, 92-102.
- Yulug, E., Turedi, S., Alver, A., Turedi, S., Kahraman, C., 2013. Effects of resveratrol on methotrexate-induced testicular damage in rats. *Sci World J* 2013, 489659.
- Zhao, L., Cui, S., 2016. Curcumin improves sciatic nerve regeneration by up-regulating S100 expression in mice. *Biomed Res* 27, 322-327.
- Zimmermann, M., 1983. Ethical guidelines for investigations of experimental pain in conscious animals. *Pain* 16, 109-110.