

The first report of equine atrial fibrillation in Iran

Mokhber-Dezfouli, M.R.^{1*}, Alidadi, N.¹, Darestani-Farahani, M.², Rezakhani, A.³

¹Department of Clinical Sciences, Faculty of Veterinary Medicine, University of Tehran, Tehran-Iran. ²Department of Clinical Sciences, Faculty of Veterinary Medicine, Azad University, Karaj-Iran. ³Department of Clinical Sciences, Faculty of Veterinary Medicine, University of Shiraz, Shiraz- Iran.

Abstract: A Thoroughbred horse with clinical signs of inappetence, loss of body weight, poor performance and scrotal sac infection following castration was examined. Because of irregularity in heart rhythm, ECG was recorded and on the base of normal rhythm criteria, atrial fibrillation was diagnosed. This is believed to be the first reported case of atrial fibrillation in horses in Iran. *J. Vet. Res.* 62,2:53-55,2007.

Key words: ECG, atrial fibrillation, horse, Iran.

Case Report

An eleven year old Thoroughbred horse was referred to Tehran University Veterinary Teaching Hospital with the complaint of inappetence, loss of body condition and poor performance in jumping competition for the last two months before admission. The horse had been castrated four months before presentation, and because of poor post-operative care, the scrotal sac became infected which delayed the healing. The horse's diet consists of barley grain, alfalfa hay and wheat straw.

On clinical examination the animal was found to be depressed, had mild fever, tachycardia, dysrhythmia, respiratory distress associated with mild frothy nasal discharge. Blood samples were taken for CBC and blood chemistry analysis. Because of cardiac dysrhythmia an electrocardiogram (ECG) was recorded using a base apex lead (Figure 1).

Blood tests revealed PCV 43%. WBC 5500/micro liter (neutrophils 63%, lymphocytes 33%, monocytes 3% and eosinophils of 1%). Blood chemistry showed Ca: 9.7mg/dl, P: 3.5 mg/dl and Mg: 3.6 mg/dl.

Because of the fever and the history of scrotal

infection, the animal was given sodium penicillin intravenously every 8 hours for 5 days and again every 12 hours for another 5 days. Fifteen ml of 10% ketofen was given SID for four days. The patient's condition improved. Although dysrhythmia remained unchanged after the treatment of the suspected infection, the heart rate decreased to a normal level. The owner did not agree for further treatment, so the animal was discharged.

ECG Interpretation: The ECG was recorded, using a base apex lead with paper speed of 25mm/sec. and calibration of 1 mV, before (ECG1) and after (ECG2) treatment of scrotal infection. At the first glance it is obvious that the R-R intervals are irregular and there are no P waves, instead there are many small waves (f-waves). The heart rate calculated from the ECG recorded at the time of admission is around 60-70 beat per minute (bpm), which indicates the presence of tachycardia. The heart rate slowed down around 44-50 bpm after treatment which is in the range of normal heart rate for the horse. Because of the irregularity of the R-R interval and the presence of f wave, atrial fibrillation (AF) was diagnosed.

Discussion

Atrial fibrillation is the most common

*Corresponding author's email: mokhberd@chamran.ut.ac.ir, Tel: 021-66438322, Fax: 021-66933222



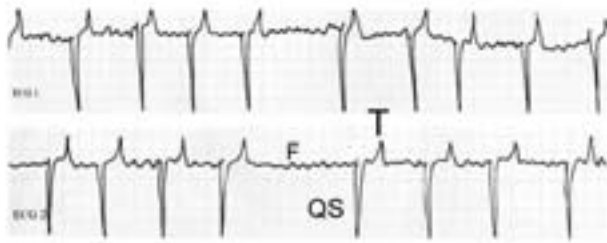


Figure 1. ECG recorded before (ECG1) and after treatment of scrotal infection from a horse on a base apex lead.

dysrhythmia causing poor performance in the horse and it has been reported from many different parts of the world (Patteson, 1996). It is more common in draught horses, but, it has also been reported in racehorses (Amada and Kiryu, 1987; Reef, et al., 1988). It usually occurs in adult horses, however, AF has been observed in normal foals and those with congenital cardiac defects (Machida *et al.*, 1989; Taylor *et al.*, 1991).

AF could be either sustained or paroxysmal (Deem and Fregin, 1982; Rose and Davies 1977). It can convert to sinus rhythm spontaneously without any treatment; however, when it is sustained it should be treated. Several drugs have been used for AF conversion (De Clercq *et al.*, 2006; Van Loon *et al.*, 2004) with various degree of success. Guanidine sulfate been the drug of choice for a long time (Muir *et al.*, 1990) although some of the new drugs have been tried with success. Recently researchers in Canada have used transvenous electrical cardioversion for treatment of AF in horses (McGurrin *et al.*, 2005). The owner of this horse declined treatment with quinidine sulfate, and so we were unable to attempt conversion of the dysrhythmia.

Although AF in the majority of horses, unlike dogs, produces no clinical signs of heart failure, it has an effect on the athletic performance of the affected horses (Patteson, 1996). This is due to the fact that with AF at high heart rates the contribution of atria to ventricular filling is nil due to the chaotic atrial

contraction, and hence cardiac output decreases accordingly.

Various factors have been incriminated in the production and maintenance of AF in large animals, such as, high vagal tone, atrial dilatation due to mitral and tricuspid insufficiency, gastrointestinal disorders, atrial myocardial lesions, electrolytes and acid base imbalances, infection, a macerated fetus and premature atrial contractions (Pringle *et al.*, 1990; Rezakhani *et al.*, 1996; Wijnberg *et al.*, 1998).

The horse presented here had no history of poor performance before scrotal infection following castration. In this case local infection probably produced septicemia which consequently affecting the heart and induced an inhomogenous refractory period and atrial fibrillation. Although infection was controlled by antibiotic and non-steroidal anti-inflammatory drugs the AF persisted. The animal was subsequently retired from jumping due to poor performance.

This is the first documented case of AF in the horse in Iran although studies on cardiac rhythm of horses have been reported before (Rezakhani and Beedgoli, 2001; Rezakhani *et al.*, 2006). Why AF is very rare among horses in Iran is not known. At first we thought the native breeds of horse are smaller size than Western breeds of horse, however, AF has not been observed in horses with much bigger sizes which have been imported into Iran from other countries. It can be postulated that the horses in Iran have not been used in their full capacity so there is less stress on their cardiovascular system, which may play a role in the development of AF.

Acknowledgments

The authors would like to thank Professor Christopher M. Brown from Ontario Veterinary School for correcting the manuscript.

References

1. Amada, A., Kiryu, K. (1987) Atrial fibrillation in the racehorse. *Heart vessels Suppl.* 2: 2-6.
2. De Clercq, D., Van Loon, G., Baert K., Tavernier, R., Groubels, S. (2006) Intravenous amiodarone treatment in horses with chronic atrial fibrillation.



- Vet. J. (In press) (The paper was obtained on line. doi: 10-1016/j.tvjl.2005.04. 001).
3. Deem, D. A., Fregin G. F.(1982) Atrial fibrillation in horses: a review of 106 clinical cases, with consideration of prevalence, clinical signs, and prognosis. *J. Am. Vet. Med. Assoc.* 180: 261-265.
 4. Machida, N., Yasud, J., Too, K.(1989) Three cases of paroxysmal atrial fibrillation in the Thoroughbred newborn foal. *Eq. Vet. J.* 21: 66-68.
 5. Mcgurrrin, M. K., Physick-Sheard, P. W., Kenney, D. G., Kerr, C.(2005) Transvenous electrical cardioversion of equine atrial fibrillation: technical considerations. *J. Vet. Intern. Med.* 19: 695-702.
 6. Patteson, M. W.(1996) *Equine Cardiology*, Balckwell Science Ltd., Oxford, pp. 187-197.
 7. Pringle, J., Gomp, R., Magnus, R.(1990) ECG of the month. Atrial fibrillation in a cow with meningitis. *J. Am. Vet. Med. Assoc.* 196: 56-57.
 8. Reef, V. B., Levitan, C.W., Spencer, P. A.(1988) Factors affecting prognosis and conversion in equine atrial fibrillation. *J. Vet. Intern. Med.* 2: 1-6.
 9. Rezakhani, A., Oloumi, M. M., Ahmadi, A.(1996) Atrial fibrillation in a cow with fetal maceration. *Can. Vet. J.* 37: 625-626.
 10. Rezakhani, A., Beedgoli, A. R.(2001) The prevalence of cardiac arrhythmias in horses in Tehran area. *J. Fac. Vet. Med. Univ. Tehran.* 56: 48-50.
 11. Rezakhani, A., Mokhber-Dezfouli, M. R., Goodarzi, M., Ansari Lari, M.(2006) Study on the frequency of cardiac dysrhythmias in apparently healthy horses of riding schools. *J. Fac. Vet. Med. Univ. Tehran.* 62.
 12. Rose, R. J., Davies, P. E. (1977) Paroxysmal atrial fibrillation in a race horse. *Aust. Vet. J.* 53: 545-549.
 13. Taylor, F. G., Wotton, P. R., Hillyer, M. H., Barr, F. J., Lucke, V. M.(1991) Atrial septal defect and atrial fibrillation in a foal. *Vet. Rec.* 128: 80-81.
 14. Van Loon, G., Blissitt, K. J., Young, L. E.(2004) Use of intravenous flecainide in horse with nutrally occurring atrial fibrillation. *Eq. Vet. J.* 36: 609-614.
 15. Wijnberg, I. D., Van Der Kolk, J. H., Van Gardenen, E., Binkhorst, G. J.(1998) Atrial fibrillation associated with central nervous symptoms and colic in a horse: a case of equine myopathy. *Vet. Q.* 20: 73-76.

