

## The immunohistochemistry study of lesions due to avian infectious bronchitis (Serotype 4/91) on different tissues in specific pathogen free chicks

Mahdavi, S.<sup>1</sup>, Tavasoly, A.<sup>2\*</sup>, Pourbakhsh, A.<sup>1</sup>, Momayes, R.<sup>1</sup>, Shamseddini, M.<sup>3</sup>

<sup>1</sup>Razi Vaccine and Serum Research Institute, Tehran-Iran.

<sup>2</sup>Faculty of Veterinary medicine, University of Tehran, Tehran -Iran.

<sup>3</sup>Razi Institute, Kerman branch, Kerman-Iran.

(Received 22 October 2005 , Accepted 17 March 2006)

**Abstract:** Thirty specific pathogen free (SPF) 20-day-old chicks were inoculated by the intra-tracheal (n=15) or oral (n=15) routes with serotype 793/B of IBV, isolated of Iran. Two groups of 15 SPF chicks which as controls received PBS, either by the intra-tracheal or oral route. All the chicks were observed and examined daily for clinical signs. Each day for 5 days three chicks from each infected and control group were post-mortemed and examined pathological changes in the trachea, lungs, kidneys and intestines. Sections of these tissues were prepared, stained and examined microscopically for histopathological and immunohistochemical changes. Grossly, a small amount of clear mucus and slight congestion were found only in the lumen of the trachea and the lungs of the group chicks which were infected with IBV. The kidneys were pale and slightly enlarge. Immunohistochemical examination revealed similar changes in the kidneys of both groups of chicks infected by the intra-tracheal and oral routes. Viral antigens were detected in the infected cells. The viral antigens were apparent prior to the development of lesions and were detected in the cytoplasm of epithelial cells by 3 days post infection with IBV. The results of this study clearly indicate that IBV (serotype 793/B), isolated in Iran by Momayes *et al.* (2001), is capable of causing lesions in different tissues most severely in the kidneys of experimentally infected chicks. On the other hand, the serotype has a greater affinity and positive tropism for the kidney than to other tissues.

**Key words:** infectious bronchitis, serotype 793/B, immunohistochemistry, avian diseases.

### Introduction

Infectious bronchitis, a viral disease of great economic importance to the poultry industry, affects the respiratory, urinary and reproductive systems of chickens (14). While IB is considered primarily a disease of respiratory system, different IBV strains may show variable tissue tropisms (8,12,16). Chong and Apostolov (1982) demonstrated with using immunofluorescence, that viral antigen was mainly distributed in many organs and virus replication was also confirmed ultrastructurally by Condron and

Marshall (1986) (1,4,5). On the other hand, using streptavidin-biotin immunohistochemical technique and monoclonal antibody to an IBV nucleoprotein, IBV antigen was demonstrated in epithelial cells (Owen *et al.*, 1991; Janse *et al.*, 1994) (10).

The present study describes a sequential immunohistochemical investigation of antigen in the trachea, lung, intestine and kidneys of IBV infected chicks. The aim was to elucidate the localization of viral antigen and its relation to lesions, as well as to determine the main target cells and preferential sites of viral replication and tissue tropism of the serotype.

\*Corresponding author's email: atavasoli@ut.ac.ir, Tel: 021- 61117060, Fax: 021-66933222



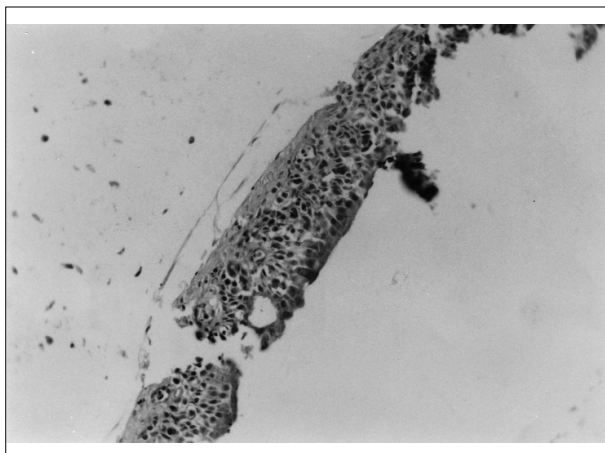


Figure 1: Trachea from IBV-inoculated chick at 5 days pi showing deciliated and degenerated of IBV-antigen-positive cells. Viral antigens were stained yellow-brown spots ( $\times 400$ ).

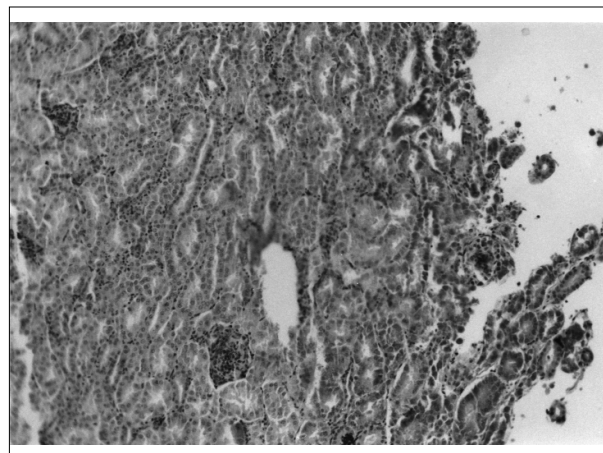


Figure 2: Kidney of chick 5 days after inoculation showing IBV antigen in the cytoplasm of the epithelial cells (yellow-brown spots) in the ducto-tubular tissue ( $\times 250$ ).

## Materials and Methods

**Virus:** Serotype 793/B (4/91) IBV was isolated from broiler commercial poultry flocks of 2-18 weeks of age, which were suspected to IBV infection (Momayes *et al.*, 2001). The virus was inoculated (0.1ml) into the allantoic cavity of 10 day-old chicken embryonated SPF eggs. Inoculated eggs were checked twice a day. The allantoic fluid was collected from eggs between 4-5 days post-inoculation (pi). However, 1:4 dilution in 0.01 M PBS (pH=7.4) was used as inoculum at a titre of 105 EID<sub>50</sub> /0.1ml for infected groups.

**Experimental Design:** Sixty 20 day-old SPF chicks were divided into 4 groups. The infected groups (A=15, B=15) were inoculated intra-tracheally (A) and intra-orally (B) with virus (0.3ml), while the control groups (C=15, D=15) were inoculated with 0.3ml of 0.01M PBS (intra-tracheal and orally). The infected and control chicks were housed separately and received food and water ad libitum.

In four groups (infected and control groups), clinical signs were recorded daily for 5 days post-inoculation and three chicks of each were killed at 1, 2, 3, 4 and 5 days p. i.

**Immunohistochemistry:** At first, the tissues samples sectioned in 3-5 $\mu$ m thickness, and then the slides rinsed in xylol and dilutions of alcohol. The slides rinsed in dionized water and placed in Tris-Hcl solution (0.1mol/l, pH=7.2-7.4) twice for 5 min (13).

Sections were first treated with a specific monoclonal antibody (1:600) to Matrix (M) and a specific monoclonal antibody (1:600) to Spike (S) antigens of IBV (30 min incubation in room temperature). After washing in Tris-solution (twice), they were treated with peroxidase-labeled Horse Reddish (45min) and washed again in Tris-solution (twice). Sections were then treated with 0.02% diaminobenzidine (DAB)-Hcl in buffered solution at room temperature for 4min, and after washing in Tris-solution (twice), counter-stained with Mayer's Hematoxylin. In this method, viral antigens in the cytoplasm of infected cells were stained as yellow-brown spots.

## Results

**Clinical Signs:** Some chicks of the infected groups showed tracheal rales, coughing and gasping at 3 days p. i. The signs were less severe by 8 days p. i. Decreased food consumption, ruffled feathers and whitish-green watery diarrhea were noted from 3 to 8 days p. i. Three chicks of infected groups died at 1 to 5 days p. i. The appetite returned to normal at 2 weeks p. i. and almost all signs disappeared after 2 weeks p. i. There were neither clinical signs nor deaths in the control groups.

**Gross Findings:** In the infected groups, slight hyperemia was at 3 days p. i. and in the tracheal mucosa with a small amount of catarrhal exudate. The kidneys were pale and swollen that specially found in



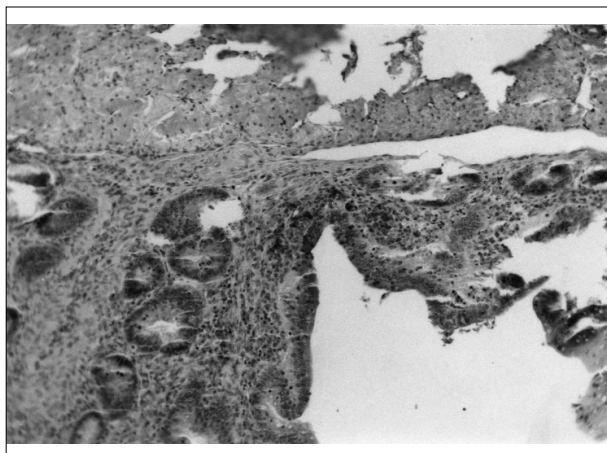


Figure 3: Intestine from IBV inoculated chick at 5 days pi having a severely degenerated IBV antigen-positive tubules ( $\times 250$ ,  $\times 400$ ).

intra-orally inoculation from 5 to 10 days p. i. No gross lesions were seen in other organs; also no comparable gross lesions were seen in control groups.

**Immunohistochemistry of the Trachea:** The distribution of viral antigen in tissues is shown in

Table1. Immunohistochemistry of two infected groups

	Group inoculated									
	Intra-tracheally					intra-orally				
Tissue lesion	1a	2	3	4	5	1	2	3	4	5
Trachea	-	<sup>b</sup>	<sup>++c</sup>	+	+	-	+	+	++	+
Kidney	-	-	++	++	+++	-	-	++	++	+++
Intestine	-	-	+	++	+	-	-	++	++	+
Lung	-	+	+	++	+	-	-	+	++	+

a = Days post-inoculation

b = Mean severity index from three chicks: -, no change; +, mild; ++, moderate; +++, severe.

c = Mean no. of antigen-positive epithelial cells per 5 microscopic fields tissue lesion ( $\times 400$ ) from three chicks: -, no change; +, 1 to 9; ++, 10 to 20; +++, over 20

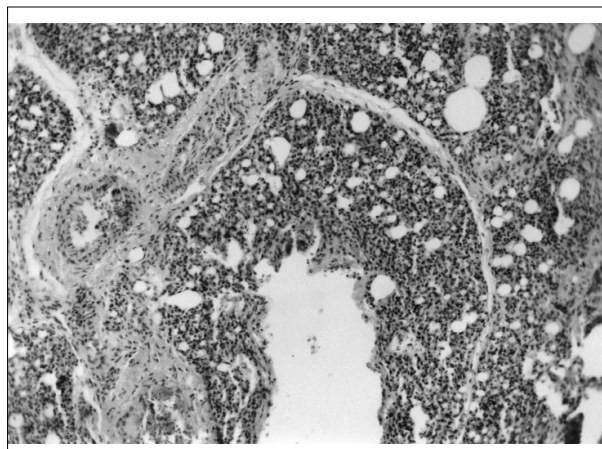


Figure 4: Lung of chick 5 days after inoculation showing IBV antigen in the cytoplasm of the epithelial cells (yellow-brown spots) ( $\times 400$ ).

Figure 1. Viral antigen was detected in the tracheal epithelium cells from 2 to 5 days p. i (Table 1). This method, demonstrated that viral antigen was primarily distributed in trachea when using intra-tracheally inoculation. At days 2 of p. i. viral antigen was scattered in a few epithelial cells. Antigen-positive cells often sloughed off into the tracheal lumen. Viral antigen was found increasingly in epithelial cells up to 5 days p. i.

**Immunohistochemistry of the kidney:** The distribution of viral antigens in tissues is shown in Figure 2. Viral antigen was detected in the epithelial cells of proximal convoluted tubules (PCT), loop of henle (HL), distal convoluted tubules (DCT) and collecting tubules (CT) and also in few epithelial cells of Bowman's capsule from 3 days p. i (Table1). Positive cells increased in number up to 5 days p. i. in both infected groups. Viral antigen-positive cells were swollen, degenerated and desquamated into lumina. Inflammatory cells infiltrated in the vicinity of the antigen-positive parts that equalized with the medullary region of kidney in other animals.

**Immunohistochemistry of the Intestine:** The distribution of viral antigen in tissues is shown in Figure 3. Viral antigen was detected in the epithelium and in a few epithelial cells of crypts from 3 days p. i. Viral antigen-positive cells were frequently degenerated and desquamated into lumina (Table 1).

**Immunohistochemistry of the Lung:** The distribution of viral antigen is shown in Figure 4. Viral antigen was detected in the epithelium and in a



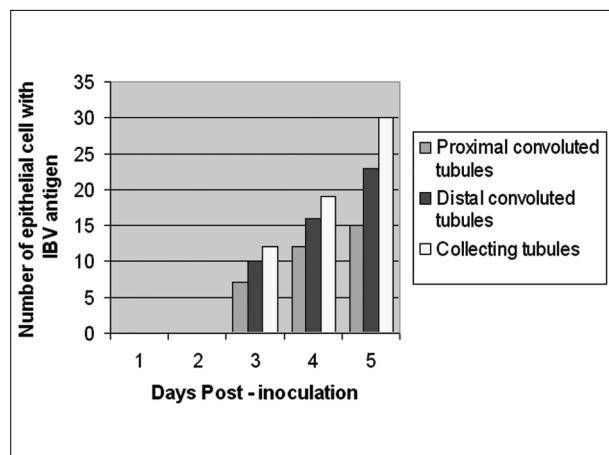


Figure 5. Incidence of viral antigen-positive epithelial cells in different parts of kidney. Each bar represents the mean per 5 microscopic fields of renal tissue from three chicks.

few epithelial cells of the alveolar mucous glands from 2 days p. i (Table1).

## Discussion

This study was conducted to demonstrate the viral antigen, frequency and severity of antigen distribution, tissue tropism with using of immunohistochemistry method for the serotype 793/B (4/91), which recently has been reported in the Iran (Momayes *et al.*, 2001). In the present study, it is interesting to note that the infected chicks showed almost similar patterns of clinical signs, gross findings, and distribution of tissues viral antigens. Of course while the chicks infected by the intra-tracheal route had an earlier (from 2 days p. i.) distribution of antigen. Thus the suggestion by Purcell *et al.*, (1976) that the route of infection with IBV may affect the incidence of disease is not supported (11).

The serotype 793/B (4/91) isolated in Iran (Momayes *et al.*, 2001), has a broad tissue distribution that included respiratory, digestive, and urinary tract tissues. The frequent finding of viral-antigen in the epithelium of kidney in the present study, suggests that the virus has a tropism to epithelium, specially in collecting tubules of kidney.

The immunohistochemical findings in the respiratory, digestive and urinary tracts in this study are similar to those described previously on other strains of IBV (Purcell and McFerran 1972, ChenandItakura 1997, ChenandHosi 1996) (2,4, 6, 7,

10,13,17).

In trachea infected by the serotype 4/91, viral antigen was localized in the epithelial layer that deciliated. Also, distribution of viral antigen in epithelium of crypts is shown in intestine. In lung infected by virus, antigen was detected in epithelial cells of the alveolar mucous glands. In kidney, viral antigen was localized mainly in the epithelial cells. Antigen was prominently distributed in the collecting tubules (CT), distal convoluted tubules (DCT) and proximal convoluted tubules (PCT), which showed marked damage of their epithelial cells at the peak of lesions; of course antigen-positive PCT epithelial cells were few. Thus, IBV 4/91 seemed to attack mainly the ducto-tubular tissues in kidney (Figure 5).

In the present study, IBV antigen appeared in renal epithelial cells prior to the development of renal lesions. The virus induced renal lesions which can be considered to be a ducto-tubular interstitial nephritis.

The sequential observations by immunohistochemistry (from 1st-5th day p. i.) support previous evidence that the virus first infects the tracheal and lung mucosa, then replicates in intestine and specially in renal epithelial cells (ChongandApostolov, 1982; Owen *et al.*, 1991; Janse *et al.*, 1994) (3,4,9,10,15). Presence of the virus antigen seemed to be must correlated with the pathogenesis of histological changes. The findings from this study support the view that IBV 793/B has a greater affinity and pathogenicity for the kidney than to other tissues.

## Acknowledgments

The authors wish to thank the staff of Department of poultry and Department of pathology for providing facilities. We also wish to express our appreciation to Dr. Momayes. We should like to thank Dr. Mehdizadeh for reading the manuscript and for positive contribution.



## References

- Ambali, A. G., Jones, R. E.(1990) Early pathogenesis in chicks of infection with an enterotropic strain of IBV, *Avian Dis.* 34:809-17.
- Ambali, A. G.(1992) Recent studies on the enterotropic strain of avian IBV. *Vet. Res. Comm.* 16: 153-7.
- Binns, M. M.(1986) Comparison of the spike precursor sequences of coronavirus infectious bronchitis virus strain M41 and 6182 with that IBV1 Beaudelhe, J. *Gen. Virology.* 62:2825-31.
- Chen, B. Y., Itakura, C.(1997) Histopathology and immunohistochemistry of renal lesions due to avian infectious bronchitis virus in chicks uninoculated and previously inoculated with highly virulent infectious bursal disease virus, *Avian Pathol.* 26: 607-24.
- DeWit, J. J.(2000) Detection of infectious bronchitis virus, *Avian Pathol.* 29: 71-93.
- DeWit, J., Koch, G., Kant, A., VanRooselaar, D., J.(1995) Detection by immunofluorescent assay of serotype-specific and group-specific antigens of infectious bronchitis virus in tracheas of broilers with respiratory problems. *Avian Pathol.* 24: 465-74.
- Dhinakar raj, G., Jones, R. C.(1996) Immunopathogenesis of infection in SPF chicks and commercial broiler chickens of a variant infectious bronchitis virus of economic importance, 1996, *Avian Pathol.* 25: 481-501.
- Handberg, K.J., Nielsen, O. L., Pedersen, M. W., Jorgensen, P. H.(1999) Detection and strain differentiation of infectious bronchitis virus in tracheal tissues from experimentally infected chickens by reverse transcription-PCR.comparison with an immunohistochemical technique, *Avian Pathol.* 28: 327-35.
- Lucio, B., Fabricant, J.(1990) Tissue tropism of three cloacal isolates and Mass. Strain of IBV. *Avian Dis.* 34: 865-70.
- Nakamura, K., Cook, J. K. A., Otsuki, K., Huggins, M. B., Frazier, J. A.(1991) Comparative study of respiratory lesions in two chicken lines of different susceptibility infected with IBV: histology, ultrastructure and immunohistochemistry. *Avian Pathol.* 20: 241-57.
- Purcell, D. A., Tham, V. L., Surman, P. G.(1976) The histopathology of infectious bronchitis in fowls infected with a nephrotropic "T" strain of virus. *Aus. Vet. J.* 52: 85-91.
- Pohl, R.(1974) Histopathogenesis of the nephrosis-nephritis syndrome, *Avian Pathol.* 3:1-13.
- Polak, J., VanNoorden,M.(1997) Introduction to Immunocytochemistry, second edition, Bios scientific publishers.
- Siller, W. G.(1981) Renal pathology of the fowl. A review. *Avian Pathol.* 10: 187-262.
- Van den Bosch, G., 4/91 A new emerging IB variant.
- Winterfield, R. W., Hitchner, S. B.(1962) Etiology of an infectious nephritis-nephrosis syndrome of chickens. *Am.J. Vet. Res.* 23:1273-9.
- Yagyu, K., Ohta, S.(1990) Detection of infectious bronchitis virus antigen from experimentally infected chickens by indirect immunofluorescent assay with monoclonal antibody. *Avian Dis.* 34: 246-52.



## مطالعه ایمنو هیستوشیمیایی ضایعات بیماری برونشیت عفونی طیور سویه بر روی بافت‌های مختلف جوجه‌های سالم

سعید مهدوی<sup>۱</sup> عباس توسلی<sup>۲\*</sup> سید علی پوربخش<sup>۱</sup> رضا ممیز<sup>۱</sup> مهرداد شمس‌الدینی<sup>۳</sup>

<sup>۱</sup> موسسه تحقیقاتی سرم و واکسن رازی، تهران-ایران.

<sup>۲</sup> دانشکده دامپزشکی دانشگاه تهران، تهران-ایران.

<sup>۳</sup> موسسه رازی کرمان، کرمان-ایران.

(دریافت مقاله: ۲۲ مهر ماه ۱۳۸۳، پذیرش نهایی: ۳۰ مهر ماه ۱۳۸۴)

تعداد ۳۰ قطعه جوجه‌ای که فاقد هر گونه آلودگی با آگانیسم‌های اختصاصی (SPF) بوده و دارای سن ۲۰ روز بوده‌اند، را از طریق داخل نائی (۱۵ قطعه) و از راه دهانی (۱۵ قطعه) توسط ویروس عامل بیماری برونشیت عفونی طیور با سویه 793/B که از ایران جدا شده است، آلوده گردیدند. دو گروه جوجه SPF هر گروه شامل ۱۵ قطعه جوجه بعنوان گروه‌های کنترل به روش داخل نائی و دهانی PBC دریافت نمودند. تمام جوجه‌ها هر روز مشاهده و مورد آزمون بالینی قرار می‌گرفتند. تعداد سه قطعه جوجه از هر گروه شامل گروه‌های کنترل و مورد آزمایش به مدت ۵ روز متوالی پس از تلقیح انتخاب نموده، سپس جوجه کشته شده و مورد کالبد گشایی قرار گرفتند. جهت مشخص شدن تغییرات پاتولوژیک بیماری بافت‌های نای، ریه، کلیه و روده‌ها مورد آزمایش قرار گرفتند. مقاطع بافتی از نمونه‌های فوق تهیه و پس از رنگ آمیزی جهت مشخص شدن تغییرات بافتی مورد آزمون ریزینی شامل هیستوپاتولوژی و مطالعه ایمنونوهیستوشیمیایی قرار گرفتند. از نظر ماکروسکوپی، میزان کمی موکوس شفاف همراه با پر خونی ملایم در قسمت داخلی نای و ریه جوجه‌های که توسط ویروس IBV آلوده شده بودند مشاهده گردید. کلیه‌ها، رنگ پریده و کمی متورم بودند. آزمون هیستوشیمیایی از کلیه‌ها تغییرات مشابهی را در هر گروه آزمایش که به روش داخل نای و دهانی بوسیله ویروس آلوده شده بودند را نشان داد. به همین روش آنتی ژن‌های ویروسی در داخل سلول‌های آلوده مشخص گردیدند. آنتی ژن‌های ویروسی بر اساس مرحله پیشرفت ضایعات بیماری ظاهر گردیده و در داخل سیتوپلاسم سلول‌های ای تلیال سه روز پس از ایجاد عفونت توسط ویروس IBV، مشخص گردیدند. این مطالعه بوضوح نشان داد که ویروس IBV سویه 793/B جدا شده از ایران (که توسط ممیز و همکاران معرفی شد ۲۰۰۱) قادر است ضایعات بیماری را در بافتهای مختلف بدن جوجه‌های که به روش تجربی آلوده شده‌اند بویژه با شدت بیشتر در کلیه‌ها ایجاد نماید. بعلاوه این مطالعه تأیید نمود که این ویروس دارای وابستگی زیاد و علاقه مثبتی به بافت کلیه نسبت به سایر بافت‌ها دارد.

واژه‌های کلیدی: برونشیت عفونی، سویه 793/B، ایمنونو شیمیایی، بیماری طیور.

